





## ORIGINAL ARTICLE

# Clinical heterogeneity and intrafamilial variability of Joubert syndrome in two siblings with *CPLANE1* variants

Xiujuan Zhang<sup>1,2</sup> | Yue Shen<sup>3</sup>  | Ping Li<sup>4</sup> | Ruikun Cai<sup>3</sup> | Chao Lu<sup>3</sup> | Qian Li<sup>3</sup> |  
Cuixia Chen<sup>3</sup> | Yufei Yu<sup>3</sup> | Tingting Cheng<sup>3,5</sup> | Xian Wang<sup>1</sup> | Minna Luo<sup>3</sup>  |  
Muqing Cao<sup>2</sup>  | Zongfu Cao<sup>3</sup> | Xu Ma<sup>3</sup> 

<sup>1</sup>Department of Physiology and Pathophysiology, School of Basic Medicine Sciences, Key Laboratory of Molecular Cardiovascular Science, Ministry of Education, Peking University, Beijing, China

<sup>2</sup>Key Laboratory of Cell Differentiation and Apoptosis of Chinese Ministry of Education, Department of Pathophysiology, Shanghai Jiao Tong University School of Medicine, Shanghai, China

<sup>3</sup>National Human Genetic Resources Center, National Research Institute for Family Planning, Beijing, China

<sup>4</sup>Department of Developmental Pediatrics, The Second Hospital of Jilin University, Changchun, Jilin, China

<sup>5</sup>Graduate School of Peking Union Medical College, Beijing, China

## Correspondence

Muqing Cao, Zongfu Cao, and Xu Ma, National Human Genetic Resources Center, National Research Institute for Family Planning, Beijing, China.  
Email: muqingcao@sjtu.edu.cn (M. C.), zongfu\_cao@163.com (Z. C.) and maxu\_nhgrc@163.com (X. M.)

## Funding information

National Key Research and Development Program, Grant/Award Number: 2016YFC1000307; Ministry of Science and Technology of the People's Republic of China, Grant/Award Number: 2016YFC1000307; National Research Institute for Family Planning, Grant/Award Number: 2020GJZ05; National Natural Science Foundation of China, Grant/Award Number: 91954123 and 3197288; Clinical Research Projects of Shanghai Municipal Health Commission, Grant/Award Number: 20194Y0133

## Abstract

**Background:** Joubert syndrome (JBTS) is a rare genetic disorder that is characterized by midbrain-hindbrain malformations. Multiple variants in genes that affect ciliary function contribute to the genetic and clinical heterogeneity of JBTS and its subtypes. However, the correlation between genotype and phenotype has not been elucidated due to the limited number of patients available.

**Methods:** In this study, we observed different clinical features in two siblings from the same family. The older sibling was classified as a pure JBTS patient, whereas her younger sibling displayed oral-facial-digital defects and was therefore classified as an oral-facial-digital syndrome type VI (OFD VI) patient. Next, we performed human genetic tests to identify the potential pathogenic variants in the two siblings.

**Results:** Genetic sequencing indicated that both siblings harbored compound heterozygous variants of a missense variant (c.1067C>T, p.S356F) and a frameshift variant (c.8377\_8378del, p.E2793Lfs\*24) in *CPLANE1* (NM\_023073.3).

**Conclusion:** This study reports that two novel *CPLANE1* variants are associated with the occurrence of JBTS and OFD VI. These results help elucidate the intrafamilial phenotypic variability associated with *CPLANE1* variants.

## KEYWORDS

*CPLANE1*, intrafamilial heterogeneity, Joubert syndrome, OFD VI

Xiujuan Zhang and Yue Shen contributed equally.

This is an open access article under the terms of the Creative Commons Attribution-NonCommercial-NoDerivs License, which permits use and distribution in any medium, provided the original work is properly cited, the use is non-commercial and no modifications or adaptations are made.

© 2021 The Authors. *Molecular Genetics & Genomic Medicine* published by Wiley Periodicals LLC.

## 1 | INTRODUCTION

Joubert syndrome (JBTS, OMIM# 213300) is a classic ciliopathy that was first identified by Dr. Joubert et al., (1969). JBTS is a rare recessive genetic disorder with an estimated prevalence of 1/80000-1/100000 (Valente et al., 2013). The clinical diagnosis of JBTS by magnetic resonance imaging (MRI) is characterized by distinct cerebellar vermis and brainstem malformation, known as the "molar tooth signs (MTS)" (Romani et al., 2013). Most patients with JBTS exhibit developmental delay, hypotonia, ataxia, abnormal breathing patterns, and/or abnormal eye movements, as well as other variable features, including retinal dystrophy, polydactyly, coloboma, and cystic disease. Variations in more than 35 genes, most of which encode ciliary proteins, have been demonstrated to be associated with the development of JBTS (Wheway et al., 2015). More variations associated with JBTS need to be elucidated.

*CPLANE1* (previously known as *C5orf42*, NM\_023073.3) is one of the causative genes for JBTS and oral-facial-digital syndrome VI (OFD VI, OMIM# 277170). OFD VI represents a rare phenotypic subtype of Joubert syndrome and related disorders (Poretti et al., 2012; Romani et al., 2015). The *CPLANE1* protein has a putative coiled-coil region and exhibits features of a transmembrane protein. This protein is located at the ciliary transition zone and is involved in the recruitment of peripheral IFT-A proteins to the basal body for cilium assembly (Toriyama et al., 2016). Patients with *CPLANE1* variants have been observed to have multiple birth defects typical of ciliopathies (Bonnard et al., 2018). To date, more than 130 different *CPLANE1* variants have been identified, and individuals carrying *CPLANE1* variants exhibit various phenotypes (Ben-Salem et al., 2014). In this study, we identified a missense variant (c.1067C>T, p.S356F) and a frameshift variant (c.8377\_8378del, p.E2793Lfs\*24) of *CPLANE1* in two siblings. Although the siblings carried the same *CPLANE1* variants, the clinical features showed a high degree of intrafamilial variability.

## 2 | MATERIALS AND METHODS

### 2.1 | Genomic DNA samples and ethical compliance

The blood samples used for genomic DNA extraction were collected from two patients and their parents after a written informed consent form was completed. This project was approved by the Ethics Committee of the National Research Institute for Family Planning.

### 2.2 | Whole exome sequencing (WES) and variants analysis

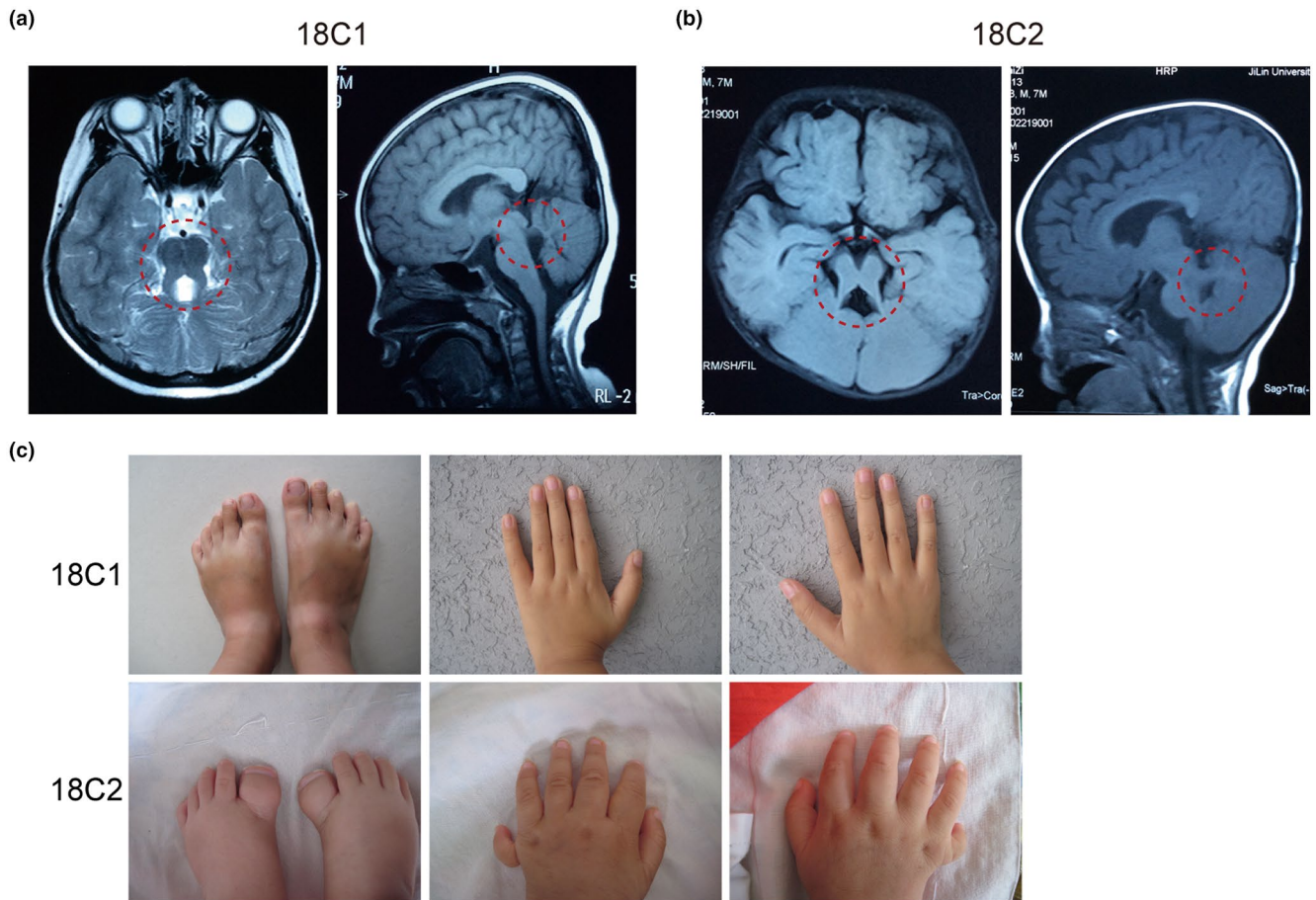
Genomic DNA was isolated by using the QIAamp DNA Blood Mini Kit (Qiagen). Whole-exome libraries were prepared using the Agilent SureSelect Human All Exon V6 kit (Agilent Technologies Inc.), and sequenced on the Illumina NovaSeq 6000 platform. The variants were called and annotated as previously described (Luo et al., 2019). Sanger sequencing was used to further validate the identified variants of *CPLANE1* (NM\_023073.3). The PCR primers used were as follows: *CPLANE1*-Exon 9 Forward (5'-CTGCTTGGTACAGCCCATTT-3') and Reverse (5'-AT TGAGATGACAGACTCAAAGAAA-3'); *CPLANE1*-Exon 43 Forward (5'-GGGTTGCCAGTTGGAAATAG-3') and Reverse (5'-TTCCCAGTAAATCATGTTTCAGTAA-3').

## 3 | RESULTS

### 3.1 | Intrafamilial heterogeneity in the clinical features of the two siblings was observed

The proband was a 14-year-old female (18C1). She was born full-term by cesarean section to a healthy couple. She was unable to sit until 1 year of age and could not walk independently until 5 years of age. At the age of 7 years, she underwent a brain MRI, which showed typical MTS with thickening and elongation of the superior cerebellar peduncles (SCP), deepening of the interpeduncular fossa (IF), hypoplasia of the cerebellar vermis, and enlargement of the fourth ventricle (Figure 1a). No other facial deformities or skeletal defects were observed on physical examination, except for oculomotor anomalies. Nor renal/hepatic involvement or retinal degeneration was observed. The Marshalla oral sensorimotor test (MOST) (Marshalla, 2007) indicated reduced strength and poor coordination of her lips, tongue, and jaw, suggesting that she experienced delayed language development, reduced intelligibility of speech, and apraxia of speech (Figure 1c and Table 1). Based on these findings, 18C1 was diagnosed as a pure JBTS patient.

Her brother (18C2) was a 6-year-old boy who exhibited similar neurological symptoms, but his clinical features differed from 18C1. Prenatal ultrasonography at 32 weeks gestation demonstrated ventriculomegaly, and prenatal MRI at 35 weeks gestation showed typical MTS features of cerebellar hypoplasia. The patient was born full-term by cesarean section with a birth weight of 3.8 kg. After birth, polydactyly on both hands and bilateral great toes were observed (Figure 1c). 18C2 exhibited abnormal breathing patterns and



**FIGURE 1** Brain MRI and photographs of the patients' feet and hands. (a and b) Axial (left) and sagittal (right) views of brain MRI in 18C1 and 18C2 show characteristic molar tooth signs (red circles). (c) Photographs of the patients' feet and hands show normal morphologies in 18C1 and limb abnormalities in 18C2

hypotonia. Physical examination demonstrated the patient's facial deformities, including a prominent forehead, low-set ears, wide nasal bridge, and hypertelorism. Tongue hamartomas was also noticed on examination. In addition, the patient exhibited skeletal abnormalities, such as scoliosis. The patient also had severe deficits in both gross motor skills and language skills. All the clinical features together with the MTS on brain MRI (Figure 1b) confirmed the diagnosis of OFD VI.

### 3.2 | Genetic studies revealed novel heterozygous *CPLANE1* variants in two affected individuals

To determine the genetic basis of JBTS and OFD VI in this family, we performed WES on both siblings and validated the variants in all family members by using Sanger sequencing. We observed that both the proband (18C1) and her brother (18C2) carried novel heterozygous variants of *CPLANE1*, a paternally inherited frameshift variant c.8377\_8378del

(p. E2793Lfs\*24) and a maternally inherited missense variant c.1067C>T (p.S356F), respectively (Figure 2a,b). These two variants have not been reported in public databases, such as gnomAD, ExAC, or 1000 Genomes. Both variants are located outside of the predicted transmembrane and coiled-coil domains. The c.8377\_8378del variant causes the loss of the C-terminal domain (pfam15392) of *CPLANE1* (Figure 2c) and is classified as a "pathogenic variant" according to the American College of Medical Genetics and Genomics (ACMG) guidelines (Richards et al., 2015). The missense variant c.1067C>T results in the substitution of the highly conserved serine into phenylalanine at residue 356 (Figure 2d), which is predicted to be deleterious by several tools (SIFT = 0.002; PolyPhen = 0.997; CADD PHRED = 23.9; ClinPred = 0.985). Thus, the c.1067C>T variation is annotated to be "likely pathogenic" according to the ACMG guidelines. Further, additional pathogenic variants in other ciliopathy-related genes were not identified. Taken together, the results of this study suggest that these two novel heterozygous variants may be causative for the clinical features of JBTS and OFD VI in these two siblings.

Patient ID	18C1	Frequency in JBTS Patients	18C2	Frequency in OFD VI Patients
c.1067C>T (p.Ser356Phe)	+		+	
c.8377_8381delGAAA (p.Glu2793IlefsTer31)	+		+	
Age	14 years		6 years	
Sex	Female		Male	
Brain MRI	MTS	93.1%	MTS	100%
Developmental delay	+	100%	+	100%
Intellectual disability	+	100%	+	46.7%
Oculomotor apraxia	+	89.7%	+	11.1%
Breathing abnormality	-	61.9%	+	14.3%
Limb abnormality <sup>a</sup>	-	18.5%	+	100%
Scoliosis	-	0	+	57%
Tongue hamartomas	-	0	+	50%
Retinal involvement	-	0	-	0
Renal involvement	-	0	-	4.3%
Hepatic involvement	-	0	-	0

TABLE 1 Clinical features of the patients with *CPLANE1* variants

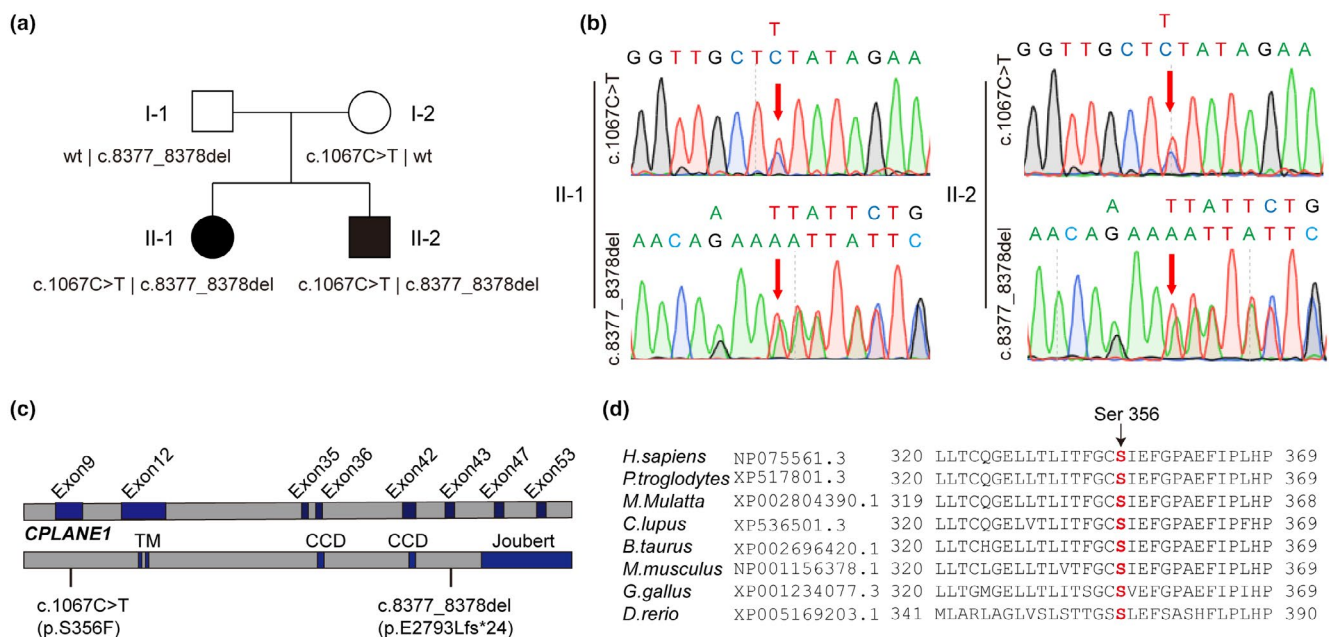


FIGURE 2 Genetic findings and functional analysis of the variants. (a) The pedigree of the family shows two novel variants. (b) Sequence chromatograms show heterozygous variations in *CPLANE1* in the two siblings. (c) The locations of variants in *CPLANE1* and the predicted transmembrane domain (TM), coiled-coil domain (CCD), and Joubert syndrome-associated domain. (d) The amino acid alignments generated by homologue (NCBI) show that the residue affected by the c.1067C>T variant is highly conserved

## 4 | DISCUSSION

Since 2012, multiple variants of *CPLANE1* have been identified in JBTS families by using WES (Alazami et al., 2012; Asadollahi et al., 2018; Kroes et al., 2016; Liu et al., 2020; Ohba et al., 2013; Srour et al., 2012). Meanwhile, several novel variants of *CPLANE1* have been reported to be responsible for the OFD VI and milder type of JBTS phenotypes

(Bayram et al., 2015; Bonnard et al., 2018; Lopez et al., 2014; Romani et al., 2015; Wentzensen et al., 2015). According to the Human Gene Mutation Database (HGMD), more than 125 variants in the *CPLANE1* gene have been confirmed to be associated with JBTS traits, including 74 missense variants, 15 splice-change variants, and 36 insertion-deletion variants. In our study, it was found that two patients carrying the same compound heterozygous variants of *CPLANE1*



(c.8377\_8378del and c.1067C>T) exhibited different clinical features, with 18C1 being diagnosed as a JBTS patient and 18C2 being diagnosed as an OFD VI patient. Due to abnormalities in the localization and function of ciliogenesis and planar polarity effector proteins in the *CPLANE1* variants (Toriyama et al., 2016), we surmise that both variants may contribute to the development of JBTS and OFD VI diseases by affecting ciliary function. Considering that rare cases of JBTS or OFD VI have been reported in the Chinese population, these two novel *CPLANE1* variants will provide valuable information for future clinical diagnosis.

JBTS is a heterogeneous disorder, and the clinical features may vary between patients. Surprisingly, a high degree of intrafamilial heterogeneity was observed in this family. Although the two siblings exhibited similar neurological symptoms, 18C2 showed more severe deficits in gross motor skills, skeletal development, and respiratory patterns (Figure 1c and Table 1). Romani also reported that patients with *CPLANE1* variants exhibited diverse JBTS phenotypes, with the OFD VI phenotype being the strongest (Romani et al., 2015). We surmise that the phenotypic heterogeneity may be due to the presence of genetic modifiers and that the genetic background of patients can alter the expressiveness of *CPLANE1* variants (Zaki et al., 2011). Recently, the first modifier of Joubert syndrome, a single locus of *Barttin*, was revealed for the first time in a mouse model (Ramsbottom et al., 2020). In-depth biostatistical and functional analyses are needed to reveal additional genes that alter *CPLANE1* variant-associated disease phenotypes.

In summary, we identified two new *CPLANE1* variants from JBTS and OFD VI patients. The two siblings carrying these two variants showed intrafamilial clinical heterogeneity.

## ACKNOWLEDGMENTS

We are grateful to the patients and their parents for the participation in this study. The work was supported by the National Key Research and Development Program (2016YFC1000307) Ministry of Science and Technology of the People's Republic of China (2016YFC1000307) to X.M., the Non-profit Central Research Institute Fund of National Research Institute for Family Planning (2020GJZ05) to M.L., National Natural Science Foundation of China (91954123, 31972887) to M.C., and Clinical Research Projects of Shanghai Municipal Health Commission (20194Y0133) to M.C.

## CONFLICT OF INTEREST

The authors declare no conflict of interest.

## AUTHOR CONTRIBUTIONS

Xu Ma, Zongfu Cao, Muqing Cao, Minna Luo, and Xian Wang conceived and supervised the project; Ping Li and Minna Luo collected the biological samples and clinical

information of the patients; Xiujuan Zhang and Yue Shen analyzed and interpreted the medical data; Xiujuan Zhang, Yue Shen, Chao Lu, Qian Li, and Tingting Cheng prepared the samples and performed human genetic testing; Zongfu Cao, Minna Luo, Ruikun Cai, Cuixia Chen, and Yufei Yu analyzed and interpreted the WES data. Xu Ma, Zongfu Cao, Muqing Cao, Xiujuan Zhang, and Minna Luo wrote the manuscript with the help of all other authors.

## DATA AVAILABILITY STATEMENT

The data in this study are available from the corresponding author (X.M.), upon reasonable request.

## ORCID

Yue Shen  <https://orcid.org/0000-0003-2797-9178>

Minna Luo  <https://orcid.org/0000-0003-1855-985X>

Muqing Cao  <https://orcid.org/0000-0002-0352-6548>

Xu Ma  <https://orcid.org/0000-0001-7674-3589>

## REFERENCES

- Alazami, A. M., Alshammari, M. J., Salih, M. A., Alzahrani, F., Hijazi, H., Seidahmed, M. Z., Abu Safieh, L., Aldosary, M., Khan, A. O., & Alkuraya, F. S. (2012). Molecular characterization of Joubert syndrome in Saudi Arabia. *Human Mutation*, 33(10), 1423–1428. <https://doi.org/10.1002/humu.22134>
- Asadollahi, R., Strauss, J. E., Zenker, M., Beuing, O., Edvardson, S., Elpeleg, O., Strom, T. M., Joset, P., Niedrist, D., Otte, C., Oneda, B., Boonsawat, P., Azzarello-Burri, S., Bartholdi, D., Papik, M., Zweier, M., Haas, C., Ekici, A. B., Baumer, A., ... Rauch, A. (2018). Clinical and experimental evidence suggest a link between KIF7 and C5orf42-related ciliopathies through Sonic Hedgehog signaling. *European Journal of Human Genetics*, 26(2), 197–209. <https://doi.org/10.1038/s41431-017-0019-9>
- Bayram, Y., Aydin, H., Gambin, T., Akdemir, Z. C., Atik, M. M., Karaca, E., Karaman, A., Pehlivan, D., Jhangiani, S. N., Gibbs, R. A., & Lupski, J. R. (2015). Exome sequencing identifies a homozygous C5orf42 variant in a Turkish kindred with oral-facial-digital syndrome type VI. *American Journal of Medical Genetics. Part A*, 167A(9), 2132–2137. <https://doi.org/10.1002/ajmg.a.37092>
- Ben-Salem, S., Al-Shamsi, A. M., Gleeson, J. G., Ali, B. R., & Al-Gazali, L. (2014). Mutation spectrum of Joubert syndrome and related disorders among Arabs. *Human Genome Variation*, 1, 14020. <https://doi.org/10.1038/hgv.2014.20>
- Bonnard, C., Shboul, M., Tonekaboni, S. H., Ng, A. Y. J., Tohari, S., Ghosh, K., Lai, A., Lim, J. Y., Tan, E. C., Devisme, L., Stichelboud, M., Alkindi, A., Banu, N., Yüksel, Z., Ghoumid, J., Elkhartoufi, N., Boutaud, L., Micalizzi, A., Brett, M. S., ... Kariminejad, A. (2018). Novel mutations in the ciliopathy-associated gene *CPLANE1* (C5orf42) cause OFD syndrome type VI rather than Joubert syndrome. *European Journal of Medical Genetics*, 61(10), 585–595. <https://doi.org/10.1016/j.ejmg.2018.03.012>
- Joubert, M., Eisenring, J. J., Robb, J. P., & Andermann, F. (1969). Familial agenesis of the cerebellar vermis. A syndrome of episodic hyperpnea, abnormal eye movements, ataxia, and retardation. *Neurology*, 19(9), 813–825. <https://doi.org/10.1212/wnl.19.9.813>
- Kroes, H. Y., Monroe, G. R., van der Zwaag, B., Duran, K. J., de Kovel, C. G., van Roosmalen, M. J., Harakalova, M., Nijman, I.

- J., Kloosterman, W. P., Giles, R. H., Knoers, N. V. A. M., & van Haaften, G. (2016). Joubert syndrome: Genotyping a Northern European patient cohort. *European Journal of Human Genetics*, 24(2), 214–220. <https://doi.org/10.1038/ejhg.2015.84>
- Liu, Q., Wang, H., Zhao, J., Liu, Z., Sun, D., Yuan, A., Luo, G., Wei, W., & Hou, M. (2020). Four novel compound heterozygous mutations in C5orf42 gene in patients with pure and mild Joubert syndrome. *International Journal of Developmental Neuroscience*, 80, 455–463. <https://doi.org/10.1002/jdn.10029>
- Lopez, E., Thauvin-Robinet, C., Reversade, B., Khartoufi, N. E., Devisme, L., Holder, M., Ansart-Franquet, H., Avila, M., Lacombe, D., Kleinfinger, P., Kaori, I., Takanashi, J.-I., Le Merrer, M., Martinovic, J., Noël, C., Shboul, M., Ho, L., Güven, Y., Razavi, F., ... Attié-Bitach, T. (2014). C5orf42 is the major gene responsible for OFD syndrome type VI. *Human Genetics*, 133(3), 367–377. <https://doi.org/10.1007/s00439-013-1385-1>
- Luo, M., Cao, L., Cao, Z., Ma, S., Shen, Y., Yang, D., Lu, C., Lin, Z., Liu, Z., Yu, Y., & Cai, R. (2019). Whole exome sequencing reveals novel CEP104 mutations in a Chinese patient with Joubert syndrome. *Molecular Genetics & Genomic Medicine*, 7(12), e1004. <https://doi.org/10.1002/mgg3.1004>
- Marshalla, P. (2007). Twenty-two fundamental methods of jaw, lip, and tongue facilitation. *International Journal of Orofacial Myology*, 33(1), 48–56.
- Ohba, C., Osaka, H., Iai, M., Yamashita, S., Suzuki, Y., Aida, N., Shimozawa, N., Takamura, A., Doi, H., Tomita-Katsumoto, A., Nishiyama, K., Tsurusaki, Y., Nakashima, M., Miyake, N., Eto, Y., Tanaka, F., Matsumoto, N., & Saito, H. (2013). Diagnostic utility of whole exome sequencing in patients showing cerebellar and/or vermis atrophy in childhood. *Neurogenetics*, 14(3–4), 225–232. <https://doi.org/10.1007/s10048-013-0375-8>
- Poretti, A., Vitiello, G., Hennekam, R. C. M., Arrigoni, F., Bertini, E., Borgatti, R., Brancati, F., D'Arrigo, S., Faravelli, F., Giordano, L., Huisman, T. A. G. M., Iannicelli, M., Kluger, G., Kyllerman, M., Landgren, M., Lees, M. M., Pinelli, L., Romaniello, R., Scheer, I., ... Boltshauser, E. (2012). Delineation and diagnostic criteria of Oral-Facial-Digital Syndrome type VI. *Orphanet Journal of Rare Diseases*, 7, 4. <https://doi.org/10.1186/1750-1172-7-4>
- Ramsbottom, S. A., Thelwall, P. E., Wood, K. M., Clowry, G. J., Devlin, L. A., Silbermann, F., Spiewak, H. L., Shril, S., Molinari, E., Hildebrandt, F., Gunay-Aygun, M., Saunier, S., Cordell, H. J., Sayer, J. A., & Miles, C. G. (2020). Mouse genetics reveals Barttin as a genetic modifier of Joubert syndrome. *Proceedings of the National Academy of Sciences of the United States of America*, 117(2), 1113–1118. <https://doi.org/10.1073/pnas.1912602117>
- Richards, S., Aziz, N., Bale, S., Bick, D., Das, S., Gastier-Foster, J., Grody, W. W., Hegde, M., Lyon, E., Spector, E., Voelkerding, K., & Rehm, H. L. (2015). Standards and guidelines for the interpretation of sequence variants: A joint consensus recommendation of the American College of Medical Genetics and Genomics and the Association for Molecular Pathology. *Genetics in Medicine*, 17(5), 405–424. <https://doi.org/10.1038/gim.2015.30>
- Romani, M., Mancini, F., Micalizzi, A., Poretti, A., Miccinilli, E., Accorsi, P., Avola, E., Bertini, E., Borgatti, R., Romaniello, R., Ceylaner, S., Coppola, G., D'Arrigo, S., Giordano, L., Janecke, A. R., Lituanica, M., Ludwig, K., Martorell, L., Mazza, T., ... Valente, E. M. (2015). Oral-facial-digital syndrome type VI: Is C5orf42 really the major gene? *Human Genetics*, 134(1), 123–126. <https://doi.org/10.1007/s00439-014-1508-3>
- Romani, M., Micalizzi, A., & Valente, E. M. (2013). Joubert syndrome: Congenital cerebellar ataxia with the molar tooth. *The Lancet Neurology*, 12(9), 894–905. [https://doi.org/10.1016/S1474-4422\(13\)70136-4](https://doi.org/10.1016/S1474-4422(13)70136-4)
- Srouf, M., Schwartzentruber, J., Hamdan, F. F., Ospina, L. H., Patry, L., Labuda, D., Massicotte, C., Dobrzyńska, S., Capo-Chichi, J.-M., Papillon-Cavanagh, S., Samuels, M. E., Boycott, K. M., Shevell, M. I., Laframboise, R., Désilets, V., Maranda, B., Rouleau, G. A., Majewski, J., & Michaud, J. L. (2012). Mutations in C5ORF42 cause Joubert syndrome in the French Canadian population. *American Journal of Human Genetics*, 90(4), 693–700. <https://doi.org/10.1016/j.ajhg.2012.02.011>
- Toriyama, M., Lee, C., Taylor, S. P., Duran, I., Cohn, D. H., Bruel, A.-L., Tabler, J. M., Drew, K., Kelly, M. R., Kim, S., Park, T. J., Braun, D. A., Pierquin, G., Biver, A., Wagner, K., Malfroot, A., Panigrahi, I., Franco, B., Al-lami, H. A., ... Wallingford, J. B. (2016). The ciliopathy-associated CPLANE proteins direct basal body recruitment of intraflagellar transport machinery. *Nature Genetics*, 48(6), 648–656. <https://doi.org/10.1038/ng.3558>
- Valente, E. M., Dallapiccola, B., & Bertini, E. (2013). Joubert syndrome and related disorders. *Handbook of Clinical Neurology*, 113, 1879–1888. <https://doi.org/10.1016/B978-0-444-59565-2.00058-7>
- Wentzensen, I. M., Johnston, J. J., Kepler-Noreuil, K., Acrich, K., David, K., Johnson, K. D., Graham, J. M., Sapp, J. C., & Biesecker, L. G. (2015). Exome sequencing identifies novel mutations in C5orf42 in patients with Joubert syndrome with oral-facial-digital anomalies. *Human Genome Variation*, 2, 15045. <https://doi.org/10.1038/hgv.2015.45>
- Wheway, G., Schmidts, M., Mans, D. A., Szymanska, K., Nguyen, T. M., Racher, H., Phelps, I. G., Toedt, G., Kennedy, J., Wunderlich, K. A., & Sorusch, N. (2015). An siRNA-based functional genomics screen for the identification of regulators of ciliogenesis and ciliopathy genes. *Nature Cell Biology*, 17(8), 1074–1087. <https://doi.org/10.1038/ncb3201>
- Zaki, M. S., Sattar, S., Massoudi, R. A., & Gleeson, J. G. (2011). Co-occurrence of distinct ciliopathy diseases in single families suggests genetic modifiers. *American Journal of Medical Genetics. Part A*, 155A(12), 3042–3049. <https://doi.org/10.1002/ajmg.a.34173>

**How to cite this article:** Zhang X, Shen Y, Li P, et al. Clinical heterogeneity and intrafamilial variability of Joubert syndrome in two siblings with *CPLANE1* variants. *Mol Genet Genomic Med*. 2021;9:e1682. <https://doi.org/10.1002/mgg3.1682>