

Distinctive pattern of temporal atrophy in patients with frontotemporal dementia and the I383V variant in *TARDBP*

INTRODUCTION

Frontotemporal dementia (FTD) and amyotrophic lateral sclerosis (ALS) are closely related disorders, linked pathologically and genetically by the TAR DNA-binding protein-43 (TDP-43). Pathogenic variants in *TARDBP* encoding for TDP-43 have been described less frequently in FTD than in ALS, and clinicopathological studies are scarce.¹ We previously observed a high frequency of the I383V variant in *TARDBP* in a Dutch cohort of FTD patients.² Here, we provide further evidence for the pathogenicity of this variant and present its clinicopathological characteristics.

METHODS

We ascertained all FTD (n=13) and ALS patients (n=4) with the I383V variant (NM_007375.3: c.1147A>G, p.Ile383Val) in *TARDBP* from three university medical centres in the Netherlands (Amsterdam, Rotterdam and Utrecht), as identified by whole-exome or whole-genome sequencing in either clinical or research setting. Concurrent pathogenic variants in 20 other genes associated with ALS, FTD or other forms of dementia were excluded in all patients.

Brain imaging (CT or MRI) was available for all FTD patients. Quantitative assessment of volume loss across lobar brain regions was performed in those patients with T1-weighted MRI images of sufficient quality (n=5), and compared with a gender-matched/age-matched reference population.

Family histories were classified into adjusted Goldman categories, which were described previously.² Additionally, we performed extensive genealogical research to investigate possible relatedness between the index patients.

Brain autopsy and routine immunohistochemistry was performed for two FTD patients by the Netherlands Brain Bank. One patient (4M) was reported previously as M008015-001.¹ Detailed information on the genetic, neuroimaging, genealogical and pathological analyses can be found in the 1.

RESULTS AND DISCUSSION

The variable clinical phenotype and reduced penetrance of the I383V variant

All 13 FTD patients with the I383V variant in *TARDBP* presented with a combination of behavioural changes and semantic deficits. The diagnoses of semantic variant of primary progressive aphasia (svPPA) are intriguing since this is usually considered a sporadic disorder. One patient (4M) showed additional motor symptoms, but not fulfilling ALS criteria. Of the 4 ALS patients with the I383V variant, 3 had a relatively slow progression with the longest disease duration of 9 years. None of the ALS patients exhibited cognitive or behavioural symptoms. Clinical details are presented in online supplemental tables 1,2.

Six FTD patients and one ALS patient were found to be related (family 1). Additionally, two FTD patients and two ALS patients (families 2 and 3) could be linked to family 1 through a distant common ancestor (figure 1). The variable phenotype of the I383V variant is exemplified by family 1, in which different family members were affected by svPPA, behavioural variant of FTD, unspecified dementia, ALS or progressive spinal muscular atrophy, with a wide range in age at onset (44–69 years) and disease duration (7–23 years). Interestingly, several obligate carriers were unaffected, suggesting incomplete penetrance even at an advanced age (>80 years). Larger prospective studies are required to estimate age-related penetrance.

Four remaining families (online supplemental figure 1) did not show a clear pattern of autosomal dominant inheritance (Goldman 2–5). In one of these families, an affected relative with the I383V variant was clinically diagnosed with Alzheimer's disease (AD), but AD biomarker changes were not evaluated in cerebrospinal fluid. A possible explanation is that the dementia in this patient is coincidental and unrelated to the I383V variant. Alternatively, increased susceptibility for AD caused by the I383V variant may be considered. Another interesting hypothesis is that *TARDBP* variants might be associated with limbic-predominant age-related TDP-43 encephalopathy, a common age-related disorder with TDP-43 proteinopathy that clinically mimics AD.³

Several other relatives, including obligate carriers, were affected by psychiatric disorders such as psychosis and schizophrenia with onset around 40–50 years. Unfortunately, detailed clinical information or DNA were not available for these

subjects. Whether psychiatric disorders are part of the I383V–*TARDBP* spectrum remains to be investigated in future studies. Altogether, our observations illustrate large phenotypic variability of the I383V variant and incomplete penetrance.

Isolated bitemporal atrophy in FTD patients with the I383V variant

The most discriminating feature of the I383V variant is the predominant and severe atrophy of the temporal lobes in all FTD patients, with relative sparing of the other lobes (figure 1 and online supplemental figure 2). This is in line with previous observations in I383V FTD patients and the frequent occurrence of semantic deficits and prosopagnosia in our patients (online supplemental table 1). Other pathogenic *TARDBP* variants (eg, K263E) are associated with a more variable pattern of lobar atrophy.¹ However, predominant temporal involvement has also been reported for other *TARDBP* variants located nearby the I383V variant (eg, A382T),⁴ suggesting a specific effect of missense variants in this part of the C-terminal domain of TDP-43. Further functional studies are needed to elucidate these possible genotype–phenotype correlations.

Heterogeneous pathological features in *TARDBP* patients

A remarkable observation is the scarcity of TDP-43 reactivity in the cortical areas of two FTD patients (patient 1F and the previously reported patient 4M¹), despite the underlying pathogenic *TARDBP* variant. Only several TDP-43 cytoplasmic inclusions of various morphologies were found in the frontal cortex, dentate gyrus and caudate nucleus (figure 1). A possible explanation for the scarce temporal pathology might be the severe neurodegeneration, especially considering the long disease duration of patient 1F (23 years). Interestingly, we also detected tau positive inclusions in the hippocampus and tufted astrocytes in the putamen and caudate nucleus (figure 1). A single other neuropathological study of a I383V carrier reported similar low amounts of TDP-43 inclusions, and the presence of α -synuclein deposits and tauopathy, including tufted astrocytes in the amygdala.⁵ It appears that the neuropathological changes in FTD caused by variants in *TARDBP* are not readily classifiable. Whether the detected co-pathologies occurred by chance needs to be determined in additional cases with TDP-43 variants.

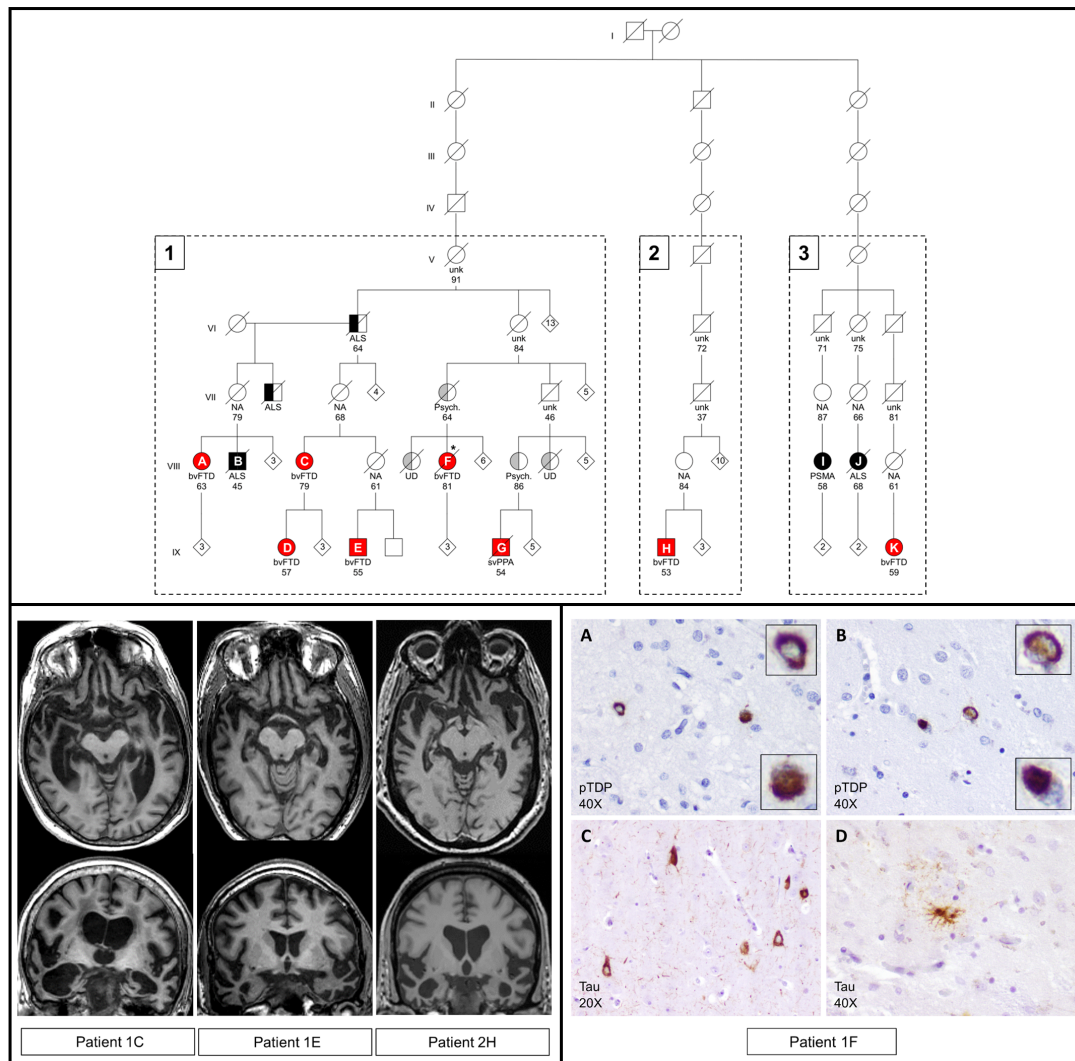


Figure 1 Pedigree of families 1–3 with radiological and pathological features.

Upper panel: three families were found to have a common ancestor following genealogical research. These families include 8 FTD patients and 3 ALS patients with a confirmed I383V variant in *TARDBP* (numbered A–K; fully coloured). Half coloured symbols represent patients with a clinical diagnosis without genetic testing. Red: clinical diagnosis of FTD or PPA. Black: clinical diagnosis of ALS or PSMA. Grey: relatives of index patients affected by other forms of dementia or psychiatric disorders. Numbers inside symbols represent additional family members without further clinical information. Numbers below the symbols indicate age at death or current age. Clinical diagnoses: bvFTD, behavioural variant of frontotemporal dementia; svPPA, semantic variant of primary progressive aphasia; ALS, amyotrophic lateral sclerosis; PSMA, progressive spinal muscular atrophy; UD, unspecified dementia; Psych, psychiatric disorder; NA, not affected based on family history; unk, disease status unknown. *Neuropathological examination (patient 1F).

Lower left panel: neuroimaging of three FTD patients with the I383V variant showing predominant bitemporal atrophy. MRI scans were obtained 7 years (1C), 6 years (1E) and 9 years (2H) after symptom onset. Quantitative analysis of volumetric loss per brain region is shown in online supplemental figure 2. Lower right panel: immunohistochemistry of patient 1F revealed several pTDP-43 positive neuronal cytoplasmic inclusions (NCI) of various morphologies in the frontal cortex (A) and nucleus caudate (B). Compared to other FTD-TDP cases, the amount of inclusions is low and intranuclear inclusions were not found. Therefore, this patient could not be readily classified into one of the FTLD-TDP subtypes. Staining with AT8 antibody revealed NCI in the hippocampus (C) and tufted astrocytes in nucleus caudate (D). Although this patient was 81 years at death, the observed tau pathology is not compatible with normal aging.

Classification of the I383V variant as likely pathogenic

Our findings indicate a pathogenic effect of the I383V variant, which was previously debated due to the more conservative amino acid substitution and the benign in silico predictions by SIFT and PolyPhen. The current families, especially family 1, clearly show segregation of the variant with the disease, although penetrance








appears incomplete. In addition to the patients described here, the I383V variant has been previously reported in 16 FTD and 8 ALS patients (online supplemental table 3), with frequencies ranging from 0% to 0.9% in ALS cohorts and from 0% to 2.5% in clinical FTD cohorts, while the variant is consistently absent in large groups of healthy controls from different populations. These data additionally

support its pathogenicity. This conclusion has clinical implications for genetic counselling of patients and unaffected family members, to whom presymptomatic testing and counselling can now be offered.

CONCLUSION

Our study provides sufficient evidence for the pathogenicity of the I383V variant

and contributes to the characterisation of *TARDBP*-related FTD. We demonstrate the large phenotypic variability and incomplete penetrance of the I383V variant. Marked isolated bitemporal volume loss in all FTD patients should prompt clinicians to genetically test for causal variants in *TARDBP*.

Merel O. Mol ¹, Sebastiaan W.R. Nijmeijer,² Jeroen G. J. van Rooij,¹ Resie M. L. van Spaendonk,² Yolande A. L. Pijnenburg ³, Sven J. van der Lee,³ Rick van Minkelen,⁴ Laura Donker Kaat,^{1,4} Annemieke J. M. Rozemuller,⁵ Mark R. Janse van Mantgem ⁶, Wouter van Rheenen,⁶ Michael A. van Es,⁶ Jan H. Veldink ⁶, Frederic A. M. Hennekam,⁷ Meike Vernooij ^{8,9}, John C. van Swieten ¹, Petra E. Cohn-Hokke,² Harro Seelaar ¹, Elise G.P. Dopper¹

¹Department of Neurology, Erasmus Medical Center, Rotterdam, The Netherlands

²Department of Clinical Genetics, Amsterdam UMC, Location VU University Medical Center, Amsterdam, The Netherlands

³Department of Neurology, Alzheimer Center, Amsterdam UMC, Location VU University Medical Center, Amsterdam, The Netherlands

⁴Department of Clinical Genetics, Erasmus Medical Center, Rotterdam, The Netherlands

⁵Department of Pathology, Amsterdam UMC, Location VU University Medical Center, Amsterdam, The Netherlands

⁶Department of Neurology, UMC Utrecht Brain Center, University Medical Center Utrecht, Utrecht, The Netherlands

⁷Department of Clinical Genetics, University Medical Center Utrecht, Utrecht, The Netherlands

⁸Department of Radiology and Nuclear Medicine, Erasmus Medical Center, Rotterdam, The Netherlands

⁹Department of Epidemiology, Erasmus Medical Center, Rotterdam, The Netherlands

Correspondence to Merel O. Mol, Department of Neurology, Erasmus Medical Center, 3015GD Rotterdam, Netherlands; m.o.mol@erasmusmc.nl

Twitter Harro Seelaar @HarroSeelaar

Acknowledgements We are indebted to all the patients who made this study possible. We also thank R. van 't Klooster from Quantib for assistance with the quantified volumetric data.

Contributors MOM and SWRN designed and conceptualised the study, analysed and interpreted all

data, and drafted and submitted the manuscript. YALP, SJL, LDK, MRJM, WR, MAE and JHV played a major role in the acquisition of data and revised the manuscript. JGJR, RM and RMLS analysed and interpreted the genetic data, and revised the manuscript. MV analysed and interpreted the neuroimaging data, and revised the manuscript. AJMR analysed and interpreted the pathological data. EAMH conducted genealogical research. JCVS, PCH, HS and EGPD designed and conceptualised the study, revised the manuscript and are responsible for the overall content as guarantors.

Funding This project has received funding from the European Research Council under the European Union's Horizon 2020 research and innovation programme (grant agreement no. 772376 – ESCORIAL).

Competing interests Several authors of this publication are members of the European Reference Network for Rare Neurological Diseases: Project ID No. 739510. JHV reports to have sponsored research agreements with Biogen.

Patient consent for publication Not required.

Ethics approval Approval of the study was provided by the Medical Ethics Review Board of the Erasmus Medical Center of Rotterdam (MEC-2019-170) and the Amsterdam Medical Center (MEC-2016-061). Ethical approval for the Netherlands Brain Bank (NBB) procedures and forms was given by the Medical Ethics Committee of the VU Medical Center, Amsterdam. Informed consent for the use of clinical and neuropathological data was obtained from all participants or their legal representatives. Brain autopsy was performed by the NBB at the designated premises of the VU Medical Center according to the code of conduct for Brain Banking and Declaration of Helsinki.

Supplemental material This content has been supplied by the author(s). It has not been vetted by BMJ Publishing Group Limited (BMJ) and may not have been peer-reviewed. Any opinions or recommendations discussed are solely those of the author(s) and are not endorsed by BMJ. BMJ disclaims all liability and responsibility arising from any reliance placed on the content. Where the content includes any translated material, BMJ does not warrant the accuracy and reliability of the translations (including but not limited to local regulations, clinical guidelines, terminology, drug names and drug dosages), and is not responsible for any error and/or omissions arising from translation and adaptation or otherwise.



OPEN ACCESS

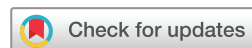Open access This is an open access article distributed in accordance with the Creative Commons Attribution 4.0 Unported (CC BY 4.0) license, which permits others

to copy, redistribute, remix, transform and build upon this work for any purpose, provided the original work is properly cited, a link to the licence is given, and indication of whether changes were made. See: <https://creativecommons.org/licenses/by/4.0/>.

© Author(s) (or their employer(s)) 2021. Re-use permitted under CC BY. Published by BMJ.

► Additional material is published online only. To view please visit the journal online (<http://dx.doi.org/10.1136/jnnp-2020-325150>).

MOM and SW.N contributed equally.



To cite Mol MO, Nijmeijer SW.R, van Rooij JGJ, *et al.* *J Neurol Neurosurg Psychiatry* 2021;**92**:787–789.

Received 18 September 2020

Revised 30 November 2020

Accepted 6 December 2020

Published Online First 15 January 2021

J Neurol Neurosurg Psychiatry 2021;**92**:787–789.
doi:10.1136/jnnp-2020-325150

ORCID iDs

Merel O. Mol <http://orcid.org/0000-0003-2533-2530>
Yolande A. L. Pijnenburg <http://orcid.org/0000-0003-2464-1905>

Mark R. Janse van Mantgem <http://orcid.org/0000-0002-5782-1980>

Jan H. Veldink <http://orcid.org/0000-0001-5572-9657>

Meike Vernooij <http://orcid.org/0000-0003-4658-2176>
John C. van Swieten <http://orcid.org/0000-0001-6278-6844>

Harro Seelaar <http://orcid.org/0000-0003-1989-7527>

REFERENCES

- Caroppo P, Camuzat A, Guillot-Noel L, *et al.* Defining the spectrum of frontotemporal dementias associated with *TARDBP* mutations. *Neurol Genet* 2016;**2**:e80.
- Mol MO, van Rooij JGJ, Wong TH, *et al.* Underlying genetic variation in familial frontotemporal dementia: sequencing of 198 patients. *Neurobiol Aging* 2021;**97**:148.e9
- Nelson PT, Dickson DW, Trojanowski JQ, *et al.* Limbic-predominant age-related TDP-43 encephalopathy (late): consensus Working Group report. *Brain* 2019;**142**:1503–27.
- Floris G, Borghero G, Cannas A, *et al.* Clinical phenotypes and radiological findings in frontotemporal dementia related to *TARDBP* mutations. *J Neurol* 2015;**262**:375–84.
- Gelpi E, van der Zee J, Turon Estrada A, *et al.* *TARDBP* mutation p.Ile383Val associated with semantic dementia and complex proteinopathy. *Neuropathol Appl Neurobiol* 2014;**40**:225–30.