

Outbreak of rabbit hemorrhagic disease virus 2 in the southwestern United States: first detections in southern California

Journal of Veterinary Diagnostic Investigation
 2021, Vol. 33(4) 728–731
 © 2021 The Author(s)
 Article reuse guidelines:
sagepub.com/journals-permissions
 DOI: 10.1177/10406387211006353
jvdi.sagepub.com

Javier Asin,¹ Akinyi C. Nyaoke, Janet D. Moore, Viviana Gonzalez-Astudillo,¹ Deana L. Clifford, Emma L. Lantz, Andrea B. Mikolon, Kimberly A. Dodd, Beate Crossley,¹ Francisco A. Uzal¹

Abstract. An outbreak of rabbit hemorrhagic disease virus 2 (RHDV2)-associated disease occurred in the southwestern United States following its first detection in New Mexico in March 2020. The disease spread throughout several states and was diagnosed for the first time in California on May 11, 2020, in a black-tailed jackrabbit (*Lepus californicus*). The following day, the California Department of Food and Agriculture (CDFA) issued an order banning the entrance into California of several lagomorph species and their products from any state in which the disease had been detected in the last 12 mo. RHDV2 is a threat to wild lagomorph species in California, including the endangered riparian brush rabbit (*Sylvilagus bachmani riparius*). Therefore, the California Department of Fish and Wildlife (CDFW) started tracking any mortality event in wild lagomorph populations. As of August 9, 2020, RHDV2 had been detected in wild and domestic lagomorphs of several counties in southern California that were submitted to the California Animal Health and Food Safety laboratory system by the CDFA or the CDFW. These positive cases included 2 additional black-tailed jackrabbits and 3 desert cottontail rabbits (*Sylvilagus audubonii*). In addition, the infection spilled over to domestic populations, whereby it was confirmed on July 10, 2020, in a domestic rabbit (*Oryctolagus cuniculus*).

Keywords: California; rabbit hemorrhagic disease virus 2; rabbits.

An outbreak of rabbit hemorrhagic disease (RHD) produced by rabbit hemorrhagic disease virus 2 (RHDV2), has been occurring in the southwestern United States since March 2020. As of August 9, cases have been confirmed in New Mexico, Arizona, Texas, Colorado, Nevada, California, and Utah. In California, cases have been detected in several southern counties, including Riverside, San Bernardino, San Diego, Orange, and Los Angeles (Fig. 1).

On May 7, 2020, the California Department of Fish and Wildlife (CDFW) submitted an adult, pregnant female, wild black-tailed jackrabbit (*Lepus californicus*) for autopsy and diagnostic workup to the San Bernardino branch of the California Animal Health and Food Safety (CAHFS) laboratory system. The animal was found dead north of Palm Springs, Riverside County, CA, in an area where several carcasses, some of which had evidence of previous nasal hemorrhage, had been found the week before. A presumptive diagnosis of RHD was established based on history, and gross and microscopic findings (Fig. 2). Grossly, the submitted animal had dried blood in and around the nares, a mild reticular pattern in the liver (Fig. 2A), congested lungs with rib impressions and subpleural hemorrhages (Fig. 2B), congested and hemorrhagic nasal turbinates, and hemorrhagic uterine serosa. Histology revealed periportal-to-panlobular, hepatic necrosis (Fig. 2C), severe pulmonary congestion and hemorrhages,

and fibrin microthrombi in pulmonary alveolar and renal glomerular capillaries (Fig. 2D). The USDA Animal and Plant Health Inspection Service, National Veterinary Services Laboratories–Foreign Animal Disease Diagnostic Laboratory (NVSL-FADDL) at Plum Island Animal Disease Center (Plum Island, NY) confirmed the presence of RHDV2 by reverse-transcription PCR (RT-PCR) in the liver from this animal on May 11, 2020. This was the first diagnosis of RHDV2-associated disease in California.

Diagnostic efforts were made to track this outbreak, and 43 wild and domestic lagomorphs with a suspicion of RHDV2-associated disease were submitted to CAHFS by the California Department of Food and Agriculture (CDFA)

California Animal Health and Food Safety Laboratory System, San Bernardino, USA (Asin, Nyaoke, Moore, Gonzalez-Astudillo, Uzal) and Davis (Crossley) Branches, and Department of Medicine and Epidemiology, School of Veterinary Medicine (Clifford), University of California–Davis, Davis, CA, USA; California Department of Fish and Wildlife, Sacramento, CA, USA (Clifford, Lantz); California Department of Food and Agriculture, Sacramento, CA, USA (Mikolon); USDA-APHIS National Veterinary Services Laboratories, Foreign Animal Disease Diagnostic Laboratory, Plum Island, NY, USA (Dodd).

¹Corresponding author: Francisco A. Uzal, California Animal Health and Food Safety, University of California–Davis, 105 W Central Ave, San Bernardino, CA 92408, USA. fauzal@ucdavis.edu

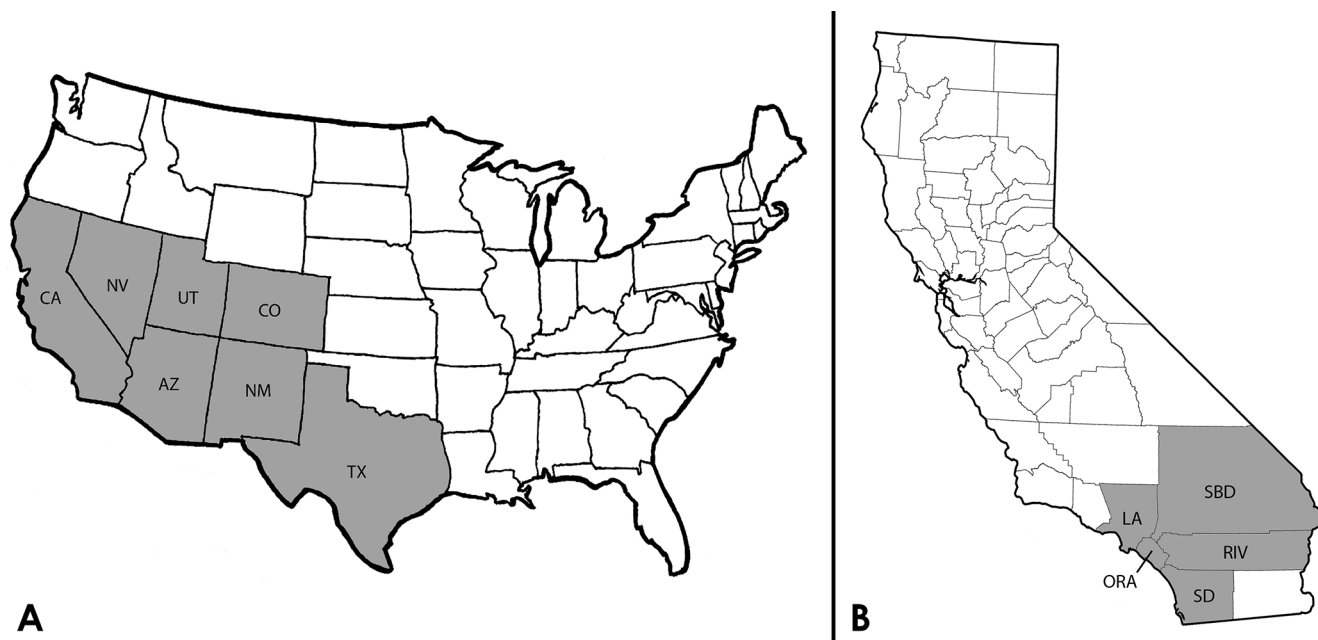


Figure 1. Rabbit hemorrhagic disease virus 2 detections in lagomorph populations of the southwestern United States and southern California as of August 9, 2020. **A.** States in which the virus has been detected. AZ = Arizona; CA = California; CO = Colorado; NM = New Mexico; NV = Nevada; TX = Texas; UT = Utah. **B.** Counties in California in which the virus has been detected. LA = Los Angeles; ORA = Orange; RIV = Riverside; SBD = San Bernardino; SD = San Diego. USDA-APHIS (<https://www.aphis.usda.gov/aphis/maps/animal-health/rhd>)

or the CDFW between May 7 and August 9. Increased awareness about this disease fostered these submissions, which had a history of simply “found dead” and/or compatible clinical signs such as blood around the nares. These submissions included 2 black-tailed jack rabbits (in addition to the first positive case), 19 desert cottontail rabbits (*Sylvilagus audubonii*), 1 brush rabbit (*Sylvilagus bachmani*), 1 riparian brush rabbit (*Sylvilagus bachmani riparius*), 17 domestic rabbits (*Oryctolagus cuniculus*), and 2 feral domestic rabbits (*Oryctolagus cuniculus*). Of those cases, NVSL-FADDL detected RHDV2 in the 2 black-tailed jackrabbits, 3 desert cottontail rabbits, and 1 domestic rabbit.

RHD is a non-zoonotic, highly contagious, frequently fatal disease of rabbits, caused by a non-enveloped, icosahedral, single-stranded RNA virus of the genus *Lagovirus*, family *Caliciviridae*.¹ This disease was originally associated with the classic RHD virus (RHDV). However, in 2010, a novel lagovirus called RHDV2 (also known as RHDVb, RHDV2/b, or GI.2) was detected in France and rapidly spread to other countries, displacing the classic RHDV variants that were circulating in those locations.²⁻⁴ Classic RHDV affects animals ≥ 8 wk old and is restricted mostly to domestic and wild European rabbits (*Oryctolagus cuniculus*), although there have been isolated detections in Iberian hares (syn. Granada hare; *Lepus granatensis*).^{3,5} The new variant RHDV2 affects animals of all ages and has a much broader host range that to date includes several hare species (*Lepus* spp.) and cottontail rabbits (*Sylvilagus* spp.),

in addition to European rabbits.^{3,4} Both viral variants are transmitted by direct contact with infected or dead animals, body fluids, and mechanical vectors, and certain wild rodents could act as reservoirs.³ Death frequently occurs as a result of acute necrotizing hepatitis with disseminated intravascular coagulation.

The clinicopathologic presentation of RHDV2-associated disease is very similar to that of classic RHD, although a slightly longer incubation period and clinical course are described for RHDV2-associated disease. Vaccines developed against classic RHDV do not confer protection against RHDV2. Multiple laboratory tests are available, and include electron microscopy, immunohistochemistry, serology, antigen ELISA, western blot, in situ hybridization, and RT-PCR. The latter is the most reliable and sensitive method; it can differentiate between RHDV and RHDV2, and is currently the test of choice in multiple countries, including the United States.²⁻⁴ The co-occurrence of classic RHD and RHDV2-associated disease in several geographic locations caused some confusion about the nomenclature of lagoviruses and their related diseases. In 2017, an international network of scientists proposed a unified classification system that included the genogroup and genotype of each virus. To date, the recommended common name for the new variant is GI.2/RHDV2/b.⁵

RHDV2 is a threat to domestic and wild lagomorph species in the United States. There are 8 wild lagomorph species in California, including the state and federally endangered riparian brush rabbit, that could potentially be infected by

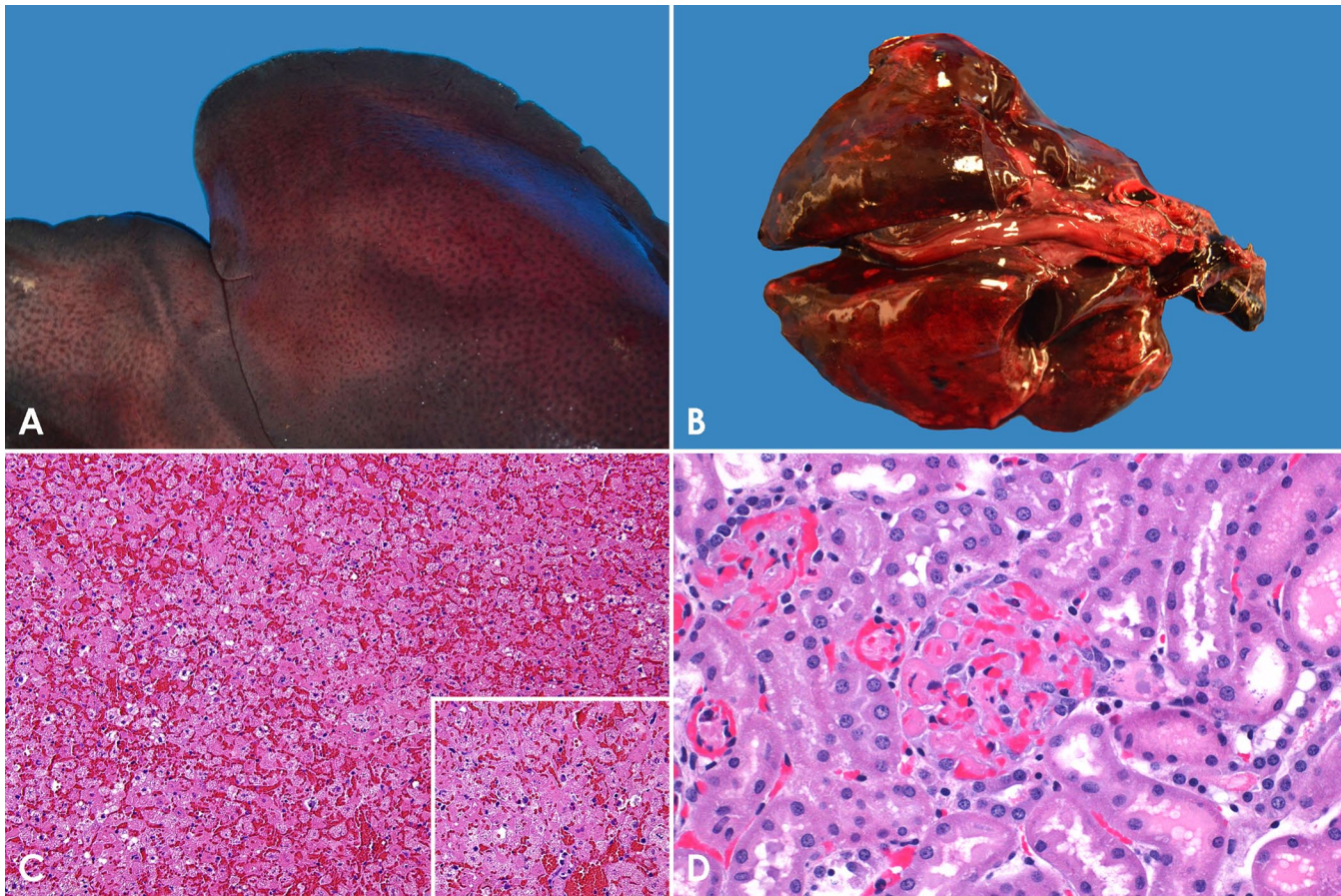


Figure 2. Rabbit hemorrhagic disease virus 2 (RHDV2)-associated lesions. **A–C.** Black-tailed jackrabbits (*Lepus californicus*) with RHDV2-associated disease. **A.** Slight hepatic pallor and mild reticular pattern. **B.** Swollen, wet, and congested lungs, with focal subpleural hemorrhages, and prominent rib impressions. **C.** Severe, massive hepatic necrosis, with congestion and hemorrhage. Inset: Higher magnification of necrotic hepatocytes. **D.** Domestic rabbit (*Oryctolagus cuniculus*) with RHDV2-associated disease. Fibrin microthrombi in renal glomerular capillaries.

RHDV2. An ever-present threat in areas where this disease is present in wild lagomorphs is spillover to the domestic rabbit populations. In California, this became a reality when RHDV2-associated disease was diagnosed for the first time in a domestic rabbit on July 10, 2020.

The CDFA issued an order on May 12, 2020, banning the entrance of rabbits, hares, and all their associated products and equipment from any state where the disease had been detected in the last 12 mo. The fact that the first diagnoses of RHDV2-associated disease in California were reported during the COVID-19 pandemic highlights the essential role of veterinary diagnostic laboratories and other regulatory agencies in maintaining animal and human health.

Acknowledgments

We thank Kelsey Clark, Jane Riner, and Nadia Javeed for their assistance in the CDFW outbreak response, and Dr. Carlos Calvete (CITA, Spain) for helpful discussions about RHD nomenclature. CAHFS case coordinators and technicians who performed autopsies of RHDV2-suspect cases are deeply acknowledged.

Declaration of conflicting interests

The authors declared no potential conflicts of interest with respect to research, authorship, and/or publication of this article.

Funding


The authors received no outside financial support for the research, authorship, and/or publication of this article.

ORCID iDs

Javier Asin  <https://orcid.org/0000-0002-6178-4801>

Viviana Gonzalez-Astudillo  <https://orcid.org/0000-0003-4208-361X>

Beate Crossley  <https://orcid.org/0000-0003-2932-7229>

Francisco A. Uzal  <https://orcid.org/0000-0003-0681-1878>

References

1. Abrantes J, et al. Rabbit haemorrhagic disease (RHD) and rabbit haemorrhagic disease virus (RHDV): a review. *Vet Res* 2012;43:12.

-
2. Le Gall-Reculé G, et al. Emergence of a new lagovirus related to Rabbit Haemorrhagic Disease Virus. *Vet Res* 2013;44:81.
 3. Delaney MA, et al. Lagomorpha. In: Terio KA, et al., eds. *Pathology of Wildlife and Zoo Animals*. 1st ed. Elsevier, 2018: 490–491.
 4. Gleeson M, Petritz OA. Emerging infectious diseases of rabbits. *Vet Clin North Am Exot Anim Pract* 2020;23:249–261.
 5. Le Pendu J, et al. Proposal for a unified classification system and nomenclature of lagoviruses. *J Gen Virol* 2017;98:1658–1666.