

# Debio1347, an Oral FGFR Inhibitor: Results From a Single-Center Study in Pediatric Patients With Recurrent or Refractory FGFR-Altered Gliomas

Sameer Farouk Sait, MBBS<sup>1,2</sup>; Stephen W. Gilheaney, MD, MMS<sup>1,2</sup>; Tejus A. Bale, MD, PhD<sup>3</sup>; Sofia Haque, MD<sup>4</sup>; Marc J. Dinkin, MD<sup>5</sup>; Stephanie Vitolano, MS<sup>1</sup>; Marc K. Rosenblum, MD<sup>3</sup>; Katarzyna Ibanez, MD<sup>6</sup>; Daniel E. Prince, MD, MPH<sup>7</sup>; Krisoula H. Spatz, PharmD<sup>8</sup>; Ira J. Dunkel, MD<sup>1,2</sup>; and Matthias A. Karajannis, MD, MS<sup>1,2</sup>

## INTRODUCTION

Recurrent genetic alterations of fibroblast growth factor receptors (FGFRs) leading to constitutive activation of FGFR signaling have been demonstrated in a variety of pediatric tumors, including gliomas.<sup>1-3</sup> Overall, up to 10% of pediatric low-grade gliomas (pLGGs) and 4% of pediatric high-grade gliomas (HGGs) harbor FGFR alterations.<sup>4</sup>

Debio1347 is an orally available, highly selective, ATP-competitive FGFR1-3 inhibitor with potent antitumor effect in preclinical models.<sup>5-7</sup> Debio1347 showed encouraging preliminary clinical activity in tumors harboring FGFR alterations and manageable safety profile in adults in its first in-human phase I study.<sup>7</sup> Measurement of Debio1347 unbound drug concentration in the CSF from an adult patient with thalamic glioblastoma receiving Debio1347 suggested significant CNS penetration (43% CSF-plasma ratio, Debiopharm internal data).

## METHODS

Five children with progressive or refractory CNS tumors harboring an FGFR gene alteration were treated at Memorial Sloan Kettering Cancer Center with Debio1347 under single patient use protocols approved by the institutional review board. Consents for publication of images were provided by the patients' guardians. The patients were treated using the 20-mg tablet formulation at the approximate body surface area-adjusted adult recommended phase II dose (80 mg/1.73 m<sup>2</sup> × body surface area once daily). Tablets were crushed and suspended in water when needed. Toxicities were graded using the National Cancer Institute Common terminology Criteria for Adverse Events version 4.0. Plain radiographs of tibial growth plates, ECG, echocardiogram, and imaging response assessments were performed every 8-12 weeks. Two-dimensional measurements were used to assess response (product of the two largest perpendicular diameters). Partial response (PR) and progressive disease were defined by a > 50% decrease or > 25% increase in tumor measurements, respectively.

## RESULTS

### Clinical Features

Three patients had low-grade gliomas and two patients had HGGs. Three patients had *FGFR1* mutations and two patients had *FGFR-TACC* fusions. The median age at treatment was 8 years (range, 13 months-14 years). Most participants (4/5) had received ≥ 1 previous chemotherapy or radiotherapy regimen. Clinical characteristics, previous treatments, and tumor FGFR status of enrolled participants are summarized in [Table 1](#).

### Toxicity

The treatment showed tolerable toxicity and all adverse events (AEs) related to Debio1347 were grade 1-2. No patient required dose modifications. Most common treatment-related AEs were hyperphosphatemia, ALT increase, and hypoalbuminemia ([Appendix Table A1](#)).

FGFR signaling plays a role in the regulation of bone development. Toxicities in skeletally immature patients are unknown. Two subjects in our cohort experienced skeletal complications; careful review of growth charts demonstrated increased linear growth velocity as evidenced by an increase in height crossing two percentile lines (from 75th to 97th). Radiographs in both patients demonstrated unfused tibial growth plates. Subject 2 developed bilateral slipped capital femoral epiphysis (SCFE), requiring percutaneous screw stabilization of both hips. The patient had several independent risk factors for SCFE, including a phase of rapid growth, race, and obesity, coupled with endocrine abnormalities.<sup>8</sup> Subject 3 developed bilateral knee pain (left > right) following 9 months of drug therapy. Knee magnetic resonance imaging demonstrated osteochondritis dissecans. The event was deemed unrelated, and a decision was made to continue drug therapy.

### Response to Therapy

Among the four evaluable patients, two subjects (one pediatric HGG and one pLGG) experienced sustained PRs, whereas two subjects experienced prolonged

## ASSOCIATED CONTENT

### Appendix

Author affiliations and support information (if applicable) appear at the end of this article.

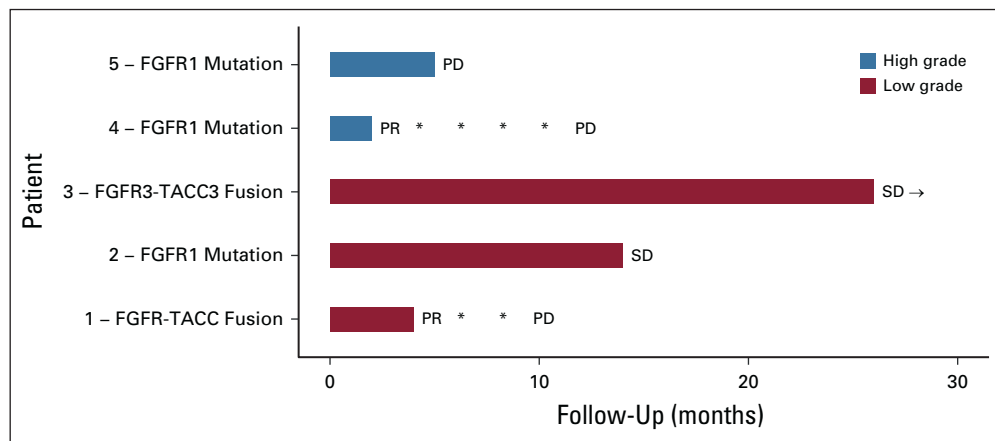
Accepted on April 16, 2021 and published at [ascopubs.org/journal/po](https://ascopubs.org/journal/po) on May 20, 2021; DOI <https://doi.org/10.1200/P0.20.00444>

**TABLE 1.** Disease and Treatment Details for Patients Treated With Debio1347

Subject	Age at Diagnosis/ Age at Start of Treatment	Tumor Type	FGFR Alteration	No. of Previous Lines of Therapy	Previous Treatment	Interval Between Previous Therapy to Start of Debio1347	Best Overall Response With Best Overall Change in Tumor Size
Low-grade gliomas or glioneuronal tumors							
1	8 months/26 months	Optic pathway pilomyxoid astrocytoma	<i>FGFR1-TACC1 fusion (FGFR1 exon 16—TACC1 exon 7)</i>	3	Carboplatin or vincristine, vinblastine, and temozolomide or bevacizumab	6 months	PR (−74.5%)
2	4 years/8 years	Optic pathway pilomyxoid astrocytoma	<i>FGFR1 V592M, K687E</i>	1	Carboplatin or temozolomide	34 months	SD (−12%)
3	13 years/14 years	Rosette-forming low-grade glioneuronal tumor	<i>FGFR3-TACC3 (FGFR3 exons 1-18—TACC3 exons 10-16: c.2325:FGFR3_c.1837-110: TACC3dup)</i>	Surgery only (partial resection)		—	SD (−7.2%)
High-grade gliomas							
4	8 months/13 months	Spinal cord (T1-T8) high-grade glioma	<i>FGFR1 mutations (V592M, K687E)</i>	1	Intensive induction chemotherapy (without methotrexate) and consolidation with stem cell rescue (as per COG ACNS0334 protocol)	6 weeks	PR (−96.3%)
5	8 years/8 years	Cerebellar glioblastoma	<i>FGFR1 N577K</i>	1	Focal RT	6 weeks	NE

Abbreviations: COG, Children’s Oncology Group; FGFR, fibroblast growth factor receptor; NE, not evaluable; PR, partial response; RT, radiation therapy; SD, stable disease.

**FIG 1.** Swimmers plot demonstrating the duration of responses in the five subjects. \*Subjects 1 and 4 had PR, which was maintained at multiple assessments. → Subject 3 continues on therapy with continued SD. PD, progressive disease; PR, partial response; SD, stable disease.



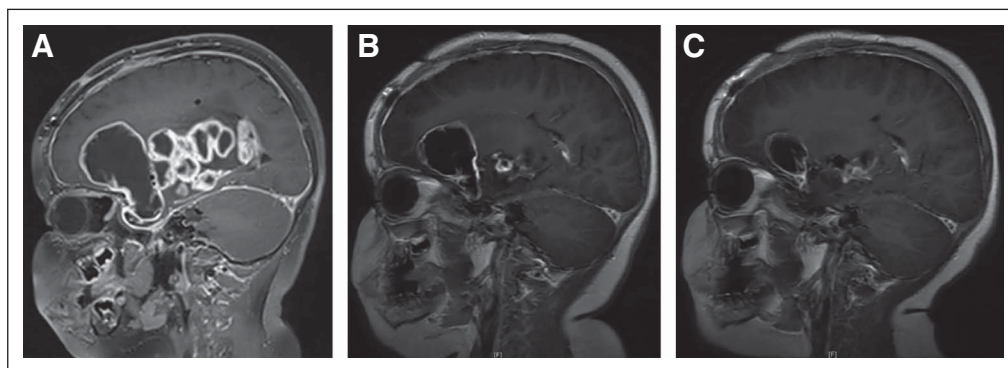
disease stabilization (stable disease [SD]) (Fig 1). Subject 2 also experienced an objective improvement in visual fields and acuity, along with SD on imaging for 8 months on therapy, which was sustained for an additional 6 months off treatment. Subject 5 had nonmeasurable disease at baseline. Reasons for therapy discontinuation included disease progression (n = 3), family preference (n = 1), and one patient continues on therapy to this date. Individual treatment outcomes are summarized below.

#### Low-Grade Gliomas

Subject 1 is an 8-month-old infant with a biopsy-confirmed optic pathway pilomyxoid astrocytoma, which was refractory to multiple (4) pLGG chemotherapy regimens. Whole-exome sequencing of the primary tumor showed no significant findings except for a large deletion on chromosome 8p11.2, flanking *FGFR1* and *TACC*, along with an *FGFR1*

variant of unknown significance (*NM\_023110.2, c.2294A>G, p.E765G*) with a variant allele frequency of 26%. Transcriptome sequencing revealed an *FGFR1-TACC1* fusion (*FGFR1* exon 16—*TACC1* exon 7). Treatment with Debio1347 was initiated, and a PR was achieved following six cycles of therapy (maximal tumor reduction of 74.5%), which was sustained for 9 months (Fig 2). Memorial Sloan Kettering-Integrated Mutation Profiling of Actionable Cancer Targets (MSK-IMPACT) DNA sequencing<sup>9</sup> of the recurrent or progressive tumor revealed a newly acquired *NF1* deletion in addition to the retained *FGFR1-TACC1* fusion detected by MSK-Solid Fusion Assay.<sup>10</sup>

Subject 2 is a 4-year-old with a biopsy-confirmed optic pathway pilomyxoid astrocytoma with multiple spinal metastases and chemotherapy refractory residual disease. The patient later developed acute-onset visual decline (20/800 visual acuity bilaterally) prompting emergent



**FIG 2.** (A) Sagittal T1 postcontrast MR brain imaging demonstrates a multilobulated cystic and solid, predominantly peripherally enhancing tumor arising in the region of the optic chiasm and hypothalamus and involving the basal ganglia and deep gray matter structures of the right cerebellum in subject 1. (B) Repeat imaging at 20 weeks following initiation of Debio1347 demonstrating decrease in heterogeneously enhancing solid and cystic lesion in the right greater than left optic pathways, decreased heterogeneously enhancing solid components in the inferior medial right basal ganglia and thalamus, decreased large peripherally enhancing cystic component in the right frontal region, and decreased posterior extension into the interpeduncular and prepontine cistern. (C) Repeat imaging at 28 weeks after initiation of Debio1347 demonstrating continued partial response. MR images from subject 2 (consent obtained). MR, magnetic resonance.

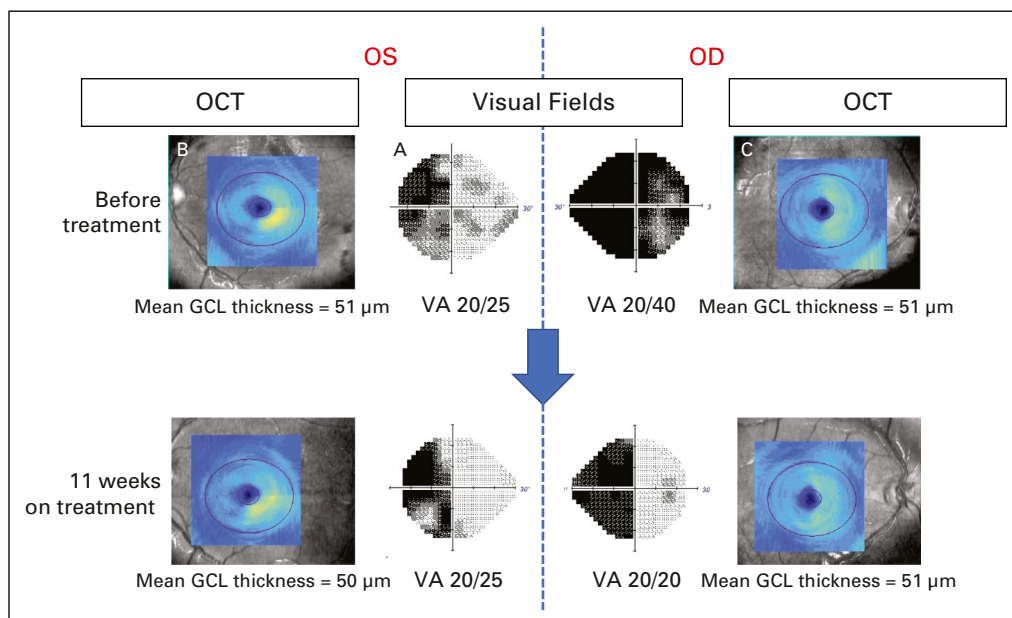
ventriculo-peritoneal shunt revision because of concern for overshunting, and a short course of steroids were administered with improvement in vision (visual acuity 20/40 bilaterally). MSK-IMPACT testing performed on CSF demonstrated *FGFR1 V592M* and *K687E* mutations. Because of concern for worsening visual decline and CSF seeding, the patient started tumor-directed treatment with Debio1347. Three months after treatment with Debio1347, a clinically significant improvement in visual fields and visual acuity was observed (Fig 3). The patient experienced a serious adverse effect (bilateral SCFE) during course 9, as described above. Although this serious adverse effect was considered unrelated to Debio1347, the family elected to discontinue therapy. Surveillance imaging demonstrated SD (maximal tumor reduction 12.2%). Repeat visual fields and optical coherence tomography 14 months after treatment initiation demonstrated sustained improvement in visual fields and stable structural integrity.

Subject 3 is a 13-year-old patient with a posterior fossa (right cerebellar hemispheric tumor circumscribing the

brainstem and extending into the C2 spine) rosette-forming glioneuronal tumor harboring an *FGFR3-TACC3* fusion. Following a partial resection, the patient experienced clinical and radiographic progression. The family declined chemotherapy, and the patient started treatment with Debio1347. Prolonged SD was demonstrated on imaging (26 months), and the patient remains on therapy. Neurologic symptoms (headaches, ataxia, and dysmetria) remained stable to minimally improved.

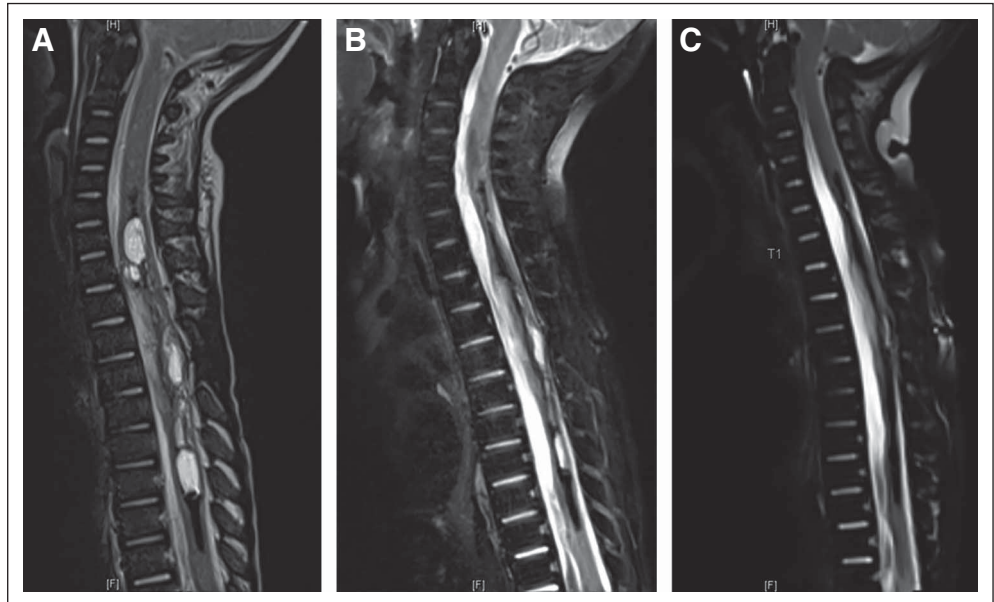
### High-Grade Gliomas

Subject 4 is an 8-month-old infant with a biopsy-confirmed spinal cord glioblastoma extending from T1-T8 and chemotherapy refractory residual disease. MSK-IMPACT DNA sequencing<sup>9</sup> demonstrated *FGFR1 V592M* and *K687E* mutations. Treatment with Debio1347 was started 6 weeks after completion of intensive chemotherapy with stem-cell rescue and led to a striking rapid imaging response at 2 months and ultimately near complete response (maximal tumor reduction of 96.3%), which was maintained for 11 months (Fig 4).



**FIG 3.** Improvement in visual fields and acuity, and stable optic nerve structural assessment in subject 2. Ophthalmologic assessment before and 11 weeks after treatment with Debio1347. Humphrey visual fields before therapy (center panels) revealed a combined LHH, from right optic tract involvement, and a bitemporal hemianopia from simultaneous optic chiasmatal compression, whereas best-corrected VAs were 20/40 OD and 20/25 OS. Structural assessment of the retinal GCL using OCT demonstrated a thinning of the right retina in both eyes consistent with permanent neuronal loss related to the LHH or optic tract compression (note the lack of normal yellow color on the left side images [B] and [C], reflecting right retinal thinning in the OS and OD, respectively). Mean GCL thicknesses were 51  $\mu\text{m}$  in both eyes. Three months after treatment with Debio1347, repeat visual fields revealed a resolution of the temporal loss OD, reflective of resolved bitemporal hemianopsia, although the LHH persisted, and VAs improved to 20/20 OD and 20/25 OS. OCT demonstrated stable GCL thinning, confirming no further damage to the optic apparatus during that period. Repeat visual fields and OCT 14 months after treatment began (not shown) demonstrated persistent improvement in visual fields and stable structural integrity. GCL, ganglion cell layer; LHH, left homonymous hemianopia; OCT, optical coherence tomography; OD, right eye; OS, left eye; VA, visual acuity.

**FIG 4.** Sagittal T2 weight fat-suppressed MR spine imaging demonstrates (A) an expansile cystic and solid tumor in subject 4 centered within the spinal cord spanning from C5-C6 level through T9 level with evidence of hemosiderin deposition and/or mineralization along several of the cystic elements, and (B) marked decrease in the cystic and solid tumor component upon repeat imaging after 8 weeks of therapy. (C) Near-complete response (96.3% reduction in bidimensional measurement) on repeat imaging performed following 18 weeks of therapy. MR images from subject 1 (consent obtained). MR, magnetic resonance.



Subject 5 is an 8-year-old patient with left cerebellar HGG, which belonged to a recently described subclass of histone wild-type glioblastoma with loss of H3K27 trimethylation<sup>11</sup> and very poor prognosis. The tumor was found to have an *FGFR1 N577K* missense mutation, *TP53* mutation, and multiple chromosome-level losses and gains. He completed 33 fractions of focal photon radiation therapy to a total dose of 59.4 Gy, followed by adjuvant therapy with Debio1347 after 6 weeks of rest. Disease progression with craniospinal dissemination was noted after 5 months (7.5 months after radiation therapy).

## DISCUSSION

FGFR inhibitors have previously been investigated in adult patients with FGFR-altered HGGs. Five patients with primary brain tumors harboring an *FGFR3-TACC3* fusion were treated with Debio1347 as part of a phase I study; however, no responses were observed.<sup>12</sup> One PR was reported among three patients with recurrent glioblastoma harboring *FGFR3-TACC3* fusions treated with erdafitinib.<sup>13-15</sup> A phase II trial of infigratinib, an FGFR1-3 inhibitor,<sup>16</sup> demonstrated PR or SD in approximately one third of patients with recurrent or refractory FGFR-altered HGGs.<sup>16</sup> In our study, subject 4 was an infant with spinal cord glioblastoma who demonstrated a sustained PR on therapy; however, response attribution is confounded by the previous administration of intensive chemotherapy. The *FGFR1 K687E* mutation in subject 4 is considered a hotspot pathogenic alteration and has been reported in subjects with gliomas,<sup>17</sup> including a patient with anaplastic oligodendroglioma who experienced a PR to an FGFR tyrosine kinase inhibitor in a phase I study.<sup>18</sup>

By contrast, pLGGs predominantly consist of single oncogenic driver entities considered susceptible to molecular

targeted therapies. We observed objective imaging responses to Debio1347 in pediatric patients with FGFR-altered low-grade gliomas, as well as functional responses with improved vision in subject 2.

Interestingly, *FGFR1* single nucleotide variants frequently co-occur with *NF1* alterations or additional mutations in components of *RAS/MAPK/PI3K* pathway.<sup>19,20</sup> Understanding the differential activation of signal transduction pathways using preclinical models will be important in determining whether cancer cells depend primarily on FGFR signaling for growth and survival and lead to the identification of appropriate biomarkers that would be predictive of efficacy.<sup>21,22</sup>

Our patient series is limited by small numbers, disease heterogeneity, retrospective nature, as well as lack of preclinical data in pediatric glioma models and PK or progressive disease studies. Nonetheless, our results demonstrate several novel findings, which can help guide the development of clinical trials in this population: (1) this is the first report in the literature documenting treatment of pediatric patients with recurrent or refractory brain tumors harboring FGFR alterations with a specific FGFR inhibitor, (2) Debio1347 demonstrated tolerable toxicity and promising antitumor efficacy; however, a phase I dose-escalation study to identify rare AEs and optimal drug dosing is required before a phase II study to evaluate efficacy, (3) we identified candidate biomarkers (*FGFR1 K687M* and *V592M* mutations, *FGFR-TACC* fusions) that may be associated with efficacy of FGFR targeted therapy, and (4) identified *NF1* deletion as a novel molecular mechanism of acquired resistance to FGFR inhibition.

## AFFILIATIONS

<sup>1</sup>Department of Pediatrics, Memorial Sloan Kettering Cancer Center, New York, NY

<sup>2</sup>Department of Pediatrics, Weill Cornell Medical College, New York, NY

<sup>3</sup>Department of Pathology, Memorial Sloan Kettering Cancer Center, New York, NY

<sup>4</sup>Department of Radiology, Memorial Sloan Kettering Cancer Center, New York, NY

<sup>5</sup>Department of Ophthalmology and Neurology, Weill Cornell Medical College, New York, NY

<sup>6</sup>Department of Neurology, Memorial Sloan Kettering Cancer Center, New York, NY

<sup>7</sup>Department of Orthopedics, Memorial Sloan Kettering Cancer Center, New York, NY

<sup>8</sup>Department of Pharmacy, Memorial Sloan Kettering Cancer Center, New York, NY

## CORRESPONDING AUTHOR

Matthias A. Karajannis, MD, MS, Memorial Sloan Kettering Cancer Center, 1275 York Ave, New York, NY 10065; e-mail: karajanm@mskcc.org.

## SUPPORT

Investigational drug Debio1347 was provided by Debiopharm International SA under Single Patient Use protocols. This work was funded in part by the Marie-Josée and Henry R. Kravis Center for Molecular Oncology and the National Cancer Institute Cancer Center Core Grant No. P30 CA008748.

## AUTHOR CONTRIBUTIONS

**Conception and design:** Sameer Farouk Sait, Krisoula H. Spatz, Ira J. Dunkel, Matthias A. Karajannis

**Administrative support:** Matthias A. Karajannis

**Provision of study materials or patients:** Stephen W. Gilheaney, Daniel E. Prince, Ira J. Dunkel, Matthias A. Karajannis

**Collection and assembly of data:** Sameer Farouk Sait, Stephen W. Gilheaney, Tejus A. Bale, Sofia Haque, Marc J. Dinkin, Stephanie Vitolano, Marc K. Rosenblum, Ira J. Dunkel, Matthias A. Karajannis

**Data analysis and interpretation:** Sameer Farouk Sait, Tejus A. Bale, Katarzyna Ibanez, Daniel E. Prince, Ira J. Dunkel

**Manuscript writing:** All authors

**Final approval of manuscript:** All authors

**Accountable for all aspects of the work:** All authors

## AUTHORS' DISCLOSURES OF POTENTIAL CONFLICTS OF INTEREST

The following represents disclosure information provided by the authors of this manuscript. All relationships are considered compensated unless otherwise noted. Relationships are self-held unless noted. I = Immediate

Family Member, Inst = My Institution. Relationships may not relate to the subject matter of this manuscript. For more information about ASCO's conflict of interest policy, please refer to [www.asco.org/rwc](http://www.asco.org/rwc) or [ascopubs.org/po/author-center](http://ascopubs.org/po/author-center).

Open Payments is a public database containing information reported by companies about payments made to US-licensed physicians ([Open Payments](http://Open Payments)).

### Sameer Farouk Sait

**Consulting or Advisory Role:** AstraZeneca

**Uncompensated Relationships:** QED Therapeutics

### Sofia Haque

**Honoraria:** Advance Medical

**Consulting or Advisory Role:** Advance Medical

### Marc J. Dinkin

**Employment:** CareMount Medical

**Research Funding:** Serenity Therapeutics

**Expert Testimony:** Medical Experts Nationwide, Ekblom & Partners LLP

### Stephanie Vitolano

**Stock and Other Ownership Interests:** Pfizer

### Daniel E. Prince

**Stock and Other Ownership Interests:** Modernizing Medicine

**Open Payments Link:** <https://openpaymentsdata.cms.gov/physician/289528>

### Ira J. Dunkel

**Consulting or Advisory Role:** Apexigen, Celgene, Roche/Genentech, AstraZeneca, Fennec Pharma, Bristol Myers Squibb, QED Therapeutics, Day One Therapeutics

**Research Funding:** Bristol Myers Squibb, Genentech, Novartis

### Matthias A. Karajannis

**Stock and Other Ownership Interests:** Johnson & Johnson (I)

**Consulting or Advisory Role:** Bayer, Recursion Pharmaceuticals, QED Therapeutics, CereXis, AstraZeneca

**Research Funding:** Novartis

**Travel, Accommodations, Expenses:** Bayer, Debiopharm Group

**Uncompensated Relationships:** Debiopharm Group

**Open Payments Link:** <https://openpaymentsdata.cms.gov/physician/710370/summary>

No other potential conflicts of interest were reported.

## ACKNOWLEDGMENT

The authors gratefully acknowledge the members of the Memorial Sloan Kettering Molecular Diagnostics Service in the Department of Pathology. The authors would like to thank Joseph Olechnowicz for editorial assistance and Dr Audrey Mauguen for assistance with biostatistical analysis.

## REFERENCES

- Hierro C, Rodon J, Tabernero J: Fibroblast growth factor (FGF) receptor/FGF inhibitors: Novel targets and strategies for optimization of response of solid tumors. *Semin Oncol* 42:801-819, 2015
- Parker BC, Engels M, Annala M, et al: Emergence of FGFR family gene fusions as therapeutic targets in a wide spectrum of solid tumours. *J Pathol* 232:4-15, 2014
- Dienstmann R, Rodon J, Prat A, et al: Genomic aberrations in the FGFR pathway: Opportunities for targeted therapies in solid tumors. *Ann Oncol* 25:552-563, 2014
- Zhang J, Wu G, Miller CP, et al: Whole-genome sequencing identifies genetic alterations in pediatric low-grade gliomas. *Nat Genet* 45:602-612, 2013
- Nakanishi Y, Akiyama N, Tsukaguchi T, et al: The fibroblast growth factor receptor genetic status as a potential predictor of the sensitivity to CH5183284/Debio 1347, a novel selective FGFR inhibitor. *Mol Cancer Ther* 13:2547-2558, 2014
- Chessex AV, Moulon C, Nicolas-Métral V, et al: 547 Preclinical activity of Debio 1347, an oral selective FGFR1, 2, 3 inhibitor, in models harboring FGFR alterations. *Eur J Cancer* 50:177-178, 2014

7. Voss MH, Hierro C, Heist RS, et al: A phase I, open-label, multicenter, dose-escalation study of the oral selective FGFR inhibitor Debio 1347 in patients with advanced solid tumors harboring FGFR gene alterations. *Clin Cancer Res* 25:2699-2707, 2019
8. Novais EN, Millis MB: Slipped capital femoral epiphysis: Prevalence, pathogenesis, and natural history. *Clin Orthop Relat Res* 470:3432-3438, 2012
9. Cheng DT, Mitchell TN, Zehir A, et al: Memorial Sloan Kettering-Integrated Mutation Profiling of Actionable Cancer Targets (MSK-IMPACT): A hybridization capture-based next-generation sequencing clinical assay for solid tumor molecular oncology. *J Mol Diagn* 17:251-264, 2015
10. Zheng Z, Liebers M, Zhelyazkova B, et al: Anchored multiplex PCR for targeted next-generation sequencing. *Nat Med* 20:1479-1484, 2014
11. Castel D, Kergrohen T, Tauziède-Espariat A, et al: Histone H3 wild-type DIPG/DMG overexpressing EZHIP extend the spectrum diffuse midline gliomas with PRC2 inhibition beyond H3-K27M mutation. *Acta Neuropathol* 139:1109-1113, 2020
12. Cleary JM, Iyer G, Oh D-Y, et al: Final results from the phase I study expansion cohort of the selective FGFR inhibitor Debio 1,347 in patients with solid tumors harboring an FGFR gene fusion. *J Clin Oncol* 38:3603, 2020
13. Bahleda R, Italiano A, Hierro C, et al: Multicenter phase I study of erdafitinib (JNJ-42756493), oral Pan-fibroblast growth factor receptor inhibitor, in patients with advanced or refractory solid tumors. *Clin Cancer Res* 25:4888-4897, 2019
14. Taberero J, Bahleda R, Dienstmann R, et al: Phase I dose-escalation study of JNJ-42756493, an oral pan-fibroblast growth factor receptor inhibitor, in patients with advanced solid tumors. *J Clin Oncol* 33:3401-3408, 2015
15. Di Stefano AL, Fucci A, Frattini V, et al: Detection, characterization, and inhibition of FGFR-TACC fusions in IDH wild-type glioma. *Clin Cancer Res* 21:3307-3317, 2015
16. Lassman AB, Sepúlveda-Sánchez JM, Cloughesy T, et al: OS10.6 infigratinib (BGJ398) in patients with recurrent gliomas with fibroblast growth factor receptor (FGFR) alterations: A multicenter phase II study. *Neuro Oncol* 21:iii21-iii22, 2019
17. Gareton A, Tauziède-Espariat A, Dangoulouff-Ros V, et al: The histomolecular criteria established for adult anaplastic pilocytic astrocytoma are not applicable to the pediatric population. *Acta Neuropathol* 139:287-303, 2020
18. Bahleda R, Meric-Bernstam F, Goyal L, et al: Phase I, first-in-human study of futibatinib, a highly selective, irreversible FGFR1-4 inhibitor in patients with advanced solid tumors. *Ann Oncol* 31:1405-1412, 2020
19. Ryall S, Zapotocky M, Fukuoka K, et al: Integrated molecular and clinical analysis of 1,000 pediatric low-grade gliomas. *Cancer Cell* 37:569-583.e5, 2020
20. Sievers P, Appay R, Schrimpf D, et al: Rosette-forming glioneuronal tumors share a distinct DNA methylation profile and mutations in FGFR1, with recurrent co-mutation of PIK3CA and NF1. *Acta Neuropathol* 138:497-504, 2019
21. Katoh M: Fibroblast growth factor receptors as treatment targets in clinical oncology. *Nat Rev Clin Oncol* 16:105-122, 2019
22. Babina IS, Turner NC: Advances and challenges in targeting FGFR signalling in cancer. *Nat Rev Cancer* 17:318-332, 2017



## APPENDIX

TABLE A1. List of AEs Related to Debio1347

AE	No. of Subjects by AE	Highest Grade	No. of Subjects by AE and by Highest Grade
ALT increased	4	Grade 1	3
		Grade 2	1
Hyperphosphatemia	4	Grade 2	4
Hypoalbuminemia	4	Grade 1	4
AST increased	3	Grade 1	3
Agitation	2	Grade 1	1
		Missing	1
Blood bilirubin increased	2	Grade 1	1
		Grade 2	1
Constipation	2	Grade 1	1
		Grade 2	1
Diarrhea	2	Grade 1	2
Hypokalemia	2	Grade 1	2
Hypomagnesemia	2	Grade 1	2
Vomiting	2	Grade 1	1
		Missing	1
Alopecia	1	Grade 1	1
Blurred vision	1	Grade 1	1
Epistaxis	1	Grade 1	1
Headache	1	Grade 1	1
Hip pain	1	Grade 1	1
Hypercalcemia	1	Grade 1	1
Myalgia	1	Grade 1	1
Nail loss	1	Grade 1	1
Nausea	1	Grade 1	1
Pruritus	1	Grade 1	1
Rhinorrhea	1	Grade 1	1
Weight gain	1	Grade 1	1

Abbreviation: AE, adverse event.