



# Anti-Myelin Oligodendrocyte Glycoprotein Antibody-Positive Encephalitis with Seizure and Unilateral Cortical Fluid-Attenuated Inversion Recovery-Hyperintense Lesions

Ki Hoon Kim  
Jinhyuk Cho  
Kyoo Ho Cho  
Ha Young Shin  
Seung Woo Kim

Department of Neurology,  
Yonsei University College of Medicine,  
Seoul, Korea

Dear Editor,

Anti-myelin oligodendrocyte glycoprotein (MOG) antibody-associated disease (MOGAD) is an autoimmune inflammatory demyelinating disease of the central nervous system (CNS) that usually presents as optic neuritis and myelitis in adults.<sup>1</sup> Cortical involvement in anti-MOG antibody-positive encephalitis with seizure was recently suggested to be one of the clinical features in MOGAD.<sup>2</sup> This distinct phenotype is referred to as FLAMES [unilateral cortical fluid-attenuated inversion recovery (FLAIR)-hyperintense lesions in anti-MOG-associated encephalitis with seizures], of which only a few cases have been reported.<sup>2</sup> Here we present two cases of FLAMES in the Korean population.

## Case 1

A 44-year-old male developed mild fever and aphasia 1 day before admission. On admission he had motor aphasia on the language function test. A cerebrospinal fluid (CSF) examination revealed a normal pressure of 14 cm H<sub>2</sub>O, total nucleated cell count of 43/μL, protein level of 58.2 mg/dL, and glucose level of 59 mg/dL. Cortical swelling of the left parietal lobe was noted on FLAIR images, with corresponding cortical enhancement on gadolinium-enhanced T1-weighted images (Fig. 1A and B). No signal change was evident in diffusion-weighted imaging (DWI) (Fig. 1C).

On day 2 the patient developed generalized tonic-clonic seizures accompanied by right-sided head version. Intravenous phenytoin was administered to control the seizures. Despite the antiviral and antiepileptic treatments, the patient experienced further sensory aphasia. Immune-mediated encephalitis was suspected, and intravenous steroid pulse therapy was initiated. Motor aphasia improved significantly and there was no further seizure attack. The 1-week follow-up brain magnetic resonance imaging (MRI) showed increased cortical swelling in the left parietal lobe (Fig. 1D). However, his clinical symptoms markedly improved.

After discharge, the patient was found to be seropositive for anti-MOG antibodies after assessment by a live-cell fluorescence-activated cell-sorting assay using serum. Autoimmune encephalitis-associated autoantibodies including N-methyl-D-aspartate-receptor (NMDAR) antibodies were negative in both serum and CSF. Prednisolone and antiepileptic medications were gradually tapered without further clinical attacks occurring. Brain MRI performed 5 months after symptom onset showed almost complete resolution of cortical swelling in the left parietal lobe (Fig. 1E). A follow-up neurologic examination demonstrated no focal neurologic deficit. Medications were discontinued and there were no additional attacks during a 12-month follow-up after the onset.

**Received** November 28, 2020  
**Revised** February 3, 2021  
**Accepted** February 3, 2021

## Correspondence

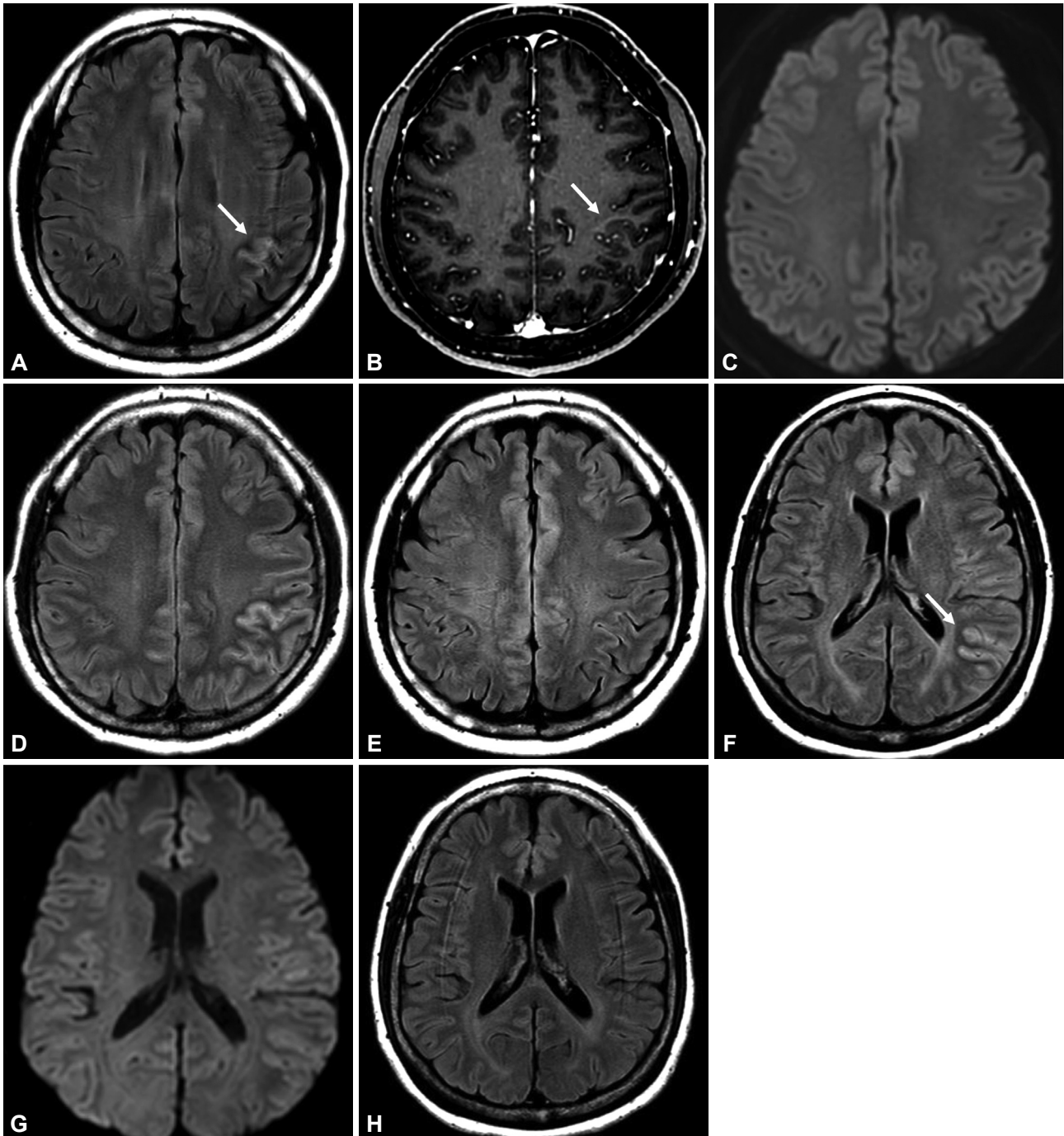
Seung Woo Kim, MD  
Department of Neurology,  
Yonsei University College of Medicine,  
50-1 Yonsei-ro, Seodaemun-gu,  
Seoul 03722, Korea  
**Tel** +82-2-2228-1600  
**Fax** +82-2-393-0705  
**E-mail** kswneuro@yuhs.ac

© This is an Open Access article distributed under the terms of the Creative Commons Attribution Non-Commercial License (<https://creativecommons.org/licenses/by-nc/4.0>) which permits unrestricted non-commercial use, distribution, and reproduction in any medium, provided the original work is properly cited.

**Case 2**

A 52-year-old female presented with acute-onset headache, nausea, and altered mental status. The initial FLAIR image

showed cortical swelling on the left parietotemporal lobe, but the signal changes on DWI were less significant than those in FLAIR imaging (Fig. 1F and G). Recurrent episodes



**Fig. 1.** Brain MRI revealed a typical pattern of unilateral cortical FLAIR-hyperintense lesions in anti-MOG-associated encephalitis with seizures (FLAMES). A–E: Brain MRI of case 1. The FLAIR image obtained at admission showed mild cortical swelling on the left parietal lobe with a T2-weighted hyperintensity (A, arrow). A gadolinium-enhanced T1-weighted image showed corresponding enhancement of the lesion but no definite leptomeningeal enhancement (B, arrow). No signal change was evident in DWI (C). The FLAIR-hyperintense lesion appeared more clearly in 1-week follow-up brain MRI (D) and was almost resolved on the MRI image obtained 5 months after symptom onset (E). F, G, and H: Brain MRI of case 2. The initial FLAIR image showed cortical swelling of the left parietotemporal lobe (F, arrow) without significant change in DWI (G). The lesion had completely disappeared in 8-month follow-up MRI (H). DWI: diffusion-weighted imaging, FLAIR: fluid-attenuated inversion recovery, MOG: myelin oligodendrocyte glycoprotein, MRI: magnetic resonance imaging.

of partial seizures occurred after admission, presenting as clonic movement of the right arm and right-sided head version. The seizures were controlled with antiepileptic medications. Two weeks after discharge the patient developed motor aphasia and clonic seizures of her right face and arm. A CSF examination showed a normal pressure, total nucleated cell count of 12/ $\mu$ L, and protein level of 26.9 mg/dL. Intravenous steroid pulse therapy improved her clinical symptoms without further seizure attacks. The patient was found to be seropositive for anti-MOG antibodies in a live-cell fluorescence-activated cell-sorting assay using serum. Autoimmune encephalitis-related autoantibodies were not detected. The cortical swelling of the left parietotemporal lobe was not evident on 8-month follow-up MRI (Fig. 1H). Long-term immunotherapy with azathioprine was used to prevent relapses, and no further clinical attacks occurred during a 18-month follow-up.

Cortical involvement is occasionally reported in patients with anti-MOG antibodies. However, a large proportion of the previous cases with anti-MOG antibody-positive encephalitis having a cortical lesions also displayed additional lesions in the juxtacortical or deep white matter. Cases with FLAMES that solely have unilateral cortical hyperintensity on FLAIR images without involvement of adjacent juxtacortical white matter have rarely been reported.<sup>2</sup> The association between anti-MOG antibody and cortical encephalitis with seizures has received considerable interest. Seizures and encephalitis are reported to be more common in MOGAD than in neuromyelitis optica spectrum disorder (NMOSD).<sup>3</sup> Additionally, a recent study suggested that cortical or juxtacortical lesions on brain MRI could help to distinguish MOGAD from NMOSD.<sup>4</sup> Thus, the pattern of cortical involvement, including FLAMES, can be a distinct phenotype of MOGAD.

A previous study demonstrated that anti-MOG antibody is mainly associated with demyelination in the CNS.<sup>5</sup> In acquired inflammatory CNS disorders with anti-MOG antibody, the level of myelin basic protein (MBP), which is a marker of myelin breakdown, was elevated in CSF without any evidence of accompanying astrocyte damage. This finding suggests that anti-MOG antibody directly causes inflammatory demyelination. However, the role of anti-MOG antibody in cortical encephalitis has been questionable. The MBP level was not elevated in a recent study that assessed three patients with cortical encephalitis who were positive for anti-MOG antibody.<sup>6</sup> Also, a direct relationship between cortical lesions and anti-MOG antibody was not observed in previous pathologic studies. Thus, anti-MOG antibody might not be directly pathogenic in cases with anti-MOG antibody-positive cortical encephalitis, and a coexisting autoimmune condition might be present. This is supported by several studies finding that anti-MOG antibody can coexist with anti-NMDAR antibodies.<sup>7,8</sup>

Further investigations are needed to find the link between anti-MOG antibody and cortical inflammation.

Early suspicion of FLAMES and testing for anti-MOG antibodies are important for making appropriate therapeutic decisions. As in the present cases, a previous study also showed the good response and prognosis of patients with unilateral cortical FLAMES treated with corticosteroids.<sup>2</sup> These observations indicate that serologic tests for anti-MOG antibodies should be considered in patients presenting with seizure, encephalitis, and unilateral cortical involvement.

### Author Contributions

Conceptualization: Ki Hoon Kim, Seung Woo Kim. Resources: Ki Hoon Kim, Kyoo Ho Cho, Seung Woo Kim. Supervision: Ha Young Shin, Seung Woo Kim. Visualization: Ki Hoon Kim, Jinhyuk Cho. Writing—original draft: Ki Hoon Kim. Writing—review & editing: all authors.

### ORCID iDs

Ki Hoon Kim	<a href="https://orcid.org/0000-0001-6428-061X">https://orcid.org/0000-0001-6428-061X</a>
Jinhyuk Cho	<a href="https://orcid.org/0000-0003-3356-1341">https://orcid.org/0000-0003-3356-1341</a>
Kyoo Ho Cho	<a href="https://orcid.org/0000-0003-2402-7198">https://orcid.org/0000-0003-2402-7198</a>
Ha Young Shin	<a href="https://orcid.org/0000-0002-4408-8265">https://orcid.org/0000-0002-4408-8265</a>
Seung Woo Kim	<a href="https://orcid.org/0000-0002-5621-0811">https://orcid.org/0000-0002-5621-0811</a>

### Conflicts of Interest

The authors have no potential conflicts of interest to disclose.

### Acknowledgements

None

## REFERENCES

- Ramanathan S, Mohammad S, Tantsis E, Nguyen TK, Merheb V, Fung VSC, et al. Clinical course, therapeutic responses and outcomes in relapsing MOG antibody-associated demyelination. *J Neurol Neurosurg Psychiatry* 2018;89:127-137.
- Budhram A, Mirian A, Le C, Hosseini-Moghaddam SM, Sharma M, Nicolle MW. Unilateral cortical FLAIR-hyperintense lesions in anti-MOG-associated encephalitis with seizures (FLAMES): characterization of a distinct clinico-radiographic syndrome. *J Neurol* 2019;266:2481-2487.
- Hamid SHM, Whittam D, Saviour M, Alorainy A, Mutch K, Linaker S, et al. Seizures and encephalitis in myelin oligodendrocyte glycoprotein IgG disease vs aquaporin 4 IgG disease. *JAMA Neurol* 2018;75:65-71.
- Salama S, Khan M, Shanchei A, Levy M, Izbudak I. MRI differences between MOG antibody disease and AQP4 NMOSD. *Mult Scler* 2020;26:1854-1865.
- Kaneko K, Sato DK, Nakashima I, Nishiyama S, Tanaka S, Marignier R, et al. Myelin injury without astrocytopathy in neuroinflammatory disorders with MOG antibodies. *J Neurol Neurosurg Psychiatry* 2016;87:1257-1259.
- Ogawa R, Nakashima I, Takahashi T, Kaneko K, Akaishi T, Takai Y, et al. MOG antibody-positive, benign, unilateral, cerebral cortical encephalitis with epilepsy. *Neurol Neuroimmunol Neuroinflamm* 2017;4:e322.
- Titulaer MJ, Höftberger R, Iizuka T, Leypoldt F, McCracken L, Cellucci T, et al. Overlapping demyelinating syndromes and anti-N-methyl-D-aspartate receptor encephalitis. *Ann Neurol* 2014;75:411-428.
- Wang L, Zhang Bao J, Zhou L, Zhang Y, Li H, Li Y, et al. Encephalitis is an important clinical component of myelin oligodendrocyte glycoprotein antibody associated demyelination: a single-center cohort study in Shanghai, China. *Eur J Neurol* 2019;26:168-174.