

desirable to confirm our data and possibly to enlighten the pathogenesis of this phenomenon.

### Acknowledgements

The patients in this manuscript have given written informed consent to the publication of their case details

### Conflict of interest

The authors have no financial obligations or conflict of interest to declare.

### Funding source

None.

C. Mazzatenta,<sup>1</sup> V. Piccolo,<sup>2,\*</sup> G. Pace,<sup>3</sup> I. Romano,<sup>4</sup>  
G. Argenziano,<sup>2</sup> A. Bassi<sup>1</sup>

<sup>1</sup>UO Dermatologia Lucca- Azienda USL Toscana Nordovest, Lucca, Italy,

<sup>2</sup>Dermatology Unit, University of Campania Luigi Vanvitelli, Naples, Italy,

<sup>3</sup>Pediatrician Self Employed, Treviso, Italy, <sup>4</sup>Dermatology Unit -  
Department of Medicine DIMED, University of Padua, Padova, Italy

\*Correspondence: V. Piccolo. E-mail: piccolo.vincenzo@gmail.com

### References

- 1 Corbeddu M, Diociaiuti A, Vinci MR *et al*. Transient cutaneous manifestations after administration of Pfizer-BioNTech COVID-19 Vaccine: an Italian single centre case series. *J Eur Acad Dermatol Venereol* 2021; **35**: e483–e485.
- 2 Ring J, Worm M, Wollenberg A *et al*. Risk of severe allergic reactions to COVID-19 vaccines among patients with allergic skin diseases – practical recommendations. A position statement of ETFAD with external experts. *J Eur Acad Dermatol Venereol* 2021; **35**: e362–e365.
- 3 Lee EJ, Cines DB, Gernsheimer T *et al*. Thrombocytopenia following Pfizer and Moderna SARS-CoV-2 vaccination. *Am J Hematol* 2021; **96**: 534–537.
- 4 Greinacher A, Thiele T, Warkentin TE, Weisser K, Kyrle PA, Eichinger S. Thrombotic thrombocytopenia after ChAdOx1 nCov-19 vaccination. *N Engl J Med* 2021; **384**: 2092–2101.
- 5 Piccolo V, Neri I, Manunza F, Mazzatenta C, Bassi A. Chilblain-like lesions during the COVID-19 pandemic: should we really worry? *Int J Dermatol* 2020; **59**: 1026–1027.
- 6 Piccolo V, Bassi A, Argenziano G *et al*. Dermoscopy of chilblain-like lesions during the COVID-19 outbreak: a multicenter study on 10 patients. *J Am Acad Dermatol* 2020; **83**: 1749–1751.
- 7 Piccolo V, Bassi A. Acral findings during the COVID-19 outbreak: Chilblain-like lesions should be preferred to acroischemic lesions. *J Am Acad Dermatol* 2020; **83**: e231.
- 8 Piccolo V, Bassi A, Russo T *et al*. Chilblain-like lesions and COVID-19: second wave, second outbreak. *J Eur Acad Dermatol Venereol* 2021; **35**: e316–e318.
- 9 Hubiche T, Cardot-Leccia N, Le Duff F *et al*. Clinical, laboratory, and interferon-alpha response characteristics of patients with chilblain-like lesions during the COVID-19 pandemic. *JAMA Dermatol* 2020; **157**: e204324.
- 10 Sekine T, Perez-Potti A, Rivera-Ballesteros O *et al*. Robust T cell immunity in convalescent individuals with asymptomatic or mild COVID-19. *Cell* 2020; **183**: 158–168.e14.

DOI: 10.1111/jdv.17340

## Recurrent injection-site reactions after incorrect subcutaneous administration of a COVID-19 vaccine

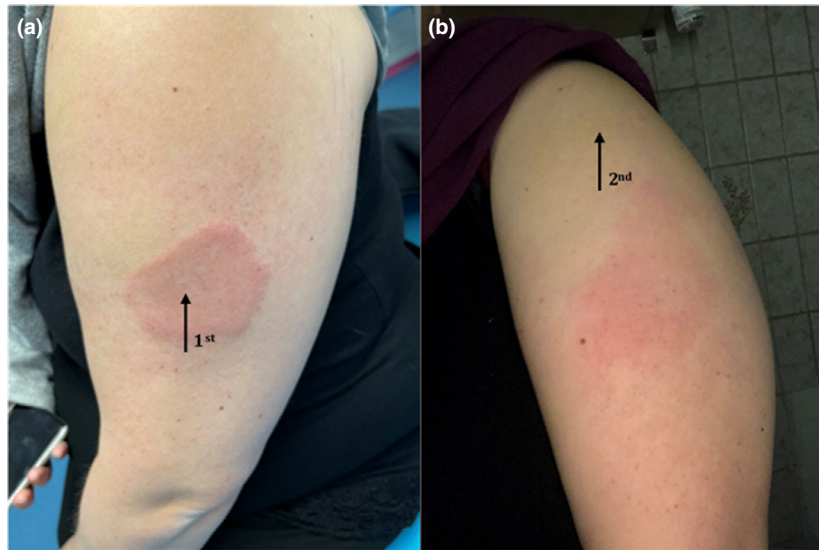
To the Editor,

Local reactions to SARS-CoV-2 vaccination are common and mainly occur within the first week, albeit also seen later.<sup>1</sup> Here, we address another aspect of cutaneous side effects to SARS-CoV-2 vaccination and draw attention to implications in clinical practice.

A 33-year-old woman with type-2 diabetes and obesity (BMI 43 kg/m<sup>2</sup>) was incorrectly given the first SARS-CoV-2 vaccination dose (BNT162b2, Pfizer-BioNTech) in the middle of her left upper arm. There were no complications to the procedure. One week later, she developed fever, myalgia, arthralgia and malaise and tested PCR-positive for SARS-CoV-2. Five days after symptom onset, she noticed an asymptomatic rash at the injection site (Fig. 1a). A lesional 3 mm skin punch biopsy showed perivascular lymphocyte infiltration in the dermis. Using ELISA,<sup>2</sup> serology testing performed on postvaccination day 13 and 35 initially demonstrated an IgG response towards the receptor-binding domain (RBD) of the spike protein but was negative for response against viral N-protein. At follow-up, antibodies against both RBD and viral N-protein were detected. The rash disappeared without treatment. Following correct re-vaccination in the left deltoid, the patient, within hours, developed skin erythema, intense soreness and warmth at the first injection site (Fig. 1b). The exanthema cleared spontaneously within a few days.

In this case, the first SARS-CoV-2 vaccine dose was accidentally injected subcutaneously due to incorrect anatomical location and high patient BMI. The significant skin reactions at the original injection site following SARS-CoV-2 infection and re-vaccination, respectively, are most likely caused by immunological reactivity towards vaccine antigens trapped in the subcutaneous tissue. As RBD is contained in the vaccine and N-protein is not, the patient's primary immune response was most likely raised against the vaccine, while both vaccine and virus antibodies were identified at follow-up.

Like most vaccines, SARS-CoV-2 vaccination should be administered intramuscularly to optimize immunogenicity and minimize local adverse reactions. Compared with muscle tissue, subcutaneous fat is less vascularized, which may harm the processing and presentation of antigens. In addition, superficial administration of vaccines more likely causes local side effects.<sup>3</sup> Obese individuals are at greater risk for severe SARS-CoV-2 infection and seem to generate poorer humoral vaccination responses compared with normal-weight persons.<sup>4</sup> Therefore, correct administration of SARS-CoV-2 vaccines is essential in the obese population. Deltoid fat pad thickness varies greatly,<sup>5</sup>



**Fig. 1** Local skin reactions, left upper arm (patient photographs). (a) Day 12 after first COVID-19 vaccination; day 5 after SARS-CoV-2 infection. (b) Day 48 after first BNT162b2 vaccination; few hours after COVID-19 re-vaccination; Arrows indicate the two injection sites.

and vaccination needles should be chosen individually to ensure intramuscular bioavailability.

#### Funding source

The analyses were supported by grants from the Carlsberg Foundation (CF20-0045) and the Novo Nordisk Foundation (NFF205A0063505).

#### Acknowledgement

The patient in this manuscript has given written informed consent to publication of her case details. We thank Dr. Lene Heise Garvey for intellectual input.

#### Conflict of interest

None.

M. Gyldenløve,<sup>1,\*</sup>  L. Skov,<sup>1</sup>  C.B. Hansen,<sup>2</sup> P. Garred<sup>2</sup>

<sup>1</sup>Department of Dermatology and Allergy, Herlev and Gentofte Hospital, University of Copenhagen, Hellerup, Denmark, <sup>2</sup>Laboratory of Molecular Medicine, Department of Clinical Immunology, Section 7631, Rigshospitalet, University of Copenhagen, Copenhagen, Denmark

\*Correspondence: M. Gyldenløve. E-mail: mette.gyldenloeve@regionh.dk

#### References

- 1 Blumenthal KG, Freeman EE, Saff RR, Robinson LB, Wolfson AR, Foreman RK. Delayed large local reactions to mRNA-1273 vaccine against SARS-CoV-2. *N Engl J Med* 2021; **384**: 1273–1277.
- 2 Hansen CB, Jarlhelt I, Pérez-Alós L *et al.* SARS-CoV-2 antibody responses are correlated to disease severity in COVID-19 convalescent individuals. *J Immunol* 2021; **206**: 109–117.

- 3 Zuckerman JN. The importance of injecting vaccines into muscle. *Br Med J* 2000; **321**: 1237–1238.
- 4 Pellini R, Venuti A, Pimpinelli F *et al.* Obesity may hamper SARS-CoV-2 vaccine immunogenicity; 2021. URL: <https://www.medrxiv.org/content/10.1101/2021.02.24.21251664v1> (last accessed: 9 March 2021). preprint.
- 5 Poland GA, Borrud A, Jacobson RM *et al.* Determination of deltoid fat pad thickness. Implications for needle length in adult immunization. *JAMA* 1997; **277**: 1709–1711.

DOI: 10.1111/jdv.17341

## Pityriasis rosea-like eruptions following vaccination with BNT162b2 mRNA COVID-19 Vaccine

Dear Editor,

COVID-19 has caused cutaneous symptoms in approximately 20% of patients, ranging from inflammatory and exanthematous eruptions to vasculopathic and vasculitic lesions.<sup>1</sup> Newly developed vaccines display high efficacy and low rates of adverse events. In the BNT162b2 (Pfizer, New York, NY, USA/BioNTech, Mainz, Germany) mRNA vaccine Phase III study, no participants reported cutaneous adverse events aside from injection site reactions.<sup>2</sup> We report two cases of cutaneous eruptions following BNT162b2 vaccination for COVID-19.