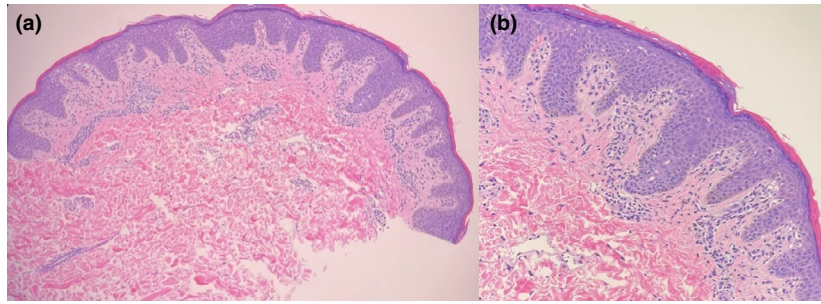

**Figure 2** Histopathological findings of pityriasis rosea-like eruption in patient 1. Parakeratosis with minimal acanthosis and spongiosis of the epidermis. Few scattered dyskeratotic keratinocytes are seen in the lower epidermis. The papillary dermis shows melanin incontinence, perivascular lymphocytic infiltrate and rare scattered extravasated red blood cells. (a) haematoxylin-eosin, original magnification  $\times 10$ . (b) haematoxylin-eosin, original magnification  $\times 20$ .

as PR-like eruptions may have peripheral eosinophilia, interface dermatitis and eosinophils on histopathology, with no evidence of HHV-6 and HHV-7 systemic reactivation.<sup>3</sup> Our cases had overlapping features of both PR and PR-like eruptions.

COVID-19 has been associated with cases of PR and PR-like eruptions following the acute infection.<sup>6,7</sup> Skin biopsies may demonstrate positivity for the SARS-CoV-2 virus spike protein on endothelial cells and lymphocytes suggesting a direct relationship between SARS-CoV-2 infection and PR.<sup>7</sup> SARS-CoV-2 may also trigger PR by reactivation of HHV-6 or HHV-7.<sup>5</sup> PR eruptions have developed following vaccination for influenza and H1N1<sup>8–10</sup> and may be secondary to reactivation of HHV-6 and HHV-7, which may be detected in skin biopsies via in situ hybridization and immunohistochemistry.<sup>9</sup> Another possible cause for PR in the setting of vaccination is a T-cell-mediated response triggered by molecular mimicry from a viral epitope.<sup>8</sup>


Given worldwide vaccination efforts against COVID-19 with mRNA vaccines, it is important for doctors and patients to recognize possible adverse events including PR. Further study is required to confirm the causative link, including direct examination of tissue and serological studies for evidence of HHV-6 and HHV-7 reactivation.

### Patient consent

The patients in this manuscript have given written informed consent to publication of their case details.

### Conflict of interest

The authors have no conflicts of interest to declare.

B.M. Cyrenne,\*  F. Al-Mohammed, J.G. DeKoven, R. Alhusayen

Division of Dermatology, Department of Medicine, University of Toronto, Toronto, ON, Canada

\*Correspondence: B.M. Cyrenne. E-mail: benoit.cyrenne@sickkids.ca

### References

- 1 Marzano AV, Cassano N, Genovese G, Moltrasio C, Vena GA. Cutaneous manifestations in patients with COVID-19: a preliminary review of an emerging issue. *Br J Dermatol* 2020; **183**: 431–442.
- 2 Polack FP, Thomas SJ, Kitchin N *et al*. Safety and efficacy of the BNT162b2 mRNA Covid-19 vaccine. *N Engl J Med* 2020; **383**: 2603–2615.
- 3 Drago F, Ciccarese G, Parodi A. Pityriasis rosea and pityriasis rosea-like eruptions: how to distinguish them? *JAAD Case Rep* 2018; **4**: 800–801.
- 4 Drago F, Ciccarese G, Javor S, Parodi A. Vaccine-induced pityriasis rosea and pityriasis rosea-like eruptions: a review of the literature. *J Eur Acad Dermatol Venereol* 2016; **30**: 544–545.
- 5 Drago F, Ciccarese G, Rebora A, Parodi A. Human herpesvirus-6, -7, and Epstein-Barr virus reactivation in pityriasis rosea during COVID-19. *J Med Virol* 2021; **93**: 1850–1851.
- 6 Johansen M, Chisolm SS, Aspey LD, Brahmabhatt M. Pityriasis rosea in otherwise asymptomatic confirmed COVID-19-positive patients: a report of 2 cases. *JAAD Case Rep* 2021; **7**: 93–94.
- 7 Welsh E, Cardenas-de la Garza JA, Cuellar-Barboza A, Franco-Marquez R, Arvizu-Rivera RI. SARS-CoV-2 spike protein positivity in pityriasis rosea-like and urticaria-like rashes of COVID-19. *Br J Dermatol* 2021: bjd.19833. <https://doi.org/10.1111/bjd.19833>
- 8 Chen JF, Chiang CP, Chen YF, Wang WM. Pityriasis rosea following influenza (H1N1) vaccination. *J Chinese Med Assoc* 2011; **74**: 280–282.
- 9 Papakostas D, Stavropoulos PG, Papafraqkaki D, Grigoraki E, Avgerinou G, Antoniou C. An Atypical case of pityriasis rosea gigantea after influenza vaccination. *Case Rep Dermatol* 2014; **6**: 119–123.
- 10 Ciccarese G, Parodi A, Drago F. SARS-CoV-2 as possible inducer of viral reactivations. *Dermatol Ther.* 2020; **33**: e13878.

DOI: 10.1111/jdv.17342

## Cutaneous adverse reactions after m-RNA COVID-19 vaccine: early reports from Northeast Italy

Dear Editor,

We report the first registered cases of cutaneous adverse reactions in Northeast Italy after the m-RNA COVID-19 vaccine

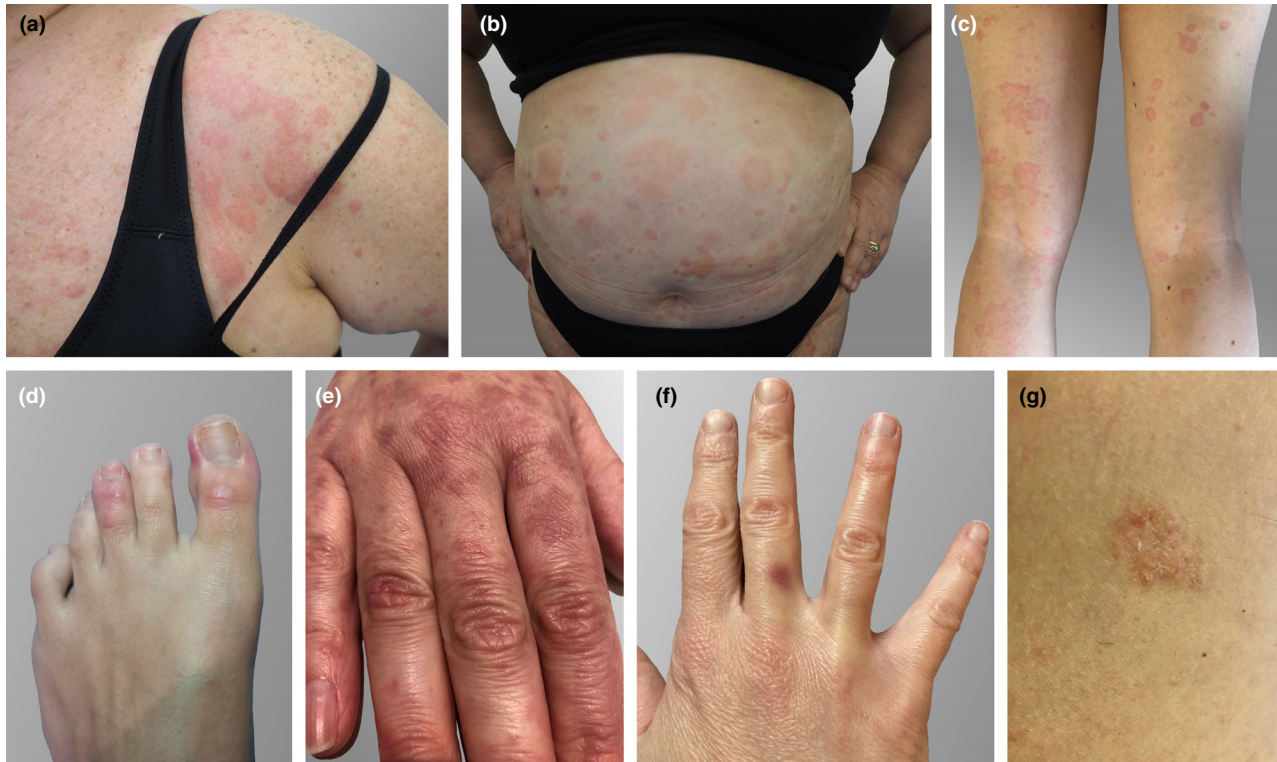
**Table 1** Summary of the total cutaneous adverse reactions reported to the Pharmacovigilance Service of Trieste (patients nr.1–44), including those evaluated at the Dermatology Clinic of Trieste (patients nr.38–44) and in other clinics of the Friuli Venezia-Giulia region, in Northeast Italy (patients 45–46)

Patient	Sex, Age	Cutaneous adverse reaction, timing of onset (if specified)	First or Second dose
1	F, 55	Urticarial rash limited to the upper limbs	First
2	F, 27	Urticarial rash limited to the neck and chest	Not reported
3	F, 64	Itchy erythema of the neck and hands	First
4	M, 38	Itching at the inoculation site	First
5	F, 49	Erythema at the inoculation site	First
6	F, 23	Urticarial rash limited to the chest	First
7	F, 49	Itchy erythema of the palms	First
8	F, 32	Itchy dermatitis of the face with fever	First
9	F, 34	Generalized itching	First
10	F, 37	Morbilliform eruption	Not reported
11	F, 43	Painful and itchy erythematous subcutaneous nodule at the inoculation site, 3 days after the dose	First
12	F, 50	Erythema of the chest and hands	First
13	F, 34	Urticarial rash limited to the upper limbs	First
14	F, 53	Painful hardening of the skin at the inoculation site with fever	Second
15	F, 65	Swelling of the face, 18 h after the dose	First
16	F, 51	Itchy arm with axillary lymphadenopathy, 24 h after the dose	First
17	F, 57	Painful swelling and erythema of the right eyelid, 7 days after the dose	First
18	F, 52	Generalized itching	First
19	F, 46	Burning wheal at the inoculation site	First
20	F, 63	Itchy wheal at the inoculation site	First
21	M, 28	Itchy swelling at the inoculation site	First
22	F, 56	Erythematous and itchy hardening of the skin at the inoculation site with fever	Second
23	F, 34	Herpes Zoster of the scalp	First
24	F, 46	Erythema at the inoculation site, 1 day after the dose	First
25	F, 46	Urticarial rash limited to the chest and lower limbs	First
26	F, 37	Cutaneous rash of the trunk	Second
27	F, 46	Generalized itching	First
28	F, 65	Nodule following itchy erythema at the inoculation site	First
29	F, 37	Painful wheal at the inoculation site	First
30	F, 55	Erythema at the inoculation site with fever	Second
31	F, 37	Swelling of the eyelids and face with mandibular lymphadenopathy	First
32	M, 70	Erythema at the inoculation site	First
33	F, 26	Painful swelling at the inoculation site	First
34	F, 39	Wheal at the inoculation site with axillary lymphadenopathy	First
35	F, 36	Itchy erythema of the abdomen, 1 week after the dose	First
36	F, 35	Swelling at the inoculation site with fever	Second
37	F, 48	Herpes Zoster	First
38	F, 54	Diffuse urticaria, 5 days after the dose	First
Fig. 1a–b			
39	F, 41	Erythematous macular rash of the hands, 8 days after the dose	First
Fig. 1e			
40	F, 44	Purplish macule on the third finger of one hand (fixed drug eruption), 10 days after the dose	Second
Fig. 1f			
41	F, 42	Pityriasis rosea-like rash on the thighs and abdomen, 4 days after the dose	Second
Fig. 1g			
42	M, 64	Pityriasis rosea-like rash on the neck, upper limbs, and trunk, 5 days after the dose	First
43	M, 18	Diffuse urticaria, 60 h after the dose	First
44	F, 55	Malar erythema, 12 h after the first dose; erythema of the face, trunk and thighs with fever, 3 days after the second dose	First and second

Table 1 Continued

Patient	Sex, Age	Cutaneous adverse reaction, timing of onset (if specified)	First or Second dose
45 Fig. 1c	F, 34	Diffuse urticaria; transient periorbital and perioral swelling, 4 days after the dose	First
46 Fig. 1d	F, 27	Chilblain-like rash on the first and third finger of one foot accompanied by urticarial rash, 4 days after the first dose; urticarial rash, 1 day after the second dose	First and second

Data were collected during the vaccination campaign with *Comirnaty*<sup>®</sup>-*BioNTech/Pfizer* (m-RNA COVID-19 vaccine) in January 2021.



**Figure 1** Cutaneous adverse reactions after administration of *Comirnaty*<sup>®</sup>-*BioNTech/Pfizer*, an m-RNA COVID-19 vaccine. (a–c) Diffuse urticaria. (d) Chilblain-like rash on the first and third finger of the left foot. (e) Erythematous macular rash of the hands. (f) Purplish macule on the third finger of the right hand, consistent with the diagnosis of fixed drug eruption. (g) Pityriasis rosea-like plaque (located on abdomen).

*Comirnaty*<sup>®</sup>-*BioNTech/Pfizer* (BioNTech Innovative Manufacturing Services GmbH, Idar-Oberstein, Germany).

During January 2021, in the public health jurisdiction of Trieste, a total of 19 485 individuals have been vaccinated: 13 266 (68.08%) first doses and 6219 (31.92%) completed cycles of two doses. In this population, 266 (1.36%) adverse reactions have been reported to the Pharmacovigilance Service. Notably, one or more cutaneous adverse effects were present in 44 people, accounting for 0.22% of all vaccinated individuals and 16.54% of communicated adverse effects. The reactions included both those at the injection site and more extensive manifestations (Table 1).

Nine subjects were evaluated in a Dermatology Clinic of the Friuli Venezia-Giulia region, in North-East Italy (Table 1, patients nr. 38–46).

Three of them presented with a diffuse urticaria (Fig. 1a–c), with onset of 60 h to 5 days after the first dose. For these three subjects, advise for not applying the second dose was given. Interestingly, one more patient developed an urticarial rash limited to the chest, together with chilblain-like manifestations on the first and third finger of one foot (Fig. 1d). The other cutaneous reactions observed in the remaining five patients were as follows: a malar erythema, an erythematous macular rash of the hands (Fig. 1e), a fixed drug eruption (FDE, Fig. 1f) and two cases resembling pityriasis rosea (Fig. 1g). Even if the first two reactions are not easy to interpret from a pathogenetic point of view, all five patients completed the two-dose vaccine cycle.

The outlined manifestations are quite heterogeneous and occur within a time frame of 60 h to 10 days after injection.

Their course was mostly mild and self-limiting. Only one patient with urticaria (nr. 45) required intravenous steroid treatment.

With regard to the urticarial manifestations, Polyethylene glycol-2000 (PEG-2000), an excipient of the vaccine, may play a role. In fact, PEG contained in several drugs can produce immediate hypersensitivity reactions<sup>1</sup> and cases of urticaria have been reported.<sup>2</sup> Moreover, PEG is investigated as possible responsible for the rare cases of anaphylaxis induced by *BioNTech/Pfizer* vaccine.<sup>3,4</sup>

The question of completing the vaccination cycle, after urticaria triggered by the first dose, remains open. We preferred to avoid exposure to the second dose, because it is currently unclear whether it should be regarded as a risk factor for anaphylaxis, although the timing of onset after exposure is not consistent with a type I Ig-E mediated reaction. Regarding the other observed reactions, it must be admitted that FDE represents a stereotypic reaction induced by drugs, but it is rarely induced by vaccines.<sup>5</sup> Conversely, pityriasis rosea has been reported after vaccinations or drug use.<sup>6,7</sup> It appears remarkable that urticarial, pityriasis rosea-like rashes or chilblain-like changes have been frequently reported during or after COVID-19.<sup>8–10</sup> For two patients (nr. 45–46), a swab and a serological test for SARS-CoV-2 resulted negative. For the remaining cases, we cannot exclude with certainty a contagion with SARS-CoV-2 shortly before or after the vaccine injection.

In conclusion, cutaneous adverse reactions triggered by *Comirnaty*®-*BioNTech/Pfizer* are seldom but appear similar to those reported during SARS-CoV-2 infections. Limitations of this study include the use of self-reported data. However, the reporting subjects were largely healthcare workers, and therefore, the reliability of data can be considered high. In addition, all the reports show a temporal relation with the vaccine, but this does not allow us to conclude that a true causal link exists.

The exact biological mechanisms underlying cutaneous effects after this m-RNA COVID-19 vaccine have still to be elucidated, and further studies based on larger cohorts are needed to better understand them.

### Acknowledgements

The persons in this manuscript have given written informed consent to publication of their case details.

### Funding sources

None.

### Conflict of interest

The authors have no conflict of interest.

E. Farinazzo,<sup>1</sup> G. Ponis,<sup>2</sup> E. Zelin,<sup>1,\*</sup> E. Errichetti,<sup>3</sup> G. Stinco,<sup>3</sup> C. Pinzani,<sup>4</sup> A. Gambelli,<sup>5</sup> N. De Manzini,<sup>6</sup> L. Toffoli,<sup>1</sup> A. Moret,<sup>1</sup> M. Agozzino,<sup>1</sup> C. Conforti,<sup>1</sup> N. Di Meo,<sup>1</sup> P. Schincariol,<sup>2</sup> I. Zalaudek<sup>1</sup>

<sup>1</sup>Dermatology Clinic, Maggiore Hospital, University of Trieste, Trieste, Italy,

<sup>2</sup>Hospital Pharmacy Unit, Cattinara Hospital, Trieste, Italy, <sup>3</sup>Department of Medical Area, Institute of Dermatology, University of Udine, Udine, Italy,

<sup>4</sup>Dermatology and Venereology, Private Practice, Udine, Italy, <sup>5</sup>Division of Molecular Oncology, Centro di Riferimento Oncologico di Aviano (CRO)

IRCCS, National Cancer Institute, Aviano, Italy, <sup>6</sup>UCO Chirurgia Generale, Cattinara Hospital, University of Trieste, Trieste, Italy

\*Correspondence: E. Zelin. E-mail: enrico.zelin@gmail.com

### References

- Cox F, Khalib K, Conlon N. PEG that reaction: a case series of allergy to polyethylene glycol. *J Clin Pharmacol* 2021; **61**: 832–835.
- Gökay SS, Çelik T, Sari MY *et al*. Urticaria as a rare side effect of polyethylene glycol-3350 in a child: case report. *Acta Clin Croat* 2018; **57**: 187–189.
- Garvey LH, Nasser S. Anaphylaxis to the first COVID-19 vaccine: is polyethylene glycol (PEG) the culprit? *Br J Anaesth* 2021; **126**: e106–e108.
- Blumenthal KG, Robinson LB, Camargo CA *et al*. Acute allergic reactions to mRNA COVID-19 vaccines. *JAMA* 2021; **325**: 1562–1565.
- Sako EY, Rubin A, Young LC. Localized bullous fixed drug eruption following yellow fever vaccine. *J Am Acad Dermatol* 2014; **70**: e113–e114.
- Drago F, Ciccarese G, Parodi A. Pityriasis rosea and pityriasis rosea-like eruptions: how to distinguish them? *JAAD Case Rep* 2018; **4**: 800–801.
- Atzori L, Pinna AL, Ferrel C, Aste N. Pityriasis rosea-like adverse reaction: review of the literature and experience of an Italian drug-surveillance center. *Dermatol Online J* 2006; **12**: 1.
- Zhao Q, Fang X, Pang Z *et al*. COVID-19 and cutaneous manifestations: a systematic review. *J Eur Acad Dermatol Venereol* 2020; **34**: 2505–2510.
- Visconti A, Bataille V, Rossi N *et al*. Diagnostic value of cutaneous manifestation of SARS-CoV-2 infection. *Br J Dermatol* 2021. **184**: 880–887.
- de Masson A, Bouaziz J-D, Sulimovic L *et al*. Chilblains is a common cutaneous finding during the COVID-19 pandemic: A retrospective nationwide study from France. *J Am Acad Dermatol* 2020; **83**: 667–670.

DOI: 10.1111/jdv.17343

## Heterogeneous red–white discoloration of the nail bed and distal onycholysis in a patient with COVID-19

### Editor

The severe acute respiratory syndrome, coronavirus 2 (SARS-CoV-2) disease (COVID-19) that emerged in China, was declared a pandemic on 11 March 2020, by the World Health Organization.<sup>1</sup> Numerous cutaneous symptoms such as pseudopernio, maculopapular, vesicular and urticarial rashes, livedoid or purpura-like vascular rashes, erythema multiforme-like rashes have been reported in COVID-19.<sup>2</sup> There are also case presentations mentioning nail symptoms related to COVID-19. Reports include half-moon-shaped transversal red bands;<sup>3</sup> Beau lines;<sup>4</sup> leukonychia in addition to Beau lines;<sup>5</sup> and red half-moon nail