



# Herniated discs: when is surgery necessary?

Wai Weng Yoon<sup>1,2</sup>  
Jonathan Koch<sup>2</sup>

- In all levels of disc herniations the absolute surgical indications include deteriorating neurological deficits with myelopathy or cauda equina syndrome. However, this review summarized the relative indications for surgery in each level.
- In cervical disc herniation (CDH), the indications for surgery consist of six months of persisting symptoms, not responding to conservative treatment. However, high-quality studies are lacking, and a randomized controlled trial is now underway to clarify the indications.
- In thoracic disc herniation (TDH), the indications for surgery comprise failure of conservative measures and/or worsening neurological symptoms. Moreover, giant calcified thoracic disc herniations or myelopathy signs on magnetic resonance imaging, even in the absence of neurological symptoms, may benefit from surgical treatment as a preventive measure.
- In lumbar disc herniation (LDH), the indications for surgery include imaging confirmation of LDH, consistent with clinical findings, and failure to improve after six weeks of conservative care.

**Keywords:** disc herniation; evidence; surgical indications

Cite this article: *EFORT Open Rev* 2021;6:526-530.  
DOI: 10.1302/2058-5241.6.210020

## Introduction

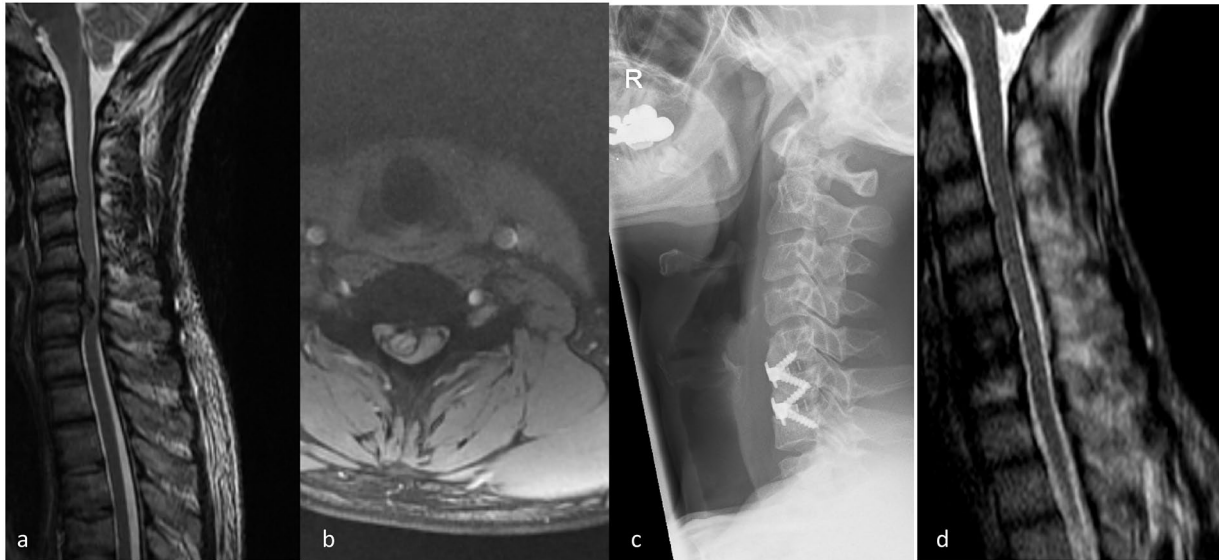
Disc herniation is a localized displacement of disc material beyond the normal margins of the intervertebral disc space. The pain pathway originates in impingement of the nerve root by the herniated disc, which may in turn lead to nerve damage both by mechanical and chemical pathways. Mechanically, compression of the nerve likely leads to localized ischemia and nerve damage. Equally important, however, is the chemical cascade triggered by the nucleus pulposus on the nerve. A pro-inflammatory cascade mediated by tumour necrosis factor-alpha (TNF- $\alpha$ ), interleukin factor-6 (IL-6), and matrix metalloproteinases (MMPs) leads to further sensitization and increased pain in the area.<sup>1,2</sup>

In this lecture we will look at herniated discs in the cervical, thoracic and lumbar spine as each has varying thresholds for intervention.

## Cervical disc herniation

Cervical disc herniation (CDH) is a common source of cervical radiculopathy, with an annual incidence of 18.6 per 100,000, and peak presentation in the sixth decade of life.<sup>3</sup> The aetiology of CDH is multi-factorial and the proposed risk factors include male gender, cigarette smoking, heavy lifting, and occupations involving operating vibrating equipment.<sup>4</sup> With regards to pathoanatomy, the herniated disc may impinge on the exiting nerve root intraforaminally as it traverses the neuroforamen, or, more commonly, posterolaterally at its take-off from the spinal cord.<sup>5</sup> Most patients with symptomatic CDH and radiculopathy report severe neck and arm pain. The arm pain typically follows a myotomal pattern, whereas the sensory symptoms (e.g., burning, tingling) follow a dermatomal distribution. These radicular symptoms may also be associated with reflex changes and motor weakness of the upper extremity.<sup>6</sup> Epidemiologic studies have shown that the C7 root (C6–7 herniation) is the most commonly affected, followed by the C6 (C5–6 herniation) and C8 (C7–T1 herniation) nerve roots.

The natural history of CDH with radiculopathy is generally considered favourable; however, high-quality studies are lacking. A classic study by Lees and Turner featured a long-term follow-up (2–19 years) of 51 patients with radiculopathy: 45% of the patients had only a single episode of pain without recurrence, 30% had mild symptoms, and only 25% had persistent or worsening symptoms.<sup>7</sup> No radiculopathic patient progressed to myelopathy in this series.<sup>7</sup> An epidemiologic study by Radhakrishnan et al showed similar findings at four-year follow-up, where nearly 90% of patients with cervical radiculopathy were either asymptomatic or only mildly symptomatic.<sup>3</sup> A recent systematic review found that substantial improvements in symptoms appear within four to six months, with time to complete recovery spanning 24 to 36 months in most patients.<sup>8</sup> In the long term, a small proportion of



**Fig. 1** A 38-year-old semi-professional cyclist with nine-month history of progressive arm weakness and unsteady gait. (a, b) Magnetic resonance imaging (MRI) demonstrated a herniated disc at C5/6 and C6/7 levels. (c) The patient had a C5/6 and C6/7 anterior cervical discectomy and fusion. (d) Postoperative MRI at 12 months.

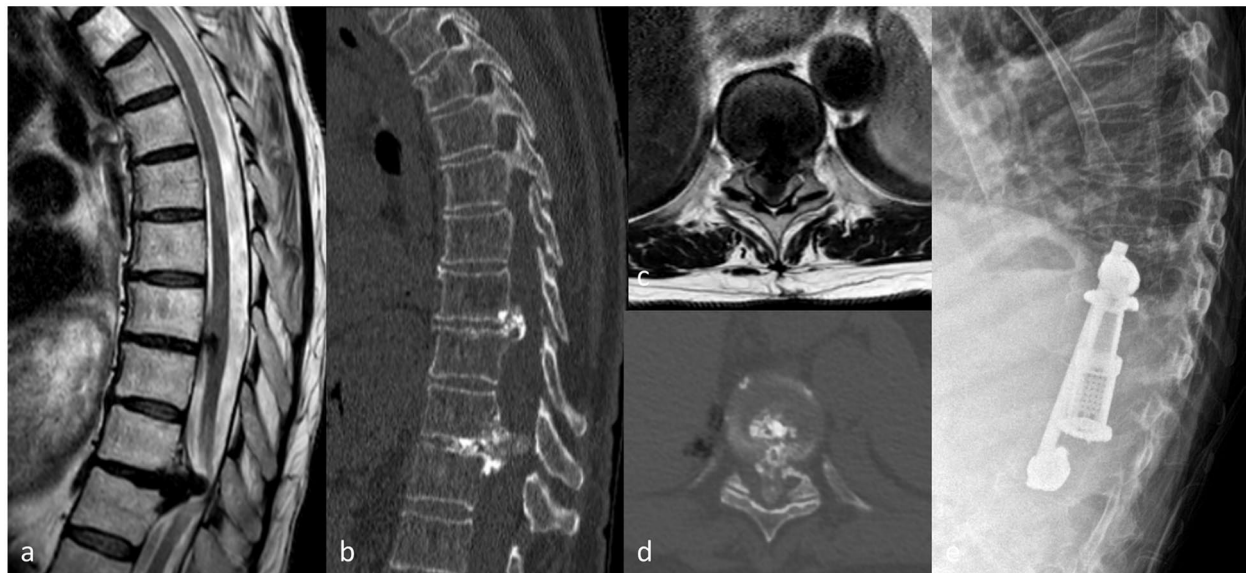
patients appeared to have residual impairments, such as pain and activity limitations; however, none of the patients had progressive neurologic deficits or developed myelopathy.<sup>8</sup> This systematic review also showed that workers' compensations claims were correlated with more invasive treatment and a poorer prognosis.<sup>8</sup>

Non-surgical treatment is the initial treatment of choice in most CDH patients with radiculopathy. It consists of a number of different modalities including immobilization, physical therapy, manipulation, traction, medication, and cervical steroid injection.<sup>5</sup> Good to excellent outcomes were reported in up to 90% of patients with non-operative management of cervical radiculopathy.<sup>9</sup> There are no clearly recognized indications for surgery in patients with CDH with radiculopathy.<sup>5</sup> Concerning signs or symptoms that might merit early surgical intervention include progressive neurologic deficits or signs of myelopathy (Fig. 1).<sup>10</sup> A trial of non-operative management is usually attempted in the absence of these signs. However, the length of non-operative management that has to be attempted is unclear. Wong et al noted in their systematic review that most patients experienced substantial improvement within 4–6 months.<sup>8</sup> A recent study by Burneikiene et al has shown that a longer duration of symptoms preoperatively corresponds to worse outcomes after surgery, with significantly better arm pain scores in patients who underwent decompression within six months of symptom onset, and the authors therefore recommended six months as the cut-off for non-operative management.<sup>11</sup> This finding has been supported by other authors.<sup>12</sup> A randomized controlled trial (RCT) is now underway to clarify indications for surgical treatment.<sup>13</sup>

### Thoracic disc herniation

Symptomatic thoracic disc herniation (TDH) is a rare condition affecting 1 in 1,000 to 1 in 1,000,000 people in the general population, and makes up 0.1% to 3% of all spinal disc herniation. Asymptomatic TDH is more frequent and is discovered incidentally in 11% to 37% of imaging studies.<sup>14</sup> The peak emergence of TDH is in adults between 30 and 50 years old, with equal distribution between genders.<sup>15,16</sup> The aetiology is multi-factorial, and recognized risk factors are history of trauma, Scheuermann's disease, cigarette smoking, and being a sedentary worker.<sup>17</sup> In 75% of cases, the TDH is located below the T7–T8 disc, with the T11–T12 disc being the most vulnerable, and only 4% of cases are located above T3–T4.<sup>18</sup> The distinctiveness of TDH is the high frequency (42%) of calcification or even ossification of the disc.<sup>15</sup> The TDH can also be very large in volume and is labelled as giant when it occupies more than 40% of the medullary canal on computed tomography (CT) or magnetic resonance imaging (MRI).<sup>16</sup> These giant herniated discs are predominantly calcified (76–95% of all giant herniated thoracic discs), and due to their voluminous and calcified nature, the risk of intradural extension is 15% to 70%.<sup>18</sup> The thoracic spinal cord is particularly vulnerable owing to the thoracic kyphosis pushing the cord against the disc, the denticulate ligament reducing the cord mobility, the large thoracic cord diameter in relation to the smaller spinal canal diameter, and the poorly vascularized area in the cord (watershed zone).<sup>14</sup>

The onset of TDH is usually gradual, and the main clinical symptom is thoracic back pain which is present in 92% of cases. Radicular symptoms (intercostal or abdominal



**Fig. 2** A 74-year-old female patient presented with five days worsening back pain and left leg numbness. Feels pins and needles over perianal area and perineal area with one episode of urinary retention. (a–d) Magnetic resonance imaging demonstrated a giant herniated disc at T9/10 level and a computerized tomography scan confirmed the characteristic calcification. (e) The patient had T9/T10 corpectomy and discectomy with anterior reconstruction (cage + lateral plate fixation).

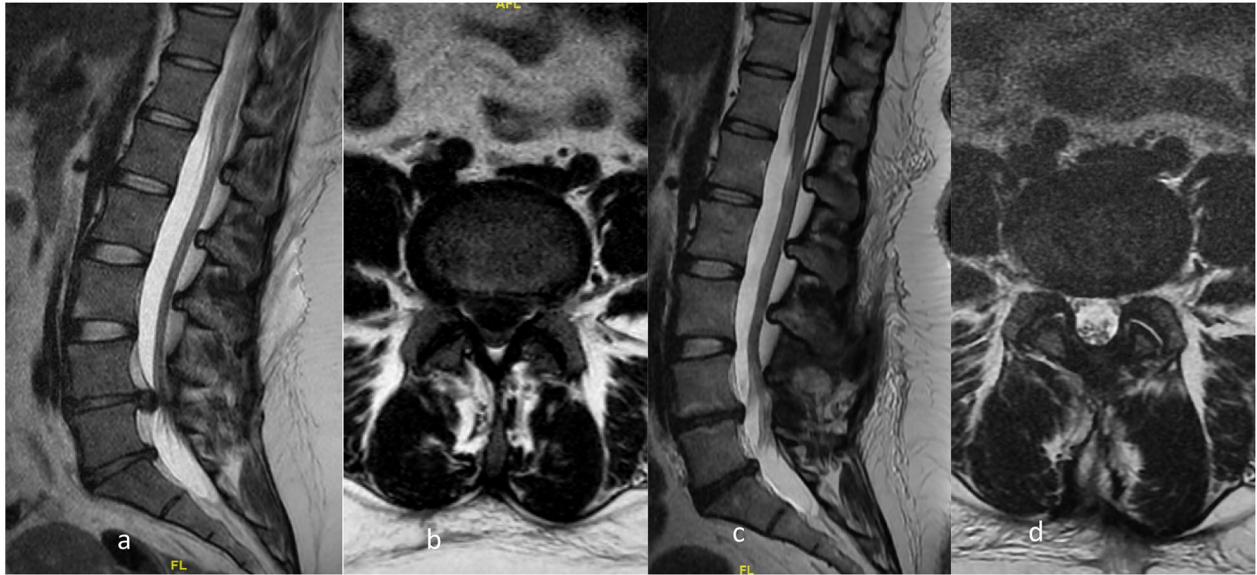radicular pain) may also be present, followed by progressive myelopathy with sensory disturbance, motor deficit in the lower limbs, ataxia, and bladder symptoms.<sup>15</sup> Calcified TDH presents in 70% to 95% of the cases with myelopathy signs. Due to the slow progression and atypical clinical signs, the mean period from onset of first symptoms to diagnosis of TDH is 15 months. However, in 11% of cases onset can be sudden, post-traumatic, with rapid onset of neurological deficits (paraparesis, Brown-Sequard syndrome, vesical–sphincter disorders, and paraplegia).<sup>15</sup>

The majority of patients will respond favourably to non-operative treatment and observation, especially in cases of isolated back pain or isolated radicular pain due to intercostal nerve root entrapment. Surgical management for TDH is indicated if patients fail conservative measures (persistent axial back pain or intractable radiculopathy) and/or if they present with worsening neurological symptoms.<sup>18</sup> Most surgeons recommend surgical treatment for giant herniated thoracic discs (HTDs) and giant calcified HTDs because those HTDs frequently lead to the development of myelopathy (up to 97%).<sup>19</sup> However, some also consider operative management in certain cases where patients with myelopathy signs are evident on MRI, even in the absence of neurological symptoms. These patients may benefit from surgical treatment before symptoms appear or, worse, become irreversible (Fig. 2).<sup>18</sup> Prognostic factors for poor surgical outcomes in patients with myelopathy include longer preoperative duration of symptoms, worse preoperative symptoms, and ossification of posterior ligament or ligamentum flavum.<sup>18</sup>

## Lumbar disc herniation

Lumbar disc herniation (LDH) is the most common cause of sciatica, affecting 1% to 5% of the population annually.<sup>20</sup> The primary signs and symptoms of lumbar disc herniation include radicular pain, sensory abnormalities, and weakness in the distribution of one or more lumbosacral nerve roots.<sup>21</sup> Focal paresis, restricted trunk flexion, and increases in leg pain when sitting or with straining, coughing, and sneezing are also indicative.<sup>21</sup> Absolute indications for an urgent surgical treatment are progressive and significant lower limb weakness or cauda equina syndrome (Fig. 3). However, in the absence of these symptoms, the first-line treatment for LDH is non-surgical and may consist of rest, pharmacologic therapy, physical therapy, and transforaminal or epidural steroid injections. In a placebo-controlled double-blinded trial, Weber et al found a significant reduction in pain within four weeks in 70% of patients with sciatica.<sup>22</sup>

For symptoms that are resistant to initial conservative treatments, continued conservative care or lumbar discectomy to remove the offending herniated disc material may be considered, and the question of which treatment is superior has sparked a major debate. In the last three decades, several RCTs and prospective cohort studies have shown that discectomy provides faster and/or greater pain relief, recovery from disability, and patient satisfaction compared to non-surgical care. Early evidence came from a large (507 patients), multi-centre prospective cohort study called the Maine Lumbar Spine Study (MLSS). At the one-year



**Fig. 3** A 28-year-old female patient presented with acute onset back pain and bilateral leg numbness. Altered sensation over perianal area and perineal area with urinary retention. (a, b) Magnetic resonance imaging (MRI) demonstrated a herniated disc at L4/5 level. (c, d) the patient had L4/5 discectomy, and this is the postoperative MRI at 12 months.

follow-up, patients treated with discectomy reported greater improvement in back and leg pain, functional status, and overall satisfaction, compared to non-surgical care.<sup>23</sup> Long-term follow-up analyses in the MLSS reported that these greater improvements among discectomy-treated patients persisted over five years for leg pain, back pain, function, and satisfaction,<sup>24</sup> and over 8 to 10 years for leg pain and function.<sup>25</sup> Another high-impact study is the Spine Patient Outcomes Research Trial (SPORT). It is a large, multi-centre RCT and an observational cohort study, comparing discectomy versus non-surgical care in patients with lumbar radiculopathy secondary to LDH. The RCT did not detect significant differences in pain, function, or disability between the treatment groups at the two-year follow-up.<sup>26</sup> However, this was later explained by a high crossover rate between the treatment groups in the RCT and the adjusted analysis showed in the discectomy group significantly better improvements in pain and function scores, sciatica scores, as well as higher patient satisfaction, compared to non-surgical care. The observational cohort showed that patients in the discectomy group had significantly greater improvements in primary outcomes (bodily pain, physical function) and secondary outcomes (bothersome sciatica, satisfaction, and self-rated improvement) over the two years of follow-up.<sup>27</sup> Longer term follow-up studies of the combined SPORT cohorts confirmed that the benefits of discectomy persisted for eight years.<sup>28</sup> A 2019 systematic review and meta-analysis examined 11 studies (3232 patients) comparing discectomy versus non-surgical care. Discectomy was found to be more effective than non-surgical care in significantly reducing leg pain, and back pain.<sup>29</sup>

In line with the above evidence, the International Society for the Advancement of Spine Surgery recently released a policy regarding the treatment of patients with symptomatic LDH who fail to improve with non-surgical care. The clinical indications for surgical treatment may be: patients with clinical signs and symptoms associated with LDH, with imaging confirmation of LDH consistent with clinical findings, and failure to improve after six weeks of conservative care.<sup>30</sup> A recent systematic review assessed the preoperative predictors associated with positive or negative postoperative clinical outcome. It found that more severe leg pain, better mental health status, shorter duration of symptoms, and younger age are associated with positive outcome, and negative outcomes are associated with intact annulus fibrosus, longer duration of sick leave, workers' compensation, and greater severity of baseline symptoms.<sup>31</sup> Surprisingly, several preoperative factors including motor deficit, side and level of herniation, presence of Type 1 Modic changes and degeneration on MRI had non-significant associations with postoperative outcome.<sup>31</sup>

#### AUTHOR INFORMATION

<sup>1</sup>Spinal Surgery Unit, University Hospitals of Leicester NHS Trust, Leicester, UK.

<sup>2</sup>Centre for Spinal Surgery, Queens Medical Centre, Nottingham University NHS Trust, Nottingham, UK.

Correspondence should be sent to: Wai Weng Yoon, University Hospitals of Leicester NHS Trust – Spinal Surgery, Leicester Royal Infirmary, Infirmary Square, Leicester, LE1 5WW, UK.

Email: [wwyoon@mac.com](mailto:wwyoon@mac.com)

**ICMJE CONFLICT OF INTEREST STATEMENT**

The authors declare no conflict of interest relevant to this work.

**FUNDING STATEMENT**

No benefits in any form have been received or will be received from a commercial party related directly or indirectly to the subject of this article.

**OPEN ACCESS**

© 2021 The author(s)

This article is distributed under the terms of the Creative Commons Attribution-Non Commercial 4.0 International (CC BY-NC 4.0) licence (<https://creativecommons.org/licenses/by-nc/4.0/>) which permits non-commercial use, reproduction and distribution of the work without further permission provided the original work is attributed.

**REFERENCES**

- Kang JD, Stefanovic-Racic M, McIntyre LA, Georgescu HI, Evans CH.** Toward a biochemical understanding of human intervertebral disc degeneration and herniation: contributions of nitric oxide, interleukins, prostaglandin E<sub>2</sub>, and matrix metalloproteinases. *Spine (Phila Pa 1976)* 1997;22:1065–1073.
- Van Boxem K, Huntoon M, Van Zundert J, Patijn J, van Kleef M, Joosten EA.** Pulsed radiofrequency: a review of the basic science as applied to the pathophysiology of radicular pain: a call for clinical translation. *Reg Anesth Pain Med* 2014;39:149–159.
- Radhakrishnan K, Litchy WJ, O'Fallon WM, Kurland LT.** Epidemiology of cervical radiculopathy: a population-based study from Rochester, Minnesota, 1976 through 1990. *Brain* 1994;117:325–335.
- Kelsey JL, Githens PB, Walter SD, et al.** An epidemiological study of acute prolapsed cervical intervertebral disc. *J Bone Joint Surg Am* 1984;66:907–914.
- Yoon T, Riew KD.** Cervical radiculopathy. *J Am Acad Orthop Surg* 2007;15:486–494.
- Carette S, Fehlings MG.** Clinical practice: cervical radiculopathy. *N Engl J Med* 2005;353:392–399.
- Lees F, Turner JW.** Natural history and prognosis of cervical spondylosis. *Br Med J* 1963;2:1607–1610.
- Wong JJ, Fccs C, Pierre C, et al.** The course and prognostic factors of symptomatic cervical disc herniation with radiculopathy: a systematic review of the literature. *Spine J* 2020;14:1781–1789.
- Saal JS, Saal JA, Yurth EF.** Nonoperative management of herniated cervical intervertebral disc with radiculopathy. *Spine (Phila Pa 1976)* 1996;21:1877–1883.
- Levine MJ, Albert TJ, Smith MD.** Cervical radiculopathy: diagnosis and nonoperative management. *J Am Acad Orthop Surg* 1996;4:305–316.
- Burneikiene S, Nelson EL, Mason A, Rajpal S, Villavicencio AT.** The duration of symptoms and clinical outcomes in patients undergoing anterior cervical discectomy and fusion for degenerative disc disease and radiculopathy. *Spine J* 2015;15:427–432.
- Engquist M, Löfgren H, Öberg B, et al.** Factors affecting the outcome of surgical versus nonsurgical treatment of cervical radiculopathy: a randomized, controlled study. *Spine (Phila Pa 1976)* 2015;40:1553–1563.
- van Geest S, Kuijper B, Oterdoom M, et al.** CASINO: surgical or nonsurgical treatment for cervical radiculopathy, a randomised controlled trial. *BMC Musculoskelet Disord* 2014;15:129.
- Court C, Mansour E, Bouthors C.** Thoracic disc herniation: surgical treatment. *Orthop Traumatol Surg Res* 2018;104:S31–S40.
- Quint U, Bordon G, Preissl I, Sanner C, Rosenthal D.** Thoracoscopic treatment for single level symptomatic thoracic disc herniation: a prospective followed cohort study in a group of 167 consecutive cases. *Eur Spine J* 2012;21:637–645.
- Hott JS, Feiz-Erfan I, Kenny K, Dickman CA.** Surgical management of giant herniated thoracic discs: analysis of 20 cases. *J Neurosurg Spine* 2005;3:191–197.
- Baranowska J, Baranowska A, Baranowski P, Rybarczyk M.** Surgical treatment of thoracic disc herniation. *Pol Merkur Lekarski* 2020;49:267–270.
- Bouthors C, Benzakour A, Court C.** Surgical treatment of thoracic disc herniation: an overview. *Int Orthop* 2019;43:807–816.
- Gong M, Liu G, Guan Q, Li L, Xing F, Xiang Z.** Literature review surgery for giant calcified herniated thoracic discs: a systematic review. *World Neurosurg* 2021;118:109–117.
- Frymoyer JW.** Back pain and sciatica. *N Engl J Med* 1988;318:291–300.
- Vucetic N, Svensson O.** Physical signs in lumbar disc hernia. *Clin Orthop Relat Res* 1996;333:192–201.
- Weber H, Holme I, Amlie E.** The natural course of acute sciatica with nerve root symptoms in a double-blind placebo-controlled trial evaluating the effect of piroxicam. *Spine (Phila Pa 1976)* 1993;18:1433–1438.
- Atlas SJ, Deyo RA, Keller RB, et al.** The Maine Lumbar Spine Study, Part II: 1-year outcomes of surgical and nonsurgical management of sciatica. *Spine (Phila Pa 1976)* 1996;21:1777–1786.
- Atlas SJ, Keller RB, Chang Y, Deyo RA, Singer DE.** Surgical and nonsurgical management of sciatica secondary to a lumbar disc herniation: five-year outcomes from the Maine Lumbar Spine Study. *Spine (Phila Pa 1976)* 2001;26:1179–1187.
- Atlas SJ, Keller RB, Wu YA, Deyo RA, Singer DE.** Long-term outcomes of surgical and nonsurgical management of lumbar spinal stenosis: 8 to 10 year results from the Maine Lumbar Spine Study. *Spine (Phila Pa 1976)* 2005;30:936–943.
- Weinstein JN, Tosteson TD, Lurie JD, et al.** Surgical vs nonoperative treatment for lumbar disk herniation: the Spine Patient Outcomes Research Trial (SPORT): a randomized trial. *JAMA* 2006;296:2441–2450.
- Weinstein JN, Lurie JD, Tosteson TD, et al.** Surgical vs nonoperative treatment for lumbar disk herniation: the Spine Patient Outcomes Research Trial (SPORT) observational cohort. *JAMA* 2006;296:2451–2459.
- Lurie JD, Tosteson TD, Tosteson ANA, et al.** Surgical versus nonoperative treatment for lumbar disc herniation: eight-year results for the spine patient outcomes research trial. *Spine (Phila Pa 1976)* 2014;39:3–16.
- Arts MP, Kuršumović A, Miller LE, et al.** Comparison of treatments for lumbar disc herniation: systematic review with network meta-analysis. *Med (United States)* 2019;98:1–9.
- Lorio M, Kim C, Araghi A, Inzana J, Yue JJ.** International Society for the Advancement of Spine Surgery Policy 2019: surgical treatment of lumbar disc herniation with radiculopathy. *Int J Spine Surg* 2020;14:1–17.
- Wilson CA, Roffey DM, Chow D, Alkherayf F, Wai EK.** A systematic review of preoperative predictors for postoperative clinical outcomes following lumbar discectomy. *Spine J* 2016;16:1413–1422.