



The ratio of the posterior atlanto-occipital interval (PAOI): a novel radiographic ratio method evaluating the risk of cervical spondylotic myelopathy—a case-control study

Mingsheng Tan^{1,2#}, Jipeng Song^{1,2#}, Yanlei Wang^{2,3}, Long Gong^{1,2}, Yan Sun^{2,3}, Ping Yi², Feng Yang², Xiangsheng Tang², Qingying Hao², Wenhao Li^{2,3}

¹Graduate School of Peking Union Medical College, Beijing, China; ²Orthopedics Department, China-Japan Friendship Hospital, Beijing, China;

³Graduate School of Beijing University of Chinese Medicine, Beijing, China

#These authors contributed equally to this work.

Correspondence to: Mingsheng Tan. Orthopedics Department, China-Japan Friendship Hospital, 2 Yinghuayuan Dongjie, Beijing 100029, China. Email: zrtanms@sina.com.

Background: Our study aims to introduce a dynamic interval ratio method calculated using cervical hyperextension-flexion X-ray films. Secondly, we aim to evaluate the relationship between the posterior atlanto-occipital interval ratio and cervical spondylotic myelopathy and explain the rationale.

Methods: We reviewed 83 cases with visible cervical dynamic X-ray films in our hospital from February 2015 to December 2018. Cases were divided into 2 groups according to their diagnosis (with or without spondylotic myelopathy). Radiographic measurements included the shortest distance between the posterior arch of the atlas and the occipital bone and cervical range of motion, and demographic data such as gender, age, and body mass index were also extracted. The posterior atlanto-occipital interval ratio (distance at hyperextension position/distance at hyperflexion position) was determined using logistic regression analysis models between the 2 groups.

Results: We included 40 cases in the disease group and 43 cases in the control group. The mean posterior atlanto-occipital interval ratio was 0.65 ± 0.30 (mean \pm standard deviation) in the disease group and 0.30 ± 0.28 in the control group, with a significant difference ($P < 0.01$). There was no correlation between the posterior atlanto-occipital interval ratio and gender or body mass index. However, the interval ratio had strong correlations with age, cervical spondylotic myelopathy, and Japanese Orthopaedic Association scores. Age, posterior atlanto-occipital interval ratio, and interval distance at hyperextension in the disease group were higher than those of the control group. Contrastingly, range of motion, Japanese Orthopaedic Association scores, and interval distance at the disease group's hyperflexion position were lower than in the control group. In all cases, the risk of cervical spondylotic myelopathy in the T2 group (cases with middle posterior atlanto-occipital interval ratio, according to the tertiles) was 6 times more than the T1 group (cases with lower ratio), and the T3 group (cases with higher ratio) had a 26.4 times greater risk than the T1 group.

Conclusions: Our results suggest that the posterior atlanto-occipital interval ratio is a simple and meaningful parameter that could provide prognostic value for the risk of cervical spondylotic myelopathy through the imaging examinations of the selected cases. Higher posterior atlanto-occipital interval ratios indicate a greater risk for cervical spondylotic myelopathy and cervical musculoskeletal dysfunction. A higher posterior atlanto-occipital interval ratio may manifest undetected posterior atlanto-occipital stiffness, which needs more pathological evidence in future studies.

Keywords: A new ratio method; posterior atlanto-occipital stiffness; posterior atlanto-occipital interval ratio; cervical spondylotic myelopathy; cervical musculoskeletal dysfunction

Submitted Aug 19, 2020. Accepted for publication Mar 12, 2021.

doi: 10.21037/qims-20-986

View this article at: <http://dx.doi.org/10.21037/qims-20-986>

Introduction

Cervical spondylotic myelopathy is a very common degenerative disease that can result from various pathophysiologies and has numerous manifestations (1-3). Consequently, cervical musculoskeletal dysfunction and neurological impairment are observed in patients of all ages (4-7). The total pathogenesis of this type of degeneration has not yet been fully understood thus far, and many factors are responsible for causing cervical spondylotic myelopathies, such as forward head posture, neck strain, stress, depression, sports, and occupational activities.

Traditionally, spondylotic myelopathy generally begins with degenerative changes in the intervertebral discs causing secondary changes in surrounding soft tissue and bony structures (8). Nevertheless, we noticed that many cases had a higher ratio of posterior atlanto-occipital interval (PAOI) (Figure 1), which was calculated by hyperextension-flexion X-ray films, and those affected were more susceptible to developing cervical spondylotic myelopathy. We hypothesized the existence of an undetected disease, and the disease could cause the development of cervical spondylotic myelopathy. Furthermore, the relationship between the interval ratio, cervical spondylotic myelopathy, and musculoskeletal dysfunction has not been examined in previous literature.

Our study aims to introduce the dynamic interval ratio method and its correlation with case demographics and, more importantly, evaluate the relationship between PAOI and cervical spondylotic myelopathy. We presumed that an unrecognized posterior atlanto-occipital stiffness caused a higher interval ratio, and the PAOI ratio could be used as an indicator to assess the risk of cervical spondylotic myelopathy.

Methods

Case population and data selection

This work has been reported following the STROCSS criteria (9) and registered at [https://www.researchregistry.com/\(UIN: 5772\)](https://www.researchregistry.com/(UIN: 5772)). The institutional review board approved the study, and patient consent was waived due to its retrospective nature. The present study reviewed

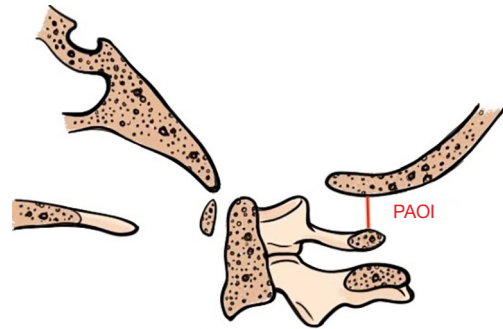


Figure 1 Diagram of the posterior atlanto-occipital interval.

the clinical records and musculoskeletal examinations of consecutive cases between February 2015–December 2018 in a single orthopedic center (Figure 2). Cases were divided into 2 comparison groups according to cervical spondylotic myelopathy diagnosis: group A (with cervical spondylotic myelopathy) and group B (without cervical spondylotic myelopathy and considered normal cases). The database was examined for cases with a diagnosis of cervical spondylotic myelopathy, according to the reports of magnetic resonance imaging (MRI) and X-ray examinations, and the detailed standards were described in relative studies (10-14). The cases' extracted demographic data included gender, age, and body mass index (BMI). The clinical examination records included cervical Range of Motion (ROM), Neck Disability Index (NDI) scores (maximum score 50) and cervical Japanese Orthopedic Association (JOA) scores (score of 17 points for cervical spondylotic myelopathy). The imaging examinations included sagittal cervical dynamic X-rays (neutral, hyperflexion, and hyperextension position) and routine clinical MRI scans, consisting of T1- and T2-weighted sequences in the sagittal plane and T2-weighted images in the axial orientation. Only cases with X-rays that showed identifiable anatomical markers in the cervical and atlanto-occipital segments on dynamic X-rays were included. The hyperflexion and hyperextension sagittal cervical X-rays were obtained using maximum active effort to move the cervical spine. Finally, we selected 40 cases (group A) that met our criteria.

Cases in group B without cervical spondylotic myelopathy were selected from the emergency room. The

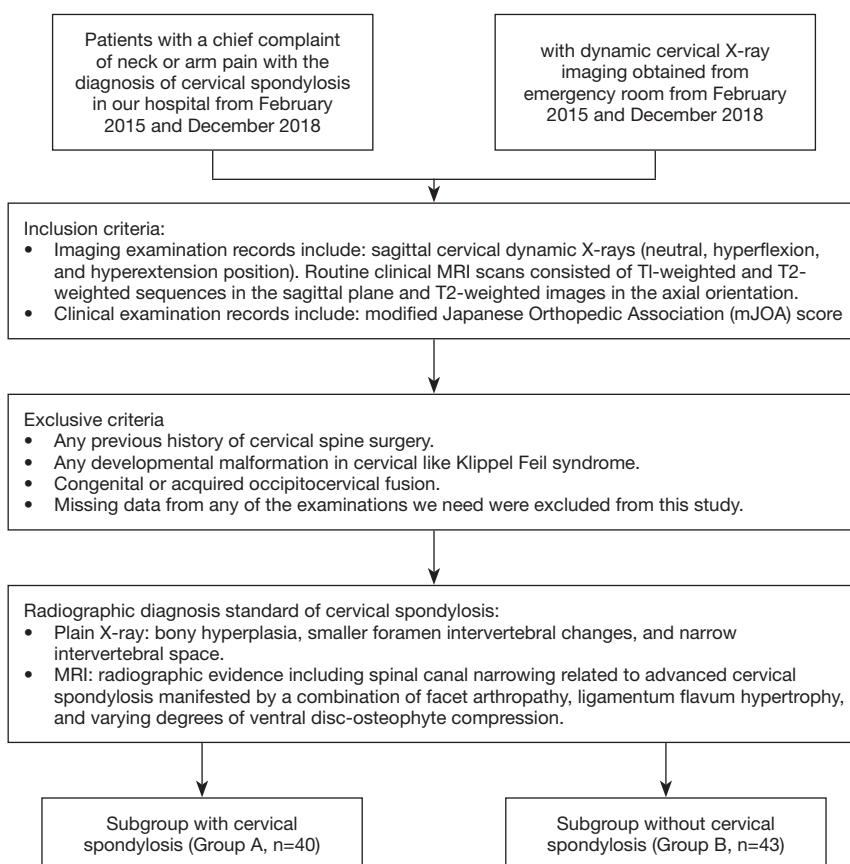


Figure 2 Flow diagram of the study.

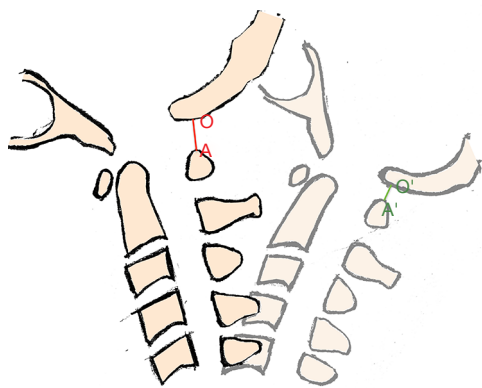


Figure 3 The measurement of the PAOI ratio (A'O'/AO).

included cases were selected by reviewing the imaging database from February 2015-December 2018 until group B included more than 40 cases. Cases with cervical spinal abnormalities, fractures, dislocations, or a history of previous or current neurological symptoms related to

the cervical spine were eliminated. Group B consisted of cases without reported imaging changes or degenerative manifestations. Cases in the 2 groups with (I) any previous history of cervical spine surgery, (II) any developmental cervical malformation, such as Klippel Feil syndrome, (III) any congenital or acquired occipitocervical fusion, and (IV) missing data from any of the examinations we required were excluded from this study.

Image analysis

All X-ray images obtained in our institution were interpreted and diagnosed by experienced radiologists. The radiographic analysis included measuring the dynamic interval ratio and the range of motion (flexion-extension) using the following methods: (I) the interval ratio, defined as the ratio between the PAOI at the hyperflexion position and hyperextension position, as demonstrated in *Figure 3*; PAOI ratio = distance at hyperextension position (A'O')/ distance at hyperflexion position (AO), and (II) the range

Table 1 Characteristics of all cases

Characteristic	All (n=83)	Group A (n=40)	Group B (n=43)	P
Male, n (%)	37 (44.6)	19 (47.5)	18 (41.9)	0.606
Age	48.04±17.06	53.18±17.07	43.26±15.78	0.007
BMI	24.76±3.39	24.22±3.21	25.13±3.65	0.315
PAOI at hyperflexion	7.50±3.14	6.92±3.20	8.04±3.09	0.259
PAOI at hyperextension	3.35±1.31	4.41±1.57	2.38±1.06	0.001
PAOI at neutral position	5.49±2.53	5.45±2.38	5.53±2.67	0.914
Ratio of PAOI (E/F)	0.45±0.34	0.65±0.30	0.30±0.28	<0.001
Cobb angle at flexion	17.87±10.16	16.12±10.84	19.50±9.32	0.132
Cobb angle at extension	36.88±15.20	34.16±14.60	39.41±15.47	0.116
ROM	54.75±18.22	50.28±16.52	58.91±18.92	0.030
NDI [50]	8.61±7.99	16.52±3.21	1.26±0.25	<0.001
JOA [17]	14.35±1.35	12.01±2.37	16.53±0.41	0.012

The table shows the detailed demographics between the 2 groups. BMI, body mass index; PAOI, posterior atlanto-occipital interval; ROM, range of motion; NDI, Neck Disability Index; JOA: Japanese Orthopedic Association.

of motion, which was the angle measured as the sum of 2 angles between the C2 and C7 posterior vertebral edge at flexion and extension position. The radiographic data from all cases were measured by 2 experienced, independent observers from our department twice to reduce intra- and inter-observer bias, and the mean values were determined and utilized.

Data analysis

The interval ratio values were compared between different groups. We present categorical variables with frequencies and percentages and continuous variables with median±standard deviation (SD) and interquartile range (IQR). The correlations between case demographic data and interval ratios were investigated using the linear regression model. Considering the influence of PAOI stiffness on the cervical spine, the interval ratios of all 83 cases were divided into 3 groups, according to the tertiles. Logistic regression analysis was used to analyze the relationship between PAOI ratio and cervical spondylotic myelopathy.

Comparisons of continuous data, including BMI, JOA scores, and interval ratios, were analyzed by the independent sample t-test, and categorical data were analyzed using the Chi-square test. All analyses were performed using the IBM SPSS Statistics software (SPSS Statistics 20.0 Inc). A P value less than 0.05 was regarded as statistically significant.

Results

A total of 83 cases were evaluated and the data were described in different groups. *Table 1* shows the detailed demographics between the 2 groups. The distances of the PAOI in group A (with cervical spondylotic myelopathy) were 4.85±2.08, 6.92±3.20, and 4.41±1.57 mm in the neutral, hyperflexion, and hyperextension position, respectively. In group B, distances were 5.53±2.67, 8.04±3.09, and 2.38±1.06 mm in the neutral, hyperflexion, and hyperextension position, respectively. The intraclass correlation coefficients (ICC) for the intra-observer reliabilities of the ratio were excellent, and ranged from 0.922–0.997, however, the inter-observer reliabilities for distances in each group were unsatisfactory, ranging from 0.657–0.702 (*Table 2*). Statistical differences existed in age, distances between PAOI, PAOI ratio, ROM, and JOA scores compared between the 2 groups. Age, interval ratio, and interval distance at hyperextension of group A were higher than those of group B. Contrastingly, ROM, JOA scores, and interval distance at the hyperflexion position in group A were lower compared to group B.

The interval ratios of all 83 cases were divided into 3 groups (T1, T2, T3) according to the tertiles in *Table 3*. Logistic regression analysis was used to analyze the relationship between PAOI ratio and cervical spondylotic myelopathy. The risk of cervical spondylotic myelopathy in

Table 2 Inter- and intra-observer reliability

	Inter-observer	Intra-observer
C0-1 at hyperflexion	0.683 (0.661-0.718)	0.891 (0.862-0.917)
C0-1 at neutral position	0.739 (0.695-0.757)	0.912 (0.889-0.935)
C0-1 at hyperextension	0.710 (0.664-0.711)	0.909 (0.869-0.920)
Ratio (E/F of C0-1)	0.968 (0.922-0.997)	0.981 (0.976-0.989)

The intraclass correlation coefficients (ICC) for the intra-observer reliabilities of the ratio were excellent, however, the inter-observer reliabilities of distances for each group were unsatisfactory.

Table 3 Risk of disease segregated by tertiles of ratio (odds ratio and 95% confidence intervals)

	T1	T2	T3	P _{trend}
Crude	Reference	6.00 (1.65, 21.84)	26.4 (6.28, 111.03)	<0.001
Adjusted	Reference	6.31 (1.59, 24.95)	36.33 (7.50, 175.96)	<0.001

The interval ratios of all 83 cases were divided into 3 groups according to the tertiles.

the T2 group (middle PAOI ratio) was 6 times more than the T1 group (lower PAOI ratio), and the risk in the T3 group (higher PAOI ratio) was 26.4 times more than the T1 group (lower PAOI ratio). The risk was still meaningful after adjusting for age, gender, JOA score, and ROM. The higher the PAOI ratio reflected by plain films, the higher the risk of cervical spondylotic myelopathy for patients.

Illustrative cases

Case 1 (Figures 4 and 5)

A 12-year-old boy with a chief complaint of neck and shoulder pain for more than 2 years presented to our hospital. The patient was neurologically intact, and the physical examination showed a limited cervical range of motion. Although the hyperflexion-extension plain film examination showed no instability, an increase in the ratio of PAOI (PAOI = ~1) and extremely small PAOI distance were observed. In addition, the patient was found to have cervical curvature changes and mild cervical disc degeneration on MRI scans. Conservative treatment was initiated.

Case 2 (Figures 6 and 7)

A 26-year-old female with a history of neck and shoulder pain for 8 years presented with a chief complaint of left side radicular pain of 7 months' duration. Physical examination showed limited neck motion, left neck and shoulder pain, numbness with hyposensitivity in the C5 distribution, and left arm inflexibility. No specific trauma was recalled.

Radiographic examination of the cervical spine showed posterior atlanto-occipital stiffness (interval ratio= ~0.81) and mild diminution in the height of the C5/6 disc space. MRI scans showed a large central herniation of the C5/6 disc, with signs of mild spinal compression. Conservative treatment was initiated for this patient.

Case 3 (Figures 8 and 9)

A 65-year-old male without significant past medical history presented to the outpatient department with a chief complaint of difficulty walking for more than 10 months' duration, and neck and shoulder pain for 40 years. Physical examination showed bilateral upper extremity hyperreflexia, bilateral Babinski reflex, a positive Hoffman's test, and a decrease in multidermatomal upper extremity sensation during pinprick testing. Furthermore, decreased grip strength and compromised coordination was noted, evidenced by altered gait pattern. Radiographic examination of the cervical spine showed a loss of activity in the PAOI on X-ray (ratio of PAOI = ~0.6). The MRI demonstrated the presence of severe spinal compression in C4/5. The patient elected to undergo cervical surgical treatment.

Discussion

Due the promotion of electronic office technologies and the common phenomenon of phubbing, the age of people suffering from cervical spondylotic myelopathy currently tends to be younger. This phenomenon may be related to

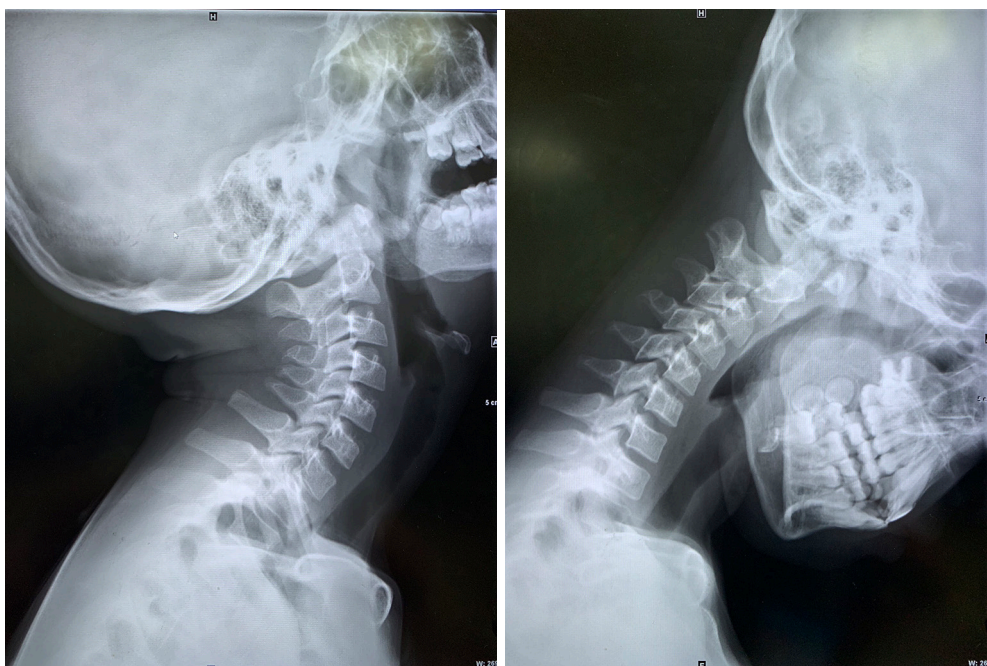

Figure 4 The normal sagittal X-ray shows an illustrative case of the posterior atlanto-occipital interval.

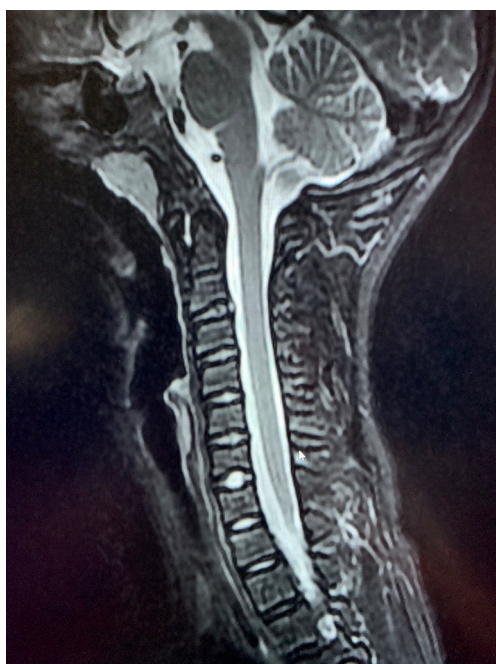

Figure 5 The magnetic resonance imaging of case 1 shows cervical curvature changes and mild cervical disc degeneration.

the environment, living habits, and other unrecognized factors (2). It is important to explore the relevant and unrecognized pathogenic factors, which will facilitate clearer and more accurate diagnosis and treatment of cervical spondylotic myelopathy. The aim of this study was to investigate the utilization of the PAOI ratio, which can be measured and calculated by means of sagittal cervical X-rays, as a novel method for evaluating the risk of cervical spondylotic myelopathy.

Our study found that a higher PAOI ratio had a strong linear correlation with cervical spondylotic myelopathy, suggesting that the interval ratio can be used to estimate the risk of cervical spondylotic myelopathy. In the present study, we termed the disease posterior atlanto-occipital stiffness. In our opinion, as a consequence of PAOI stiffness, normal upper cervical activity was lost, resulting in a series of biomechanical effects on the lower cervical spine. As displayed in *Table 1*, we found that a higher PAOI ratio was correlated with lower ROM, which may be caused by the stiffness of the upper cervical segment. In cases of younger patients, due to the short duration

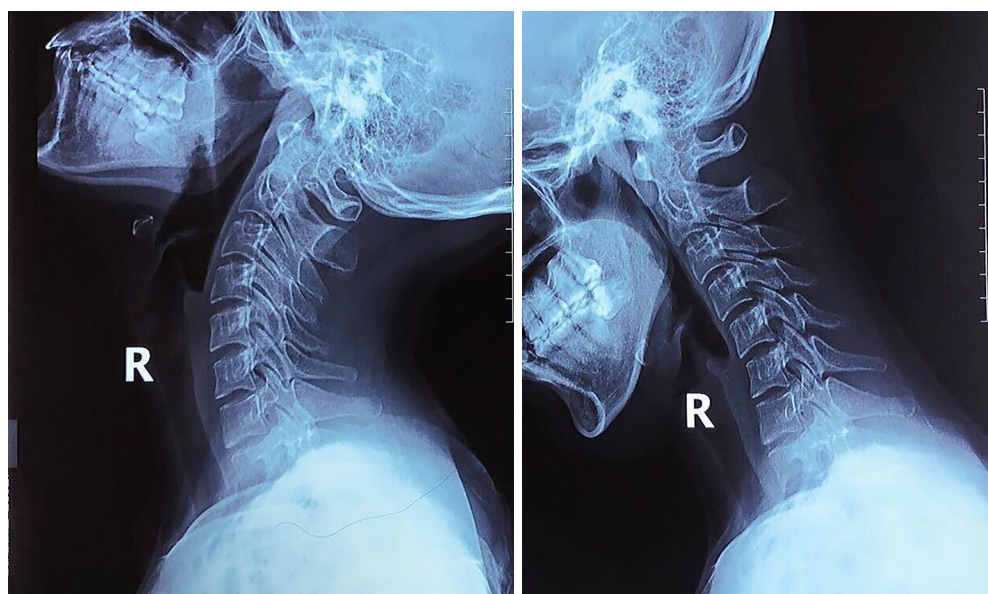


Figure 6 The hyperflexion-extension plain film examination of case 2.

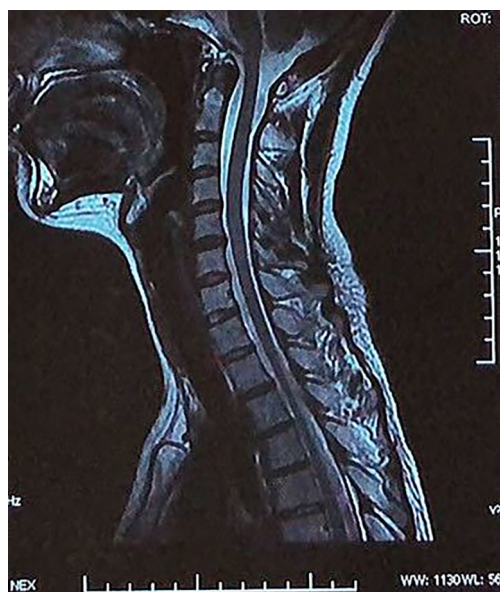

Figure 7 The magnetic resonance imaging scans of case 2 show a large central herniation of the C5/6 disc with signs of mild spinal compression.

of stiffness on the lower cervical vertebrae, the more common imaging findings were curvature straightening. In cases of advanced age, since the effects of stiffness on the lower cervical segment have existed for many years, pathology in this population was more diversified and

serious, including bony hyperplasia, smaller foramen intervertebral changes, and narrow intervertebral spaces. Based on our observations, we believe that an increased interval ratio should make a spine surgeon suspicious for the presence of atlanto-occipital stiffness, when accepting cases with cervical spine X-ray imaging. We believe that PAOI stiffness is a disease that can coexist with cervical spondylotic myelopathy and may aggravate the progress of cervical spondylotic myelopathy. According to our logistic regression analysis, the risk of cervical musculoskeletal dysfunction in the T3 group, which represented the stiffness cases, was 26.4 times more than the T1 group, which represented cases without stiffness and with normal activity. We found this phenomenon in all examined age groups, and illustrated this detail with 3 cases of different ages, as mentioned in the results section.

The mean ratio of dynamic PAOI in group A was 0.65 ± 0.30 , and in group B the value was 0.30 ± 0.28 . The mean distances between the posterior arch of atlas and the occipital bone at the hyperflexion position, the hyperextension position, and the neutral position were, respectively, 6.92 ± 3.20 , 4.41 ± 1.57 , and 4.85 ± 2.08 mm in group A, and 8.04 ± 3.09 , 2.38 ± 1.06 , and 5.53 ± 2.17 mm in group B. The intra-observer reliability for the new radiographic ratio was good, and the inter-observer reliability was also satisfactory. Unexpectedly, the inter-observer reliability of the distance parameter between

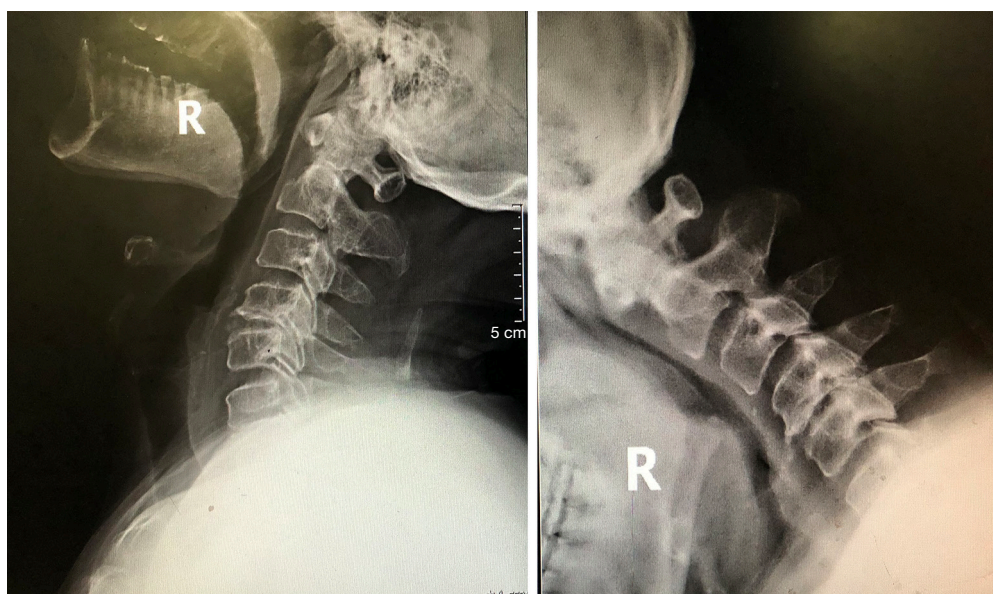


Figure 8 The hyperflexion-extension plain film examination of case 3 shows a loss of activity in the posterior atlanto-occipital interval.

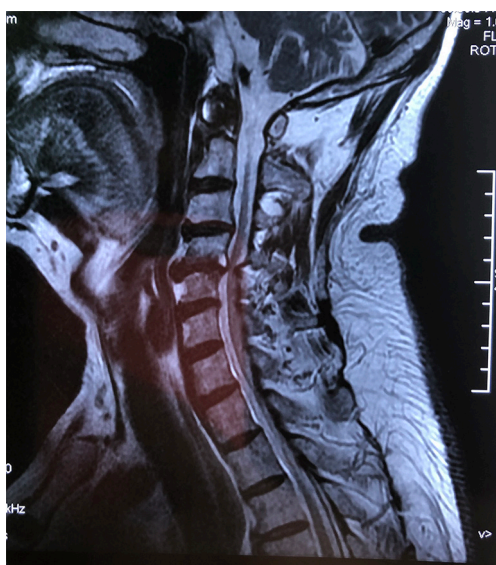


Figure 9 The magnetic resonance imaging of case 3 demonstrated the presence of severe spinal compression in C4/5.

the posterior arch of atlas and the occipital bone was low (0.661–0.739, shown in *Table 2*). The reasons are as follows: (I) for different observers, the marker point in the imaging for measuring the distance may be different, which could have resulted in measurement bias, and (II) the distances of the interval could be biased due to the different magnification rates between patients. Thus, we believe that

calculating the ratio of the distances by the same marker point would be more accurate. As a result, our outcomes indicate that the ratio method is more reliable compared to direct numerical comparison methods, which was similar to the method in a study by Pavlov *et al.* (15).

An increased ratio may suggest the existence of stiffness in the lesion of the craniovertebral junction, especially between the atlas and the occipital bone. The posterior interstitial tissue includes many anatomical structures, such as the posterior membrane of the occipital and rectus capitis posterior minor, that are at risk for possible pathological changes including contracture, fibrosis, and stiffness (16-19). These abnormal changes can induce posterior atlanto-occipital stiffness, which results in an increase in the interval ratio. The closer the ratio approaches 1, the narrower the effective space between the occipital and atlas bones. The mean distance of the PAOI at neutral position in group A cases was 4.85 ± 2.08 mm, which was 0.68 mm smaller than group B cases. There was no significant difference in the distance of the PAOI at neutral position between the 2 groups with our small sample size. However, the distance was smaller at the hyperflexion position and larger at the hyperextension position in group A. Considering the imaging changes that are associated with the higher interval ratio phenomenon, we hypothesize that the effects of posterior atlanto-occipital stiffness may result in the compensatory mechanisms that occur in the lower and

upper spine segments. A higher ratio suggests that stiffness may predispose patients to an increased risk of cervical spondylotic myelopathy. This may be the reason why cervical spondylotic myelopathy tends to occur in older people rather than young people, as reported in a study by Mattucci *et al.* (17) addressing craniovertebral lesions. This study on the tectorial membrane complex reported that younger specimens exhibited higher failure force and stiffness rates than older specimens.

Ligaments and membranes share pivotal roles in junctional ability and are key to orienting medical or surgical indications in this unique area of the spine (20). Several studies have described post-occipital interval-related diseases. In 1992, Kahn *et al.* (21) conducted an investigation focusing on the posterior intervertebral spaces of the craniovertebral interval. In the past, only a few case reports have reported progressive foramen magnum syndrome caused by the deposition of calcium pyrophosphate dihydrate crystals in the posterior longitudinal ligament (18,22). Kaale *et al.* (23) reported on the influence of Whiplash-associated disorder on neck ROM and found that an abnormal posterior atlanto-occipital membrane is associated with a shorter range of rotation. However, the majority of studies on atlanto-occipital problems involved the anterior occipitovertebral relationship seen on lateral radiographs of the cervical spine (24-27).

In our analysis, some significant imaging findings were noteworthy. One X-ray depicted the posterior arch of atlas approaching the occipital bone. In several other cases, the distance measured between the intervals was extremely small, and the posterior arch of atlas was extremely close to the occipital bone, despite the location of cervical positions. We believe that this phenomenon resulted from serious posterior atlanto-occipital stiffness of the craniovertebral junction, which could develop at different ages and lead to various manifestations. In young patients with suggested radiographic posterior atlanto-occipital stiffness, imaging changes mostly manifested in cervical curvature straightening, which warrants the need to address the future risk of spondylotic myelopathy. The older patient with the same stiffness disease showed more imaging changes, including bony hyperplasia, smaller foramen intervertebral changes, and narrow intervertebral spaces, which were the result of stress changes in the upper cervical spine for several years. The small distance resulting from extreme posterior atlanto-occipital stiffness requires future evaluation in a large sample size study, as well as additional studies on the pathological mechanisms.

Limitations

This study has several limitations. Firstly, our results were collected only from the perspective of clinical and tomographic findings, with an absence of etiological and pathological investigations. Secondly, given that the 2 groups in our study were chosen consecutively among cases at our hospital and not randomly, there was an unforeseen selection bias in this grouping method. Thirdly, since we did not study the relationship between age and PAOI ratio, we hope to evaluate this relationship in future cross-sectional studies. Finally, only the JOA and NDI were used to assess cervical spinal cord function. However, NF-36 was not used in our study, which means we could not detect the potential correlation between PAOI and the health survey results of the patients. Above all, the ability to prove the causal relationship was limited. Therefore, large-scale and multicenter studies should be established to more comprehensively examine the effectiveness of PAOI in the evaluation and diagnosis of cervical spondylotic myelopathy. To our knowledge, despite the above shortcomings, this is the first study proposing a new radiographic ratio method for PAOI calculation, along with an explanation of its rationale.

Conclusions

Through an examination of patients' imaging findings, the PAOI ratio has been discovered as a simple and meaningful parameter, and could provide prognostic value for the risk of cervical spondylotic myelopathy and musculoskeletal dysfunction. A higher PAOI ratio represents a higher risk for cervical musculoskeletal dysfunction and posterior atlanto-occipital stiffness, which could result in relative changes that require additional pathological evidence through future studies. Therefore, a higher ratio of PAOI is a useful method to evaluate the high risk of cervical spondylotic myelopathy.

Acknowledgments

Funding: Capital Characteristic Clinical project of Beijing Municipal Science and Technology Commission (<http://www.bjkw.gov.cn/n8785584/index.html>) (Grant no. Z161100000516009).

Footnote

Conflicts of Interest: All authors have completed the ICMJE

uniform disclosure form (available at <http://dx.doi.org/10.21037/qims-20-986>). The authors have no conflicts of interest to declare.

Ethical Statement: The institutional review board approved the study, and patient consent was waived due to its retrospective nature.

Open Access Statement: This is an Open Access article distributed in accordance with the Creative Commons Attribution-NonCommercial-NoDerivs 4.0 International License (CC BY-NC-ND 4.0), which permits the non-commercial replication and distribution of the article with the strict proviso that no changes or edits are made and the original work is properly cited (including links to both the formal publication through the relevant DOI and the license). See: <https://creativecommons.org/licenses/by-nc-nd/4.0/>.

References

- Kelly JC, Groarke PJ, Butler JS, Poynton AR, O'Byrne JM. The natural history and clinical syndromes of degenerative cervical spondylosis. *Adv Orthop* 2012;2012:393642.
- Amenta PS, Ghobrial GM, Krespan K, Nguyen P, Ali M, Harrop JS. Cervical spondylotic myelopathy in the young adult: a review of the literature and clinical diagnostic criteria in an uncommon demographic. *Clin Neurol Neurosurg* 2014;120:68-72.
- An SB, Lee JJ, Kim TW, Lee N, Shin DA, Yi S, Kim KN, Yoon DH, Ha Y. Evaluating the differences between 1D, 2D, and 3D occupying ratios in reflecting the JOA score in cervical ossification of the posterior longitudinal ligament. *Quant Imaging Med Surg* 2019;9:952-9.
- Hayashi H, Okada K, Hashimoto J, Tada K, Ueno R. Cervical spondylotic myelopathy in the aged patient. A radiographic evaluation of the aging changes in the cervical spine and etiologic factors of myelopathy. *Spine (Phila Pa 1976)* 1988;13:618-25.
- Fehlings MG, Tetreault L, Nater A, Choma T, Harrop J, Mroz T, Santaguida C, Smith JS. The Aging of the Global Population: The Changing Epidemiology of Disease and Spinal Disorders. *Neurosurgery* 2015;77 Suppl 4:S1-5.
- Huynh TR, Lagman C, Sweiss F, Shweikeh F, Nuno M, Drazin D. Pediatric spondylolysis/spinal stenosis and disc herniation: national trends in decompression and discectomy surgery evaluated through the Kids' Inpatient Database. *Childs Nerv Syst* 2017;33:1563-70.
- Lee JJ, Lee N, Oh SH, Shin DA, Yi S, Kim KN, Yoon DH, Shin HC, Ha Y. Clinical and radiological outcomes of multilevel cervical laminoplasty versus three-level anterior cervical discectomy and fusion in patients with cervical spondylotic myelopathy. *Quant Imaging Med Surg* 2020;10:2112-24.
- Iyer A, Azad TD, Tharin S. Cervical Spondylotic Myelopathy. *Clin Spine Surg* 2016;29:408-14.
- Agha R, Abdall-Razak A, Crossley E, Dowlut N, Iosifidis C, Mathew G, Group S. STROCSS 2019 Guideline: Strengthening the reporting of cohort studies in surgery. *Int J Surg* 2019;72:156-65.
- Cuellar J, Passias P. Cervical Spondylotic Myelopathy A Review of Clinical Diagnosis and Treatment. *Bull Hosp Jt Dis (2013)* 2017;75:21-9.
- Perlman R, Hawes LE. Cervical spondylolisthesis. *J Bone Joint Surg Am* 1951;33-A:1012-3.
- Redla S, Sikdar T, Saifuddin A, Taylor BA. Imaging features of cervical spondylolysis--with emphasis on MR appearances. *Clin Radiol* 1999;54:815-20.
- Park MS, Moon SH, Oh JK, Lee HW, Riew KD. Natural History of Cervical Degenerative Spondylolisthesis. *Spine (Phila Pa 1976)* 2019;44:E7-E12.
- Ellingson BM, Woodworth DC, Leu K, Salamon N, Holly LT. Spinal Cord Perfusion MR Imaging Implicates Both Ischemia and Hypoxia in the Pathogenesis of Cervical Spondylosis. *World Neurosurg* 2019;128:e773-e781.
- Pavlov H, Torg JS, Robie B, Jahre C. Cervical spinal stenosis: determination with vertebral body ratio method. *Radiology* 1987;164:771-5.
- Pimenta NJ, Gusmao SS, Kehrli P. Posterior atlanto-occipital and atlanto-axial area and its surgical interest. *Arq Neuropsiquiatr* 2014;72:788-92.
- Mattucci SF, Moulton JA, Chandrashekar N, Cronin DS. Strain rate dependent properties of human craniovertebral ligaments. *J Mech Behav Biomed Mater* 2013;23:71-9.
- Kawano N, Matsuno T, Miyazawa S, Iida H, Yada K, Kobayashi N, Iwasaki Y. Calcium pyrophosphate dihydrate crystal deposition disease in the cervical ligamentum flavum. *J Neurosurg* 1988;68:613-20.
- Krakenes J, Kaale BR, Moen G, Nordli H, Gilhus NE, Rorvik J. MRI of the tectorial and posterior atlanto-occipital membranes in the late stage of whiplash injury. *Neuroradiology* 2003;45:585-91.
- Debernardi A, D'Aliberti G, Talamonti G, Villa F, Piparo M, Collice M. The craniovertebral junction area and the role of the ligaments and membranes. *Neurosurgery* 2011;68:291-301.
- Kahn JL, Sick H, Koritké JG. Les espaces intervertébraux

- postérieurs de la jointure crânio-rachidienne. *Cells Tissues Organs* 1992;144:65-70.
22. Ciricillo SF, Weinstein PR. Foramen magnum syndrome from pseudogout of the atlanto-occipital ligament. Case report. *J Neurosurg* 1989;71:141-3.
 23. Kaale BR, Krakenes J, Albrektsen G, Wester K. Active range of motion as an indicator for ligament and membrane lesions in the upper cervical spine after a whiplash trauma. *J Neurotrauma* 2007;24:713-21.
 24. Browd S, Healy LJ, Dobie G, Johnson JT, 3rd, Jones GM, Rodriguez LF, Brockmeyer DL. Morphometric and qualitative analysis of congenital occipitocervical instability in children: implications for patients with Down syndrome. *J Neurosurg* 2006;105:50-4.
 25. Riew KD, Hilibrand AS, Palumbo MA, Sethi N, Bohlman HH. Diagnosing basilar invagination in the rheumatoid patient. The reliability of radiographic criteria. *J Bone Joint Surg Am* 2001;83:194-200.
 26. Brockmeyer DL, Brockmeyer MM, Bragg T. Atlantal hemi-rings and craniocervical instability: identification, clinical characteristics, and management. *J Neurosurg Pediatr* 2011;8:357-62.
 27. Harris JH, Jr., Carson GC, Wagner LK. Radiologic diagnosis of traumatic occipitovertebral dissociation: 1. Normal occipitovertebral relationships on lateral radiographs of supine subjects. *AJR Am J Roentgenol* 1994;162:881-6.

Cite this article as: Tan M, Song J, Wang Y, Gong L, Sun Y, Yi P, Yang F, Tang X, Hao Q, Li W. The ratio of the posterior atlanto-occipital interval (PAOI): a novel radiographic ratio method evaluating the risk of cervical spondylotic myelopathy—a case-control study. *Quant Imaging Med Surg* 2021;11(7):3018-3028. doi: 10.21037/qims-20-986