



Since January 2020 Elsevier has created a COVID-19 resource centre with free information in English and Mandarin on the novel coronavirus COVID-19. The COVID-19 resource centre is hosted on Elsevier Connect, the company's public news and information website.

Elsevier hereby grants permission to make all its COVID-19-related research that is available on the COVID-19 resource centre - including this research content - immediately available in PubMed Central and other publicly funded repositories, such as the WHO COVID database with rights for unrestricted research re-use and analyses in any form or by any means with acknowledgement of the original source. These permissions are granted for free by Elsevier for as long as the COVID-19 resource centre remains active.

Similarities and perspectives on the two C's—Cancer and COVID-19

Jecko Thachil¹ | Alok Khorana² | Marc Carrier^{3,4}

¹Department of Haematology, Manchester University Hospitals, Manchester, UK

²Department of Hematology and Medical Oncology, Taussig Cancer Institute and Case Comprehensive Cancer Center, Cleveland, Ohio, USA

³Cleveland Clinic, Cleveland, Ohio, USA

⁴Department of Medicine, University of Ottawa, The Ottawa Hospital Research Institute, Ottawa, Ontario, Canada

Correspondence

Jecko Thachil, Department of Haematology, Manchester Royal Infirmary, Oxford road, M13 9WL Manchester, UK.
Email: jecko.thachil@mft.nhs.uk

Abstract

COVID-19 continues to dominate the health-care burden in the twenty-first century. While health-care professionals around the world try their best to minimize the mortality from this pandemic, we also continue to battle the high mortality from different types of cancer. For the hemostasis and thrombosis specialist, these two conditions present some unusual similarities including the high rate of thrombosis and marked elevation of D-dimers. In this forum article, we discuss these similarities and provide some considerations for future research and therapeutic trials.

KEYWORDS

anticoagulation, cancer, COVID-19, D-dimer, embolism, thrombosis

1 | INTRODUCTION

The year 2020 was different from any other in the last 100 years with the impact the COVID-19 pandemic had on the global population. This viral infection has caused enough morbidity and mortality in such a short period as malignancies have done to the human population over many decades. When we look forward to a post-COVID-19 era with “respair” (a fourteenth-century word meaning “the return of hope after a period of despair”), it would be worthwhile looking at these two C's—COVID-19 and cancer—to see if there may be any common factors and whether we can learn from the latest scourge to inform us of the age-old menace. Some of the similarities between these two conditions are the very high D-dimers, markedly elevated thrombotic risk including multi-system thrombosis, and inadequacy of anticoagulation in certain cases.^{1–3} We provide some perspectives on these laboratory abnormalities and clinical features to assist future basic science research and clinical trials.

2 | VERY HIGH D-DIMERS

D-dimers are created during the process of fibrinolysis when covalently bound D-domains of adjacent fibrin monomers are created by plasmin degradation of cross-linked fibrin.¹ D-dimers were developed as a laboratory marker for the exclusion of venous thrombosis and indeed have a very good predictive potential in this clinical endpoint.⁴ Despite its admirable role as a negative predictive marker, unfortunately, it is often used as a positive diagnostic marker for thrombosis in patients including those with COVID-19.^{5,6} Markedly elevated D-dimers were noted early on in patients with COVID-19.⁷ Different authors correlated very high D-dimers with mortality and suggested particular cut-off levels as a prognostic indicator.^{6–9} For example, a cut-off value of 2.0 µg/ml was shown to have a sensitivity of 92.3% and a specificity of 83.3% in predicting hospital mortality.¹⁰ A pooled analysis of the literature at the time of publication also identified D-dimer to be associated with the severity of COVID-19 (weighted mean difference: 2.97 mg/L; 95% confidence interval [CI] 2.47–3.46 mg/L between COVID-19 patients with or without severe disease).¹¹ However, one of the misunderstood aspects of this laboratory marker is to consider all the D-dimers in COVID-19 result from intravascular clot breakdown and thus behave as a marker of thrombosis.¹²

2.1 | D-dimer in lung inflammation (COVID-19)

D-dimer is generated by the breakdown of cross-linked fibrin that can happen inside the blood vessels but also in the extravascular space^{4,13} (see Figure 1). In patients affected by severe COVID-19, a considerable amount of D-dimers may be generated in the extravascular space; specifically in the alveolar space.^{12,14} In patients who develop acute lung injury with infectious or inflammatory conditions including COVID-19, one of the characteristic features is the leakage of plasma proteins into the alveolar space (sometimes termed “wet lung”).¹⁵ These plasma proteins, which may include inflammatory cytokines, may help in the local defense mechanism against airway-borne pathogens.¹⁵ But in addition to the inflammatory cytokines, the leaked plasma proteins also include fibrinogen and thrombin.¹⁶ Just as much as these proteins participate in clot formation in the vascular space, they also create fibrin in the alveolar space. Fibrin may serve the purpose of acting as a scaffold for the inflammatory cytokines to act out their defense function.¹⁷ Breakdown of this fibrin, which is necessary to main adequate gas exchange (the lungs have a vigorous fibrinolytic system), also creates D-dimer, which is reabsorbed into the vasculature and can be detected in blood samples. But the key difference here is that these D-dimers do not signify intravascular clot formation and thus do not behave as a marker for thrombosis. On the other hand, the increase in D-dimers would correlate with worsening acute lung injury, which may clinically manifest as increasing hypoxia and can thus be a useful prognostic indicator.¹⁸ Postmortem studies of COVID-19 patients have shown the exudative pattern (in keeping with the wet lung description) in all cases with hyaline membranes composed of serum proteins and fibrin.¹⁹ Polak et al. in their systematic review of the pathological findings in COVID-19 described a vascular pattern in which diffuse intra-alveolar fibrin deposition was noted in addition to microvascular thrombi; and intra-alveolar fibrin balls filling alveoli in conjunction with organizing pneumonia.²⁰ In a recent study of just over 120 patients with COVID-19, D-dimer values at peak were shown to be

an independent predictor of critical lung injuries irrespective of the inflammatory markers assessed by C reactive protein. D-dimer was also associated with increased in-hospital death or need for critical care support even in the absence of thrombotic events.²¹

2.2 | D-dimer in cancer

The malignant process very much mimics an inflammatory reaction with chronic inflammation suggested to be a risk factor for some types of cancers (see Figure 1).²² The inflammatory part of the tumors is the stromal component, which functions as the tumor nourisher with its rich supply of blood vessels.²³ In addition to new blood vessels, the other constituents of the stroma include connective tissue (which makes the tumor palpable), and a fibrin-gel matrix, which determines the stromal size.²⁴ Initial skeptics considered the presence of fibrin in tumor tissue as an epiphenomenon of ischemic necrosis or representative of the clot formed during removal of the tumor.²³ But, the identification of a process similar to that of vascular leakage in inflammatory processes (as described above in the lungs) has given proof to the concept of fibrin being a significant part of the stroma.²⁵ Increased vascular permeability allows extravasation of fibrinogen, which is acted on by the cancer procoagulants to create cross-linked fibrin.²⁶ The cross-linked fibrin in the stroma is degraded rapidly by the extensive fibrinolysis instigated by tumor-secreted plasminogen activators.²⁷ The key difference between inflammatory and tumor fibrin deposition is that the latter is an ongoing process due to the continued release of vascular permeability factor by the tumors.²⁸ The tumor-associated fibrin in high concentrations can prevent inflammatory cells reaching the tumor (detrimental to the host), although in low concentrations would have facilitated inflammatory function (beneficial to the host).²³ These observations would suggest that aggressive tumors and those who may be “resistant” to anti-cancer therapy may be associated with increased extravascular fibrin and subsequent fibrinolysis and hence raised D-dimers (see Table 1).

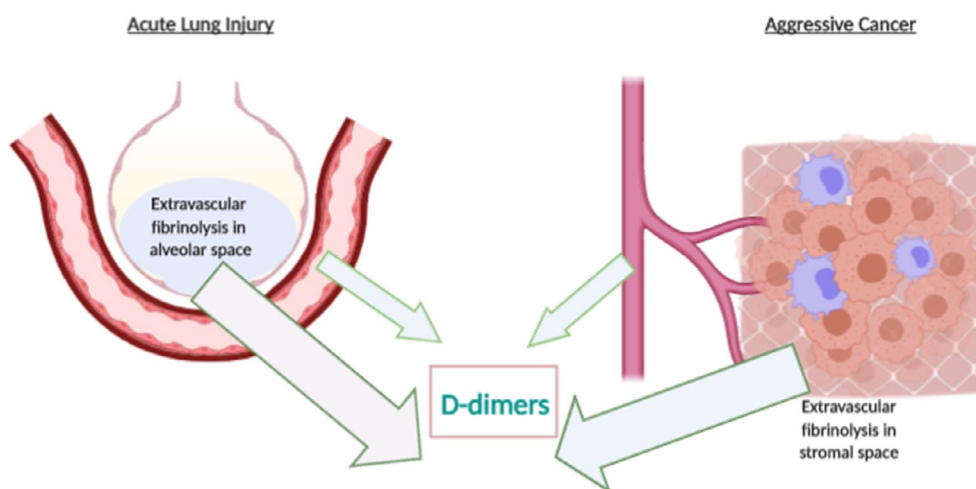


FIGURE 1 D-dimer production in acute lung injury and malignancies. Fibrinolysis in both these cases occurs in the extravascular spaces and intravascularly created using BioRender tool

TABLE 1 Comparison between COVID-19 and malignancy in relation to D-dimers, thrombus formation, and anticoagulation failure

	COVID-19	Malignancy
Mechanism of generation of D-dimers	<ul style="list-style-type: none"> • Thrombi breakdown • Intra-alveolar fibrinolysis (driven by virus induced thrombo-inflammation) 	<ul style="list-style-type: none"> • Thrombi breakdown • Extravascular fibrinolysis in the malignant stroma (driven by the malignant process)
Site of initial thrombus formation	<ul style="list-style-type: none"> • Pulmonary vasculature 	<ul style="list-style-type: none"> • Likely adjacent to the malignant focus in solid cancers
Localized vs. systemic thrombi	<ul style="list-style-type: none"> • Starts as pulmonary thrombi • Severe cases, thrombi in multiple circulatory beds 	<ul style="list-style-type: none"> • Differentiation not easy • May be as DVT, PE, unusual-site venous thrombi or arterial thrombi
Triggers for thrombi	<ul style="list-style-type: none"> • Thrombo-inflammation • Endothelialitis • Stasis from immobility 	<ul style="list-style-type: none"> • Cancer procoagulant • Vascular damage by tumor and its treatment • Immunothrombosis with immune check-point drugs • Stasis from compression or immobility
Reasons for anticoagulant failure	<ul style="list-style-type: none"> • Multiple mechanisms (e.g., inflammation, platelet hyperactivity, complement and contact system activation, and others) 	<ul style="list-style-type: none"> • Multiple mechanisms (e.g., cancer progression, platelet activation, immune activation, and others)

Abbreviations: DVT, deep vein thrombosis; PE, pulmonary embolism.

2.3 | Perspectives

- Because D-dimer can signify continuing inflammation, increasing D-dimers can be considered a prognostic factor in inflammatory conditions (in combination with other markers such as C-reactive protein).
- Serial monitoring of D-dimers may assist in predicting the development of acute respiratory distress syndrome in critically ill patients with underlying inflammation.
- Similarly increasing D-dimers may be considered a tumor marker indicating progression and/or metastasis in solid cancers.
- It would be interesting to see whether decrease in D-dimer values with anti-inflammatory therapies mirror clinical improvement.
- In the same manner, it would be useful to examine whether decrease in D-dimer is one of the markers of clinical efficacy of anti-cancer therapies.

3 | MARKEDLY ELEVATED RISK OF THROMBOSIS

One of the well-known clinical complications of COVID-19 is the markedly increased risk of thrombosis. This is similar to what has been observed in patients with malignancies with cancer-associated thrombosis now considered a speciality in itself. Some of the unusual thrombotic manifestations of the two C's are the development of pulmonary thrombosis in the absence of lower limb deep vein thrombosis and the simultaneous development of clots in various circulatory beds (Table 1).

3.1 | Pulmonary thrombosis in the two C's

Thrombus embolization to the lung vasculature is the most common cause of death in patients who develop deep vein thrombosis (DVT). Because more than half of the patients with a pulmonary embolism (PE) have an accompanying clot in the lower limb veins, there is widespread

assumption that screening for lower limb DVT can be a surrogate marker for PE.²⁹ However, clots can develop in the pulmonary vessels in the absence of DVT and can be often seen in patients with an underlying malignancy. In a study by Schwartz et al. aiming to identify patients with PE without DVT, those with no identifiable source (no evidence of upper or lower limb DVT) had a statistically significant increased prevalence of malignancy (67% vs. 40%, $P = .046$).³⁰ Although the absence of DVT itself does not necessarily mean that the thrombus was formed in the lungs (the thrombus might have already embolized from a distal DVT or emboli might have arisen from a central venous catheter), active search for a lower limb thrombus with ultrasound Doppler screening to identify patients at high risk for thrombosis may not always be rewarding. Similarly, in COVID-19, the thrombo-inflammatory process that commences in the lungs would cause pulmonary thrombi at least in the initial stages and surveillance Doppler imaging for DVT may not serve as surrogate for pulmonary thrombi.³¹ A recent meta-analysis identified that a high proportion of thrombotic events in COVID-19 patients are likely to be secondary to pulmonary artery occlusion by thrombi, rather than emboli from peripheral vein thrombi.³² In both COVID-19 and malignancies, there is marked activation of coagulation, which increases thrombotic risk anywhere in the circulatory system and not exclusively in the lower limb veins. The key trigger for thrombosis here is the aggressiveness of the underlying malignancy or the degree of inflammation in COVID-19. Not surprisingly, depending on the severity of the underlying disease, DVT can develop in either of these cases, if the patient becomes less mobile (in a critical care setting) and has local vessel damage from lines or surgical interventions or indeed as part of extensive coagulation activation.^{2,33}

3.2 | Pulmonary emboli or pulmonary filling defects?

Incidental pulmonary emboli (IPE) is a recently defined term with the increasing use of highly sophisticated computed tomography (CT)

scans. These incidental pulmonary “thrombi” are often detected in patients with cancer and critically ill patients.³⁴ But radiological examination cannot conclusively determine whether these constitute a bland embolus, or they may be tumor thrombi. Anatomical distribution of the human circulatory system has positioned lungs as a very effective filter by having all the systemic venous blood tracking to the pulmonary circulation prior to being oxygenated. It can play one of the crucial non-respiratory roles by filtering out thrombus material, fibrin clumps, and possibly other exogenous materials from the venous circulation.³⁵ The tendency for cancers to disseminate means that cancer particulate matter may escape into the venous circulation and may get lodged in the narrow-lumen pulmonary microcirculation.³⁶ These tumor emboli are not thrombotic in nature and thus reporting them as thrombo-emboli may not be correct. CT reports should ideally term them pulmonary filling defects rather than PE. This distinction between tumor and non-tumor emboli is clinically important because while the thrombo-embolic process is best managed by anticoagulation, tumor emboli will not be treated with blood thinners.³⁷ Because platelets play a major role in tumor metastasis, tumor-platelet hetero-aggregates formed can circulate and lodge in pulmonary vasculature and can mimic tumor thrombi.³⁸ In the COVID-19 setting, pulmonary thrombi can start as microthrombi secondary to thrombo-inflammation.³⁹ These filling defects caused by microthrombi may not be adequately treated by anticoagulant drugs explaining failure of these drugs in those with severe COVID-19.^{37,39,40} Another clinical pointer in patients with “isolated” PEs is their tendency to develop arterial and venous thrombosis. Data from the START2-Register for a venous thrombo-embolic event demonstrated patients with isolated PE to be older and female, with heart failure and cancer being significant associations.⁴¹ A high prevalence of arterial complications was noted in the isolated PE group (1.01% vs. 0.28%, $P = .008$) as well.⁴¹

3.3 | Multisystem thrombosis in the two C's

COVID-19 and different types of malignancies are associated with development of thrombosis in various circulatory beds. One Italian study of approximately 400 patients noted a high rate of venous thrombosis (7.7% of cases) but also a reasonably high number of patients with arterial thrombosis manifesting as ischemic stroke (2.5%) or acute coronary syndrome (1.1%), diagnosed within 24 h of admission.⁴² Malignancies are also associated with a high number of arterial clots similarly manifesting as coronary or cerebrovascular ischemia. An epidemiology study noted 6-month cumulative incidence of arterial thrombo-embolism to be 4.7% in patients with cancer compared to 2.2% in controls with the statistics for myocardial infarction being 2.0% versus 0.7% and that for ischemic stroke being 3.0% compared to 1.6% in cancer patients versus controls, respectively.⁴³ The new kids on the block anticancer therapy, immune checkpoint inhibitors, also are associated with a substantial risk of venous and arterial thrombo-embolism (cumulative incidences of venous and arterial thromboses were 12.9% [95% CI: 8.2–18.5] and 1.8% [95% CI: 0.7–3.6]).⁴⁴

The multisystem thrombosis would once again point to systemic coagulation activation in both the C's with all three constituents of the Virchow's triad coming into play. In relation to cancer, endothelial damage is caused by the tumor itself, chemotherapeutic agents, surgical interventions, and radiotherapy procedures, and stasis can occur from compression of vessels and immobility following surgery and general weakness and hypercoagulability from cancer procoagulants.⁴⁵ In COVID-19, thrombo-inflammation (hypercoagulability) is currently considered the key pathogenic factor for the development of thrombosis in addition to endothelialitis (vascular damage) from direct viral invasion.⁴⁶ In addition, stasis can be caused by immobility from the extreme fatigue and enforced social isolation in mild cases and the critical illness state in the severe cases.⁴⁶ The clinical relevance of heightened awareness of multisystem thrombosis is that anticoagulant drugs may be inadequate in preventing arterial clots based on the adage that venous thrombi are caused by coagulation factors and arterial clots are caused by platelet thrombi.

3.4 | Perspectives

- Regular ultrasound screening of the lower limbs in critically ill patients may miss cases of pulmonary thrombosis.
- Pulmonary filling defects may be the appropriate terminology instead of pulmonary emboli in patients with cancer-associated thrombosis.
- Future studies with more sophisticated imaging techniques able to distinguish tumor (and non-thrombotic) emboli from thrombo-emboli would be welcome to select appropriate patients for anticoagulation.
- Arterial thrombosis is not rare in patients with systemic activation of coagulation and preventive strategies may need to include additional therapeutic measures to anticoagulants (e.g., antiplatelets and anti-inflammatory/antineoplastic agents).

4 | FAILURE OF ANTICOAGULATION

Several current trials are exploring the role of intensified anticoagulation in patients with COVID-19. Although the early publications from China showed that prophylactic anticoagulation can translate to reduced mortality in these patients, a plethora of papers was published soon after that demonstrated that prophylactic anticoagulation is not enough to prevent thrombosis in COVID-19 settings, especially in those who require critical care support.^{47–49} In the cancer context, failure of thrombo-prophylaxis was observed in a phase 2 trial of 50 hospitalized cancer patients with high risk for thrombosis (based on Padua risk score).⁵⁰ These patients were randomized to fixed-dose or weight-adjusted low molecular weight heparin regimens wherein the cumulative incidence of DVT of 22% was noted in those assigned to fixed-dose enoxaparin (40 mg daily) compared to one incidentally identified pulmonary embolus in the

weight-adjusted enoxaparin (1 mg/kg daily) group.⁵⁰ A similar failure of anticoagulation is not uncommonly reported in patients with many cancers, especially when they are aggressive and metastatic with the pivotal CLOT study reporting up to 6% to 9% of cancer patients to develop recurrent VTE, despite anticoagulation.⁵¹ Carrier et al. reported on 70 cancer patients who developed recurrent VTE despite anticoagulation (two-thirds received low molecular weight heparin and a third on vitamin K antagonists).⁵² They used a dose escalation strategy using 20% to 25% more of the therapeutic anticoagulant and achieved considerable success although six patients (8.6%; 95% CI 4.0–17.5%) still developed a second recurrent thrombotic episode during the 3-month follow-up period.⁵² Why may anticoagulants fail in these two C's and can this failure be prevented or treated? (Table 1).

It is of course important to look at the key reasons for the resistant thrombosis in these cases. Anticoagulant drugs would only “work” on the hypercoagulability aspect of the Virchow's triad and possibly the endothelial dysfunction (only the heparins). If the principal trigger for thrombosis in COVID-19 is the uncontrolled inflammation driving immuno-thrombosis and in malignancies, the cancer procoagulant particles, they are unlikely to be “cleared” by the anticoagulant drugs. It may also be said that these two pathophysiological processes are not mitigated by intensified anticoagulation either despite heparins possibly exhibiting anti-inflammatory properties and at least theoretically anti-cancer properties.^{53,54} Thus, in severe cases of the two C's—COVID-19 patients who require critical care support and the patients with aggressive or metastatic cancer disease, higher doses of heparin may not be the answer while

combination therapies may be, subject to randomized trials. These adjuvant therapies could include anti-inflammatory agents; anti-neoplastic drugs; anti-complement drugs; and in cases of low bleeding risk, antiplatelet agents (see Figure 2).

4.1 | Perspectives

- More research is needed to understand the exact mechanisms of thrombosis in the two C's, which would help identify therapeutic strategies.
- Interesting research prospects in this context are whether early commencement of anticoagulant therapy (heparins) at prophylactic doses may decrease the thrombotic risk in the two C's due to their possible anti-inflammatory, endothelial quiescent, and anti-neoplastic effects.
- Whether direct oral anticoagulants have a heparin-like non-anticoagulant role would be worth exploring, although the absence of protection displayed by patients with COVID-19 recently is disappointing.⁵⁵

5 | CONCLUSION

In summary, the two C's, cancer and COVID-19, share some unique clinical and laboratory features that open more questions about the pathophysiological roles of hemostasis and thrombosis in inflammatory and neoplastic diseases. D-dimers may prove to be a

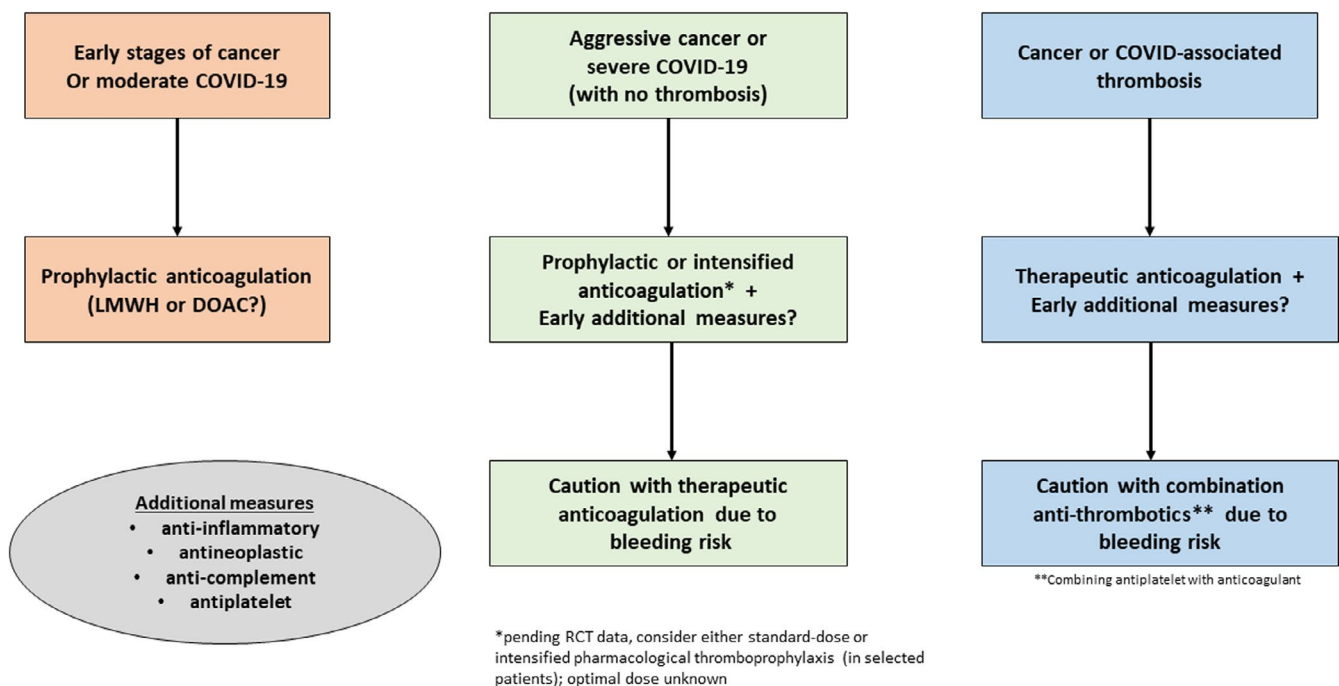


FIGURE 2 A suggested algorithm for management of thrombosis in patients with COVID-19 and cancer. The first two sections are for patients who do not have clinical evidence of thrombosis but have increased risk for thrombosis. DOAC, direct oral anticoagulants; LMWH, low molecular weight heparin; RCT, randomized controlled trial

non-thrombotic marker in these conditions both for prognosis and as a measure of therapeutic success. In the case of radiological imaging, distinguishing thrombotic and non-thrombotic filling defects in the lung vasculature may aid in choosing appropriate therapies while an open mind in cases of systemic coagulation activation and their underlying triggers may give us more effective antithrombotic strategies in cancer and inflammatory conditions.

CONFLICTS OF INTEREST

JT has received honoraria from BMS-Pfizer, Bayer, Boehringer, Daichii, and Leo Pharma. AK has received grant fees or consulting fees or honoraria from NIH, CDC, Leap, BMS, Celgene, Merck, Janssen, Bayer, Pfizer, Anthos, Sanofi, BMS, Seagen, and Medscape. MC reports grants and personal fees from Leo Pharma, grants and personal fees from BMS, grants and personal fees from Pfizer, personal fees from Bayer, personal fees from Servier, and personal fees from Sanofi, outside the submitted work.

AUTHOR CONTRIBUTIONS

JT conceived the paper and wrote the first draft. AK and MC critically reviewed the manuscript and gave comments. All authors approved the final manuscript.

REFERENCES

- Thachil J, Longstaff C, Favaloro EJ, et al. The need for accurate D-dimer reporting in COVID-19: communication from the ISTH SSC on fibrinolysis. *J Thromb Haemost.* 2020;18(9):2408-2411.
- Thachil J, Juffermans NP, Ranucci M, et al. ISTH DIC subcommittee communication on anticoagulation in COVID-19. *J Thromb Haemost.* 2020;18(9):2138-2144.
- White D, MacDonald S, Bull T, et al. Heparin resistance in COVID-19 patients in the intensive care unit. *J Thromb Thrombolysis.* 2020;50(2):287-291.
- Thachil J, Lippi G, Favaloro EJ. D-Dimer testing: laboratory aspects and current issues. *Methods Mol Biol.* 2017;1646:91-104.
- Oliver M, Goubran M, Karathra J, Karkhaneh M, Wu CM. A retrospective review of the appropriateness of D-dimer ordering and interpretation using wells' clinical probability criteria. *Blood.* 2020;136(1):28-29.
- Favaloro EJ, Thachil J. Reporting of D-dimer data in COVID-19: some confusion and potential for misinformation. *Clin Chem Lab Med.* 2020;58(8):1191-1199.
- Huang C, Wang Y, Li X, et al. Clinical features of patients infected with 2019 novel coronavirus in Wuhan, China. *Lancet.* 2020;395(10223):497-506.
- Tang N, Li D, Wang X, Sun Z. Abnormal coagulation parameters are associated with poor prognosis in patients with novel coronavirus pneumonia. *J Thromb Haemost.* 2020;18(4):844-847.
- Zhou F, Yu T, Du R, et al. Clinical course and risk factors for mortality of adult inpatients with COVID-19 in Wuhan, China: a retrospective cohort study. *Lancet.* 2020;395(10229):1054-1062.
- Zhang L, Yan X, Fan Q, et al. D-dimer levels on admission to predict in-hospital mortality in patients with Covid-19. *J Thromb Haemost.* 2020;18(6):1324-1329.
- Lippi G, Favaloro EJ. D-dimer is associated with severity of coronavirus disease 2019: a pooled analysis. *Thromb Haemost.* 2020;120(5):876-878.
- Thachil J. All those D-dimers in COVID-19. *J Thromb Haemost.* 2020;18(8):2075-2076.
- Busso N, Hamilton JA. Extravascular coagulation and the plasminogen activator/plasmin system in rheumatoid arthritis. *Arthritis Rheum.* 2002;46(9):2268-2279.
- Medcalf RL, Keragala CB, Myles PS. Fibrinolysis and COVID-19: a plasmin paradox. *J Thromb Haemost.* 2020;18(9):2118-2122.
- Thompson BT, Chambers RC, Liu KD. Acute respiratory distress syndrome. *N Engl J Med.* 2017;377(6):562-572.
- Wagers SS, Norton RJ, Rinaldi LM, et al. Extravascular fibrin, plasminogen activator, plasminogen activator inhibitors, and airway hyperresponsiveness. *J Clin Invest.* 2004;114:104-111.
- Weinberg JB, Phippen AM, Greenberg CS. Extravascular fibrin formation and dissolution in synovial tissue of patients with osteoarthritis and rheumatoid arthritis. *Arthritis Rheum.* 1991;34(8):996-1005.
- Idell S, James KK, Levin EG, et al. Local abnormalities in coagulation and fibrinolytic pathways predispose to alveolar fibrin deposition in the adult respiratory distress syndrome. *J Clin Invest.* 1989;84(2):695-705.
- Carsana L, Sonzogni A, Nasr A, et al. Pulmonary post-mortem findings in a series of COVID-19 cases from northern Italy: a two-centre descriptive study. *Lancet Infect Dis.* 2020;20(10):1135-1140.
- Polak SB, Van Gool IC, Cohen D, von der Thüsen JH, van Paassen J. A systematic review of pathological findings in COVID-19: a pathophysiological timeline and possible mechanisms of disease progression. *Mod Pathol.* 2020;33(11):2128-2138.
- Trimaille A, Thachil J, Marchandot B, et al. D-Dimers level as a possible marker of extravascular fibrinolysis in COVID-19 patients. *J Clin Med.* 2020;10(1):E39.
- Coussens LM, Werb Z. Inflammation and cancer. *Nature.* 2002;420(6917):860-867.
- Dvorak HF. Tumors: wounds that do not heal. Similarities between tumor stroma generation and wound healing. *N Engl J Med.* 1986;315(26):1650-1659.
- Dvorak HF, Nagy JA, Berse B, et al. Vascular permeability factor, fibrin, and the pathogenesis of tumor stroma formation. *Ann N Y Acad Sci.* 1992;667:101-111.
- Feng D, Nagy JA, Hipp J, Dvorak HF, Dvorak AM. Vesiculo-vacuolar organelles and the regulation of venule permeability to macromolecules by vascular permeability factor, histamine, and serotonin. *J Exp Med.* 1996;183:1981-1986.
- Dvorak HF, Senger DR, Dvorak AM, Harvey VS, McDonagh J. Regulation of extravascular coagulation by microvascular permeability. *Science.* 1985;227(4690):1059-1061.
- McMahon B, Kwaan HC. The plasminogen activator system and cancer. *Pathophysiol Haemost Thromb.* 2008;36(3-4):184-194.
- Senger DR, Galli SJ, Dvorak AM, Perruzzi CA, Harvey VS, Dvorak HF. Tumor cells secrete a vascular permeability factor that promotes accumulation of ascites fluid. *Science.* 1983;219(4587):983-985.
- Kearon C. Natural history of venous thromboembolism. *Circulation.* 2003;107(23 Suppl 1):I22-I30.
- Schwartz T, Hingorani A, Ascher E, et al. Pulmonary embolism without deep venous thrombosis. *Ann Vasc Surg.* 2012;26(7):973-976.
- Thachil J, Srivastava A. SARS-2 coronavirus-associated hemostatic lung abnormality in COVID-19: is it pulmonary thrombosis or pulmonary embolism? *Semin Thromb Hemost.* 2020;46(7):777-780.
- Birocchi S, Manzoni M, Podda GM, Casazza G, Cattaneo M. High rates of pulmonary artery occlusions in COVID-19. A meta-analysis. *Eur J Clin Invest.* 2021;51(1):e13433.
- Jonmarker S, Hollenberg J, Dahlberg M, et al. Dosing of thromboprophylaxis and mortality in critically ill COVID-19 patients. *Crit Care.* 2020;24(1):653.
- O'Connell C. How I treat incidental pulmonary embolism. *Blood.* 2015;125:1877-1882.
- Joseph D, Puttaswamy RK, Krovvidi H. Non-respiratory functions of the lung. *Cont Edu Anaesth Crit Care Pain.* 2013;13:98-102.

36. Perea Paizal J, Au SH, Bakal C. Squeezing through the microcirculation: survival adaptations of circulating tumour cells to seed metastasis. *Br J Cancer*. 2021;124(1):58-65.
37. Jorens PG, Van Marck E, Snoeckx A, Parizel PM. Nonthrombotic pulmonary embolism. *Eur Respir J*. 2009;34(2):452-474.
38. Gay LJ, Felding-Habermann B. Contribution of platelets to tumour metastasis. *Nat Rev Cancer*. 2011;11(2):123-134.
39. Hariri LP, North CM, Shih AR, et al. Lung histopathology in coronavirus disease 2019 as compared with severe acute respiratory syndrome and H1N1 influenza: a systematic review. *Chest*. 2020;S0012-3692(20):34868-34876.
40. Cattaneo M, Bertinato EM, Birocchi S, et al. Pulmonary embolism or pulmonary thrombosis in COVID-19? is the recommendation to use high-dose heparin for thromboprophylaxis justified? *Thromb Haemost*. 2020;120(8):1230-1232.
41. Palareti G, Antonucci E, Dentali F, et al. Patients with isolated pulmonary embolism in comparison to those with deep venous thrombosis. Differences in characteristics and clinical evolution. *Eur J Intern Med*. 2019;69:64-70.
42. Lodigiani C, Iapichino G, Carenzo L, Cecconi M, Ferrazzi P, Sebastian T. Venous and arterial thromboembolic complications in COVID-19 patients admitted to an academic hospital in Milan, Italy. *Thromb Res*. 2020;191:9-14.
43. Navi BB, Reiner AS, Kamel H, et al. Risk of arterial thromboembolism in patients with cancer. *J Am Coll Cardiol*. 2017;70(8):926-938.
44. Moik F, Chan WE, Wiedemann S, et al. Incidence, risk factors and outcomes of venous and arterial thromboembolism in immune checkpoint inhibitor therapy. *Blood*. 2020. <https://doi.org/10.1182/blood.2020007878>.
45. Falanga A, Schieppati F, Russo L. Pathophysiology 1. Mechanisms of thrombosis in cancer patients. *Cancer Treat Res*. 2019;179:11-36.
46. Iba T, Levy JH, Levi M, Connors JM, Thachil J. Coagulopathy of coronavirus disease 2019. *Crit Care Med*. 2020;48(9):1358-1364.
47. Tang N, Bai H, Chen X, Gong J, Li D, Sun Z. Anticoagulant treatment is associated with decreased mortality in severe coronavirus disease 2019 patients with coagulopathy. *J Thromb Haemost*. 2020;18(5):1094-1099.
48. Helms J, Tacquard C, Severac F, et al. High risk of thrombosis in patients with severe SARS-CoV-2 infection: a multicenter prospective cohort study. *Intensive Care Med*. 2020;46:1089-1098.
49. Poissy J, Goutay J, Caplan M, et al. Pulmonary embolism in patients with COVID-19: awareness of an increased prevalence. *Circulation*. 2020;142:184-186.
50. Lee AY, Levine MN, Baker RI, et al. Low-molecular-weight heparin versus a coumarin for the prevention of recurrent venous thromboembolism in patients with cancer. *N Engl J Med*. 2003;349:146-153.
51. Zwicker JJ, Roopkumar J, Puligandla M, et al. Dose-adjusted enoxaparin thromboprophylaxis in hospitalized cancer patients: a randomized, double-blinded multicenter phase 2 trial. *Blood Adv*. 2020;4(10):2254-2260.
52. Carrier M, Le Gal G, Cho R, Tierney S, Rodger M, Lee AY. Dose escalation of low molecular weight heparin to manage recurrent venous thromboembolic events despite systemic anticoagulation in cancer patients. *J Thromb Haemost*. 2009;7(5):760-765.
53. Mousa SA, Petersen LJ. Anticancer properties of low-molecular-weight heparin: preclinical evidence. *Thromb Haemost*. 2009;102:258-267.
54. Beurskens DMH, Huckriede JP, Schrijver R, Hemker HC, Reutelingsperger CP, Nicolaes GAF. The anticoagulant and nonanticoagulant properties of heparin. *Thromb Haemost*. 2020;120(10):1371-1383.
55. Lewis P, Tharp JL. Breakthrough venous thromboembolic events in five patients with COVID-19 on direct oral anticoagulants. *J Clin Pharm Ther*. 2021;46(2):519-523.

How to cite this article: Thachil J, Khorana A, Carrier M. Similarities and perspectives on the two C's—Cancer and COVID-19. *J Thromb Haemost*. 2021;19:1161-1167. <https://doi.org/10.1111/jth.15294>