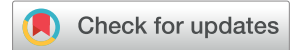



Since January 2020 Elsevier has created a COVID-19 resource centre with free information in English and Mandarin on the novel coronavirus COVID-19. The COVID-19 resource centre is hosted on Elsevier Connect, the company's public news and information website.

Elsevier hereby grants permission to make all its COVID-19-related research that is available on the COVID-19 resource centre - including this research content - immediately available in PubMed Central and other publicly funded repositories, such as the WHO COVID database with rights for unrestricted research re-use and analyses in any form or by any means with acknowledgement of the original source. These permissions are granted for free by Elsevier for as long as the COVID-19 resource centre remains active.

# Long-term follow-up of choroidal changes following COVID-19 infection: analysis of choroidal thickness and choroidal vascularity index



Mustafa Hepokur, MD, FEBO,\* Medine Gunes, MD,\*<sup>†</sup> Ebubekir Durmus, MD,\*<sup>†</sup> Veysel Aykut, MD,\*<sup>†</sup> Fehim Esen, MD, FEBO,\*<sup>†</sup> Halit Oguz, MD\*<sup>†</sup>

**Objective:** To investigate subclinical choroidal involvement in patients with systemic coronavirus disease 2019 (COVID-19) infection and evaluate its long-term course.

**Materials and Methods:** This prospective, longitudinal study included 32 eyes of 16 COVID-19 patients and 34 eyes of 17 age-matched healthy control subjects. All the participants had a detailed ophthalmologic assessment, including visual acuity assessment, slit-lamp examination, and indirect ophthalmoscopy. Enhanced depth optical coherence tomography imaging of the posterior pole and peripapillary region was performed in the early (days 15–40) and late (ninth month) postinfectious periods. Choroidal vascularity index (CVI) was calculated using ImageJ software (National Institutes of Health, Bethesda, Md.).

**Results:** None of the patients had any examination finding associated with the ocular involvement of COVID-19. Subfoveal choroidal thickness (SFCT) decreased significantly in the early postinfectious period compared with the healthy control individuals ( $p = 0.045$ ). SFCT increased significantly in the late postinfectious period compared with the early period ( $p = 0.002$ ), and the difference between patients and control individuals became statistically insignificant ( $p = 0.362$ ). There was a similar trend for the peripapillary choroidal thickness measurements. CVI remained unchanged ( $p = 0.721$ ) despite the significant decrease in SFCT and total choroidal area ( $p = 0.042$ ), indicating that this decrease occurred both in choroidal stroma and in blood vessels. CVI remained unchanged in the late postinfectious period ( $p = 0.575$ ) compared with the early period, indicating that recovery occurred in the entire choroidal tissue.

**Conclusion:** This study demonstrates that choroidal thickness was reduced in all measured areas and that this decrease affected all choroidal layers. This choroidopathy was reversible and recovered in the ninth postinfectious month.

**Objectif:** Examiner la choroïdopathie infraclinique chez des patients qui ont subi une infection à coronavirus 2019 (COVID-19) et évaluer son évolution à long terme.

**Méthodes:** Cette étude prospective longitudinale portait sur 32 yeux de 16 patients qui ont eu la COVID-19 et sur 34 yeux de 17 sujets sains témoins appariés pour l'âge. Tous les participants ont subi un examen ophtalmologique approfondi qui comprenait une évaluation de l'acuité visuelle, un examen à la lampe à fente de même qu'une ophtalmoscopie indirecte. La tomographie par cohérence optique à l'imagerie à profondeur améliorée du pôle postérieur et de la zone péripapillaire a été réalisée à 2 moments : période post-infectieuse hâtive (de 15 à 40 jours après l'infection) et période post-infectieuse tardive (9 mois après l'infection). Le logiciel ImageJ (National Institutes of Health, Bethesda, Maryland) a servi à calculer l'indice de vascularisation choroïdienne (CVI).

**Résultats:** Dans aucun cas l'examen n'a mis au jour d'atteinte oculaire liée à la COVID-19. L'épaisseur choroïdienne sous-fovéale (ECSF) a diminué significativement pendant la période post-infectieuse hâtive, comparativement à ce qui a été observé chez les témoins en bonne santé ( $p = 0,045$ ). L'ECSF a augmenté significativement pendant la période post-infectieuse tardive, comparativement à la période post-infectieuse hâtive ( $p = 0,002$ ); la différence entre les patients et les témoins est alors devenue non significative sur le plan statistique ( $p = 0,362$ ). Il s'est produit une tendance semblable en ce qui a trait aux mesures de l'épaisseur choroïdienne péripapillaire. Le CVI est demeuré le même ( $p = 0,721$ ), malgré la diminution significative de l'ECSF et de l'aire totale de la choroïde ( $p = 0,042$ ), ce qui donne à penser que la diminution a eu lieu à la fois dans le stroma choroïdien et dans les vaisseaux sanguins choroïdiens. Le CVI est demeuré le même pendant la période post-infectieuse tardive ( $p = 0,575$ ), comparativement à la période post-infectieuse hâtive, ce qui indique que le rétablissement s'est produit dans l'ensemble du tissu choroïdien.

**Conclusion:** La présente étude révèle que l'épaisseur choroïdienne décroît dans toutes les zones mesurées et que cette diminution touche l'ensemble des couches de la choroïde. Cette choroïdopathie était réversible et avait disparu 9 mois après l'infection.

A new coronavirus strain (severe acute respiratory syndrome coronavirus 2 [SARS-CoV-2]) emerged from Wuhan, China,

in December 2019 and caused a new disease called coronavirus disease 2019 (COVID-19), which was later declared as a

pandemic by the World Health Organization in March 2020.<sup>1</sup> COVID-19 is a multisystem disease that can cause respiratory, central nervous system, gastrointestinal, renal, hepatic, olfactory, and ocular involvement.<sup>2,3</sup> Although respiratory system involvement is the leading cause of mortality, hematologic complications of the disease can result in severe morbidity or even mortality.<sup>2</sup> Prolonged prothrombin time and increased D-dimer levels are relatively common findings in these patients.<sup>4</sup> There is a tendency for hematologic complications in critically ill patients, and complications such as pulmonary embolism, myocardial infarction, ischemic stroke, deep vein thrombosis, and systemic arterial embolism are encountered in this patient population more commonly.<sup>5,6</sup> Patients who develop acute respiratory distress syndrome during COVID-19 pneumonia also have a propensity for thrombotic complications compared with acute respiratory distress syndrome patients without COVID-19.<sup>7</sup> In addition to these systemic complications, this pro-thrombotic status caused by COVID-19 also can result in retinal vascular occlusions and subsequent retinal damage.<sup>1</sup>

SARS-CoV-2 enters human cells using angiotensin-converting enzyme 2 receptor, and this receptor is expressed on some of the cells in human retina, ciliary body, and choroid.<sup>8</sup> Postmortem evaluation of the retinas of COVID-19 patients revealed that SARS-CoV-2 could be isolated both from the ocular surface and from intraocular tissues such as the retina.<sup>9</sup> Human choroid consists of blood vessels, melanocytes, fibroblasts, and connective tissue.<sup>10</sup> The choroidal vessels are responsible for the oxygenation and nutrition of the outer third of the retina and photoreceptor cells.

Evaluation of the choroid is relatively difficult because it shrinks when the systemic circulation stops. Enhanced depth imaging (EDI) mode of the spectral domain optical coherence tomography (OCT) instruments allowed us to evaluate choroidal anatomy with in vivo images that are produced with this noninvasive, inexpensive, reproducible imaging method that delivers high-resolution images.<sup>11</sup> Choroidal thickness in different regions of the eye can be evaluated using these high-resolution images,<sup>12</sup> and structural properties of the choroid (such as vascularity) also can be further described with automated software analyses.<sup>13</sup>

Certain antigens of SARS-CoV-2 also have molecular similarities with certain retinal structures<sup>14</sup> and can cause thrombotic complications in ocular blood vessels.<sup>15</sup> Therefore, we suspected that there might be subclinical choroidal involvement in these patients and wanted to study long-term changes in choroidal thickness and structure following COVID-19 infection.

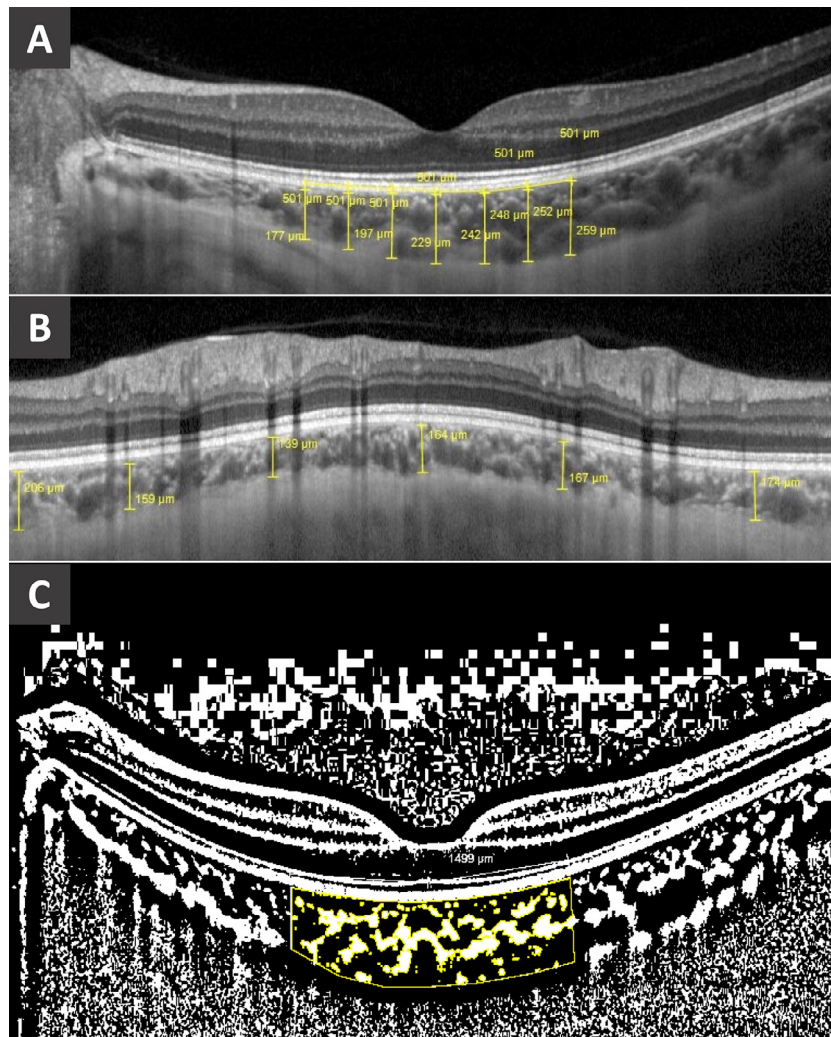
## Materials and Methods

This prospective, longitudinal study included 32 eyes of 16 health care professionals who had recovered from COVID-19 (COVID-19 group) and 34 eyes of 17 age-matched healthy control subjects (control group). All the COVID-19 patients were followed at the Istanbul Medeniyet University Göztepe Prof.Dr. Süleyman Yalçın City Hospital.

Only health care professionals who recovered from COVID-19 and did not have ocular symptoms during the disease duration were included to the study. Patients with a history of intraocular surgery, retinal disease, uveitis, retinal laser surgery for any reason, high intraocular pressure, or glaucoma were excluded from the study. Patients with ocular media opacities that prevented high-quality OCT imaging of the retina and choroid also were excluded. (Mean quality value was  $32.4 \pm 4.4$  in the COVID-19 group and  $34.9 \pm 4.4$  in the control group. Automatic real-time mode was activated during image acquisition, and each image was formed by averaging 100 frames.) Written informed consent was obtained from all patients, and the study protocol was approved by the Ethics Committee of the Istanbul Medeniyet University, Göztepe Prof.Dr. Süleyman Yalçın City Hospital (Jul. 22, 2020, no. 2020/0480). The study protocol adhered to the tenets of the Declaration of Helsinki.

The COVID-19 group was evaluated first between 15 and 40 days after the onset of the disease (early postinfectious period) and later at the ninth month after the disease (late postinfectious period). None of the patients needed hospitalization during the disease course and did not receive any anticoagulant and antiplatelet prophylaxis agents or treatment. A detailed ophthalmologic examination including measurement of intraocular pressure, central corneal thickness, axial length, best corrected visual acuity, slit-lamp examination and dilated fundus examination was performed on all participants.

After these examinations, a line image of the retina and choroid was taken in the EDI mode of a spectral domain OCT instrument (Spectralis, Heidelberg Engineering GmbH, Heidelberg, Germany). Subfoveal choroidal thickness (SFCT) was measured at 7 separate location of the image (just under the foveal centre and 500, 1000, and 1500  $\mu\text{m}$  away from the fovea on the nasal and temporal sides; Fig. 1A). A circular image with a diameter of 3.5  $\mu\text{m}$  also was taken surrounding the optic nerve head (in the retinal nerve fibre layer setup and EDI mode of the instrument), and peripapillary choroidal thickness (PPCT) was evaluated at 6 locations (nasal, superonasal, superotemporal, temporal, inferonasal, and inferotemporal; Fig. 1B). These choroidal thickness measurements were performed by two different observers (M.H. and M.G.) masked to the diagnosis of the participants. The posterior pole EDI-OCT image was further analyzed using ImageJ software (National Institutes of Health, Bethesda, Md.) for calculation of total choroidal volume and choroidal vascularity index, as described previously.<sup>16</sup> The foveal centre was located in the analysis software of the OCT instrument, and two lines (each 1500  $\mu\text{m}$ ) from the foveal centre were drawn in the temporal and nasal directions at the level of the retinal pigment epithelium (Fig. 1C). The choroidal area underlying this 3 mm region was marked using the polygon tool of the ImageJ software. The image was binarized. Total choroidal area and luminal choroidal area were calculated using the region of interest manager tool of the instrument. Luminal choroidal



**Fig. 1**—Representative images of the choroidal thickness and vascularity index analyses: (A) subfoveal choroidal thickness measured at 7 locations (one at the foveal centre, 3 in the temporal direction, and 3 in the nasal direction, each with 500  $\mu\text{m}$  intervals); (B) peripapillary choroidal thickness measured at 6 locations (nasal, superonasal, superotemporal, temporal, inferonasal, and inferotemporal); (C) choroidal vascularity index (CVI) calculated in the subfoveal choroidal area (starting from 1500  $\mu\text{m}$  nasal to fovea and ending 1500  $\mu\text{m}$  temporal to fovea); the image was binarized, and CVI calculations were made by the region of interest manager of the ImageJ software.

area was divided by the total choroidal volume to calculate the choroidal vascularity index.

Statistical analyses were performed using SPSS Statistics for Windows version 21 (IBM Corp, Chicago, Ill.). The normal distribution of the data was evaluated by performing the Shapiro–Wilk test. Data with a normal distribution were evaluated with Student’s *t* test, and data without a normal distribution were evaluated with the Mann–Whitney *U* test. Repeated measures were compared with a paired-sample *t* test for data with a normal distribution and a Wilcoxon test for data without a normal distribution. *p* Values less than 0.05 were accepted as statistically significant.

## Results

The COVID-19 group included 32 eyes of 16 patients (in the early and late postinfectious periods), and the control

group included 34 eyes of 17 healthy volunteers who did not have any history of COVID-19 infection or any other systemic disease. There was no significant difference between the COVID-19 and control groups for age and gender distribution ( $p = 0.447$  and  $p = 0.908$ , respectively). Best-corrected visual acuity, intraocular pressure, and axial length measurements also were similar between the COVID-19 and control groups ( $p = 0.303$ ;  $p = 0.196$ ; and  $p = 0.185$ , respectively). The baseline demographic and clinical characteristics of the patients and control subjects are listed in [Table 1](#).

Choroidal thickness was significantly reduced in the early postinfectious period in the COVID-19 group compared with the control group in all subfoveal locations except for  $T_{500}$ . There was also a similar trend toward decline in the  $T_{500}$  location. Choroidal thickness was measured in another retinal region to better understand structural changes in the choroid following COVID-19 infection. Choroidal



**Table 1—Demographic characteristics and ophthalmologic measurements of study groups**

Factor	COVID-19 group	Control group	p Value
Age, y	31.43 ± 9.29	28.00 ± 5.77	0.447*
Sex (M/F)	5/11	5/12	0.908 <sup>†</sup>
BCVA (decimal)	0.98 ± 0.08	1.00	0.303*
IOP, mm Hg	15.71 ± 2.51	14.97 ± 2.98	0.196*
CCT, μm	546.33 ± 26.71	542.42 ± 40.23	0.868*
Axial length	24.04 ± 0.83	23.76 ± 0.95	0.185*

BCVA, best-corrected visual acuity; IOP, intraocular pressure; CCT, central corneal thickness.

\*Mann–Whitney U test.

<sup>†</sup>Chi-square test.

thickness measurements of the peripapillary region confirmed the above-mentioned observations and was significantly reduced in the superotemporal and temporal regions ( $p = 0.020$  and  $p = 0.017$ , respectively) in the COVID-19 group in the early postinfectious period, whereas there was also an insignificant trend toward decline in the remaining regions for PPCT. The difference in SFCT and PPCT results between the COVID-19 and control groups became statistically insignificant in the late postinfectious period, whereas an insignificant trend toward reduced choroidal thickness remained at most of the studied regions in the COVID-19 group. Detailed analysis of choroidal thickness changes between the COVID-19 and control groups are given in Table 2.

Longitudinal comparative analysis of the structural changes also was performed to better understand COVID-19-associated choroidopathy. The choroidal structure normalized in the late postinfectious period by significantly increasing in all studied regions compared with the early postinfectious period. A similar change also was observed in the peripapillary region, and the PPCT became significantly thickened in the late postinfectious period compared with

the early postinfectious period. A detailed comparative analysis of the choroidal thickness changes between the early and late postinfectious periods is given in Table 2.

The above-mentioned data indicated a decrease in the early postinfectious period following COVID-19 infection that normalized in the long term. The choroidal vascularity index (CVI) of the patients was further analyzed to better understand which structures of the choroid were affected by this temporary choroidopathy. The COVID-19 group had significantly reduced total choroidal area compared with the control group ( $p = 0.042$ ) in the early postinfectious period, and this difference became statistically insignificant in the late postinfectious period ( $p = 0.055$ ; Fig. 2A). The CVI was similar between the COVID-19 and control groups in the early postinfectious period ( $p = 0.721$ ) and remained unchanged in the late postinfectious period ( $p = 0.575$ ; Fig. 2B).

## Discussion

This study demonstrated a decrease in choroidal thickness in the early postinfectious period of COVID-19 infection. This decrease included both choroidal stroma and blood vessels, and the CVI remained unchanged in these patients. In the late postinfectious period, choroidal thickness started to normalize and became significantly thicker than in the early postinfectious period. The CVI remained unchanged despite significant choroidal thickening in the late postinfectious period. These data indicate that this structural recovery of the choroid occurs in both choroidal stroma and blood vessels at the same time.

COVID-19 patients have a high incidence of thromboembolic complications, especially in severe cases.<sup>5,6</sup> The primary factor responsible for these coagulation disorders is believed to be an indirect effect of the inflammatory disorder induced by the infection rather than a direct effect of SARS-CoV-2.<sup>17</sup>

**Table 2—Choroidal thicknesses of the study groups and long-term changes of the COVID-19 group**

Choroidal thickness	Early postinfectious period	Late postinfectious period	Control group	P <sub>1</sub>	P <sub>2</sub>	P <sub>3</sub>
<b>Subfoveal</b>						
T <sub>1500</sub>	301.28 ± 60.00	326.60 ± 50.19	341.32 ± 86.58	0.034*	0.009 <sup>§</sup>	0.462 <sup>‡</sup>
T <sub>1000</sub>	302.90 ± 59.01	336.17 ± 53.07	339.94 ± 85.59	0.044*	<0.001 <sup>‡</sup>	0.833*
T <sub>500</sub>	307.96 ± 61.43	336.60 ± 62.88	338.26 ± 88.26	0.113*	0.001 <sup>‡</sup>	0.934*
SFCT	309.65 ± 68.05	330.10 ± 67.26	347.94 ± 82.58	0.045*	0.002 <sup>‡</sup>	0.362*
N <sub>500</sub>	290.15 ± 66.54	321.03 ± 79.55	335.91 ± 82.33	0.016*	0.005 <sup>‡</sup>	0.475*
N <sub>1000</sub>	271.37 ± 69.27	305.14 ± 76.60	317.88 ± 83.00	0.016*	<0.001 <sup>‡</sup>	0.536*
N <sub>1500</sub>	252.28 ± 73.36	291.25 ± 90.60	289.08 ± 74.31	0.026 <sup>†</sup>	<0.001 <sup>§</sup>	0.918*
<b>Peripapillary</b>						
Nasal	189.00 ± 64.81	198.50 ± 53.20	231.20 ± 62.09	0.063 <sup>†</sup>	0.311 <sup>§</sup>	0.308 <sup>†</sup>
Superonasal	187.15 ± 56.87	202.10 ± 61.96	217.11 ± 65.44	0.076 <sup>†</sup>	0.049 <sup>§</sup>	0.305 <sup>†</sup>
Superotemporal	187.46 ± 56.59	196.42 ± 51.41	220.58 ± 56.39	0.020*	0.370 <sup>†</sup>	0.086*
Temporal	177.37 ± 69.72	198.39 ± 66.65	216.85 ± 70.46	0.017 <sup>†</sup>	0.022 <sup>§</sup>	0.297*
Inferonasal	176.84 ± 49.30	188.53 ± 47.96	193.29 ± 65.70	0.426 <sup>†</sup>	0.218 <sup>§</sup>	0.871 <sup>†</sup>
Inferotemporal	157.75 ± 48.45	179.35 ± 53.40	186.76 ± 62.77	0.066 <sup>†</sup>	0.004 <sup>§</sup>	0.666 <sup>†</sup>

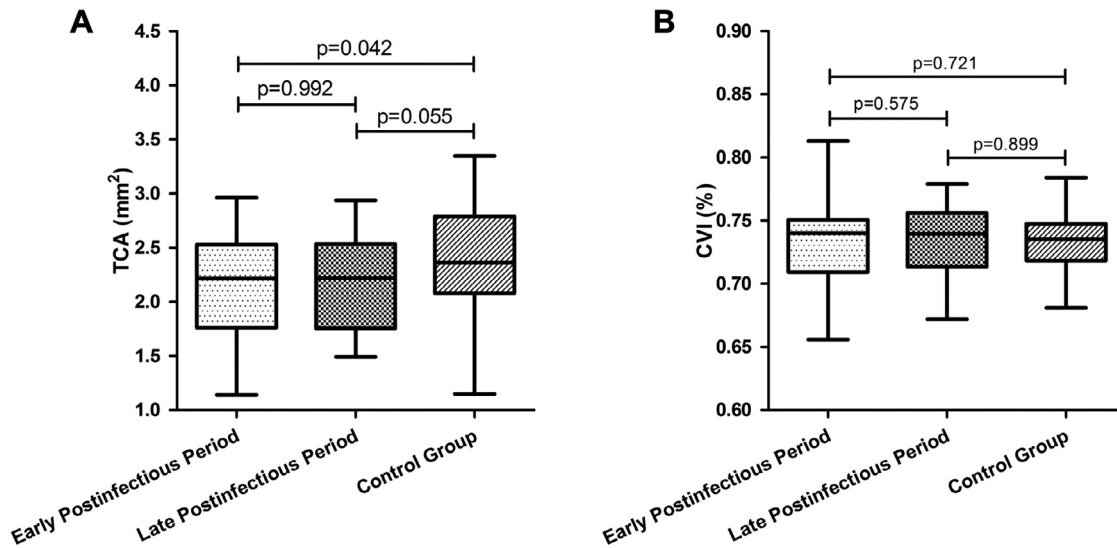
T<sub>1500</sub>, temporal 1500 μm away from foveal centre; T<sub>1000</sub>, temporal 1000 μm away from foveal centre; T<sub>500</sub>, temporal 500 μm away from foveal centre; SFCT, subfoveal choroidal thickness; N<sub>500</sub>, nasal 500 μm away from foveal centre; N<sub>1000</sub>, nasal 1000 μm away from foveal centre; N<sub>1500</sub>, nasal 1500 μm away from foveal centre.

<sup>†</sup>Independent samples t test.

<sup>‡</sup>Mann–Whitney U test.

<sup>§</sup>Paired samples t test.

<sup>¶</sup>Wilcoxon test: P<sub>1</sub>, early postinfectious period of COVID-19 group versus control group; P<sub>2</sub>, early versus late postinfectious period of COVID-19; P<sub>3</sub>, late postinfectious period of COVID-19 group versus control group.



**Fig. 2—Choroidal structural changes in the early and late postinfectious periods of COVID-19: (A) total choroidal area was significantly reduced in the early postinfectious period compared with control subjects; this difference became insignificant in the late postinfectious period; (B) the choroidal vascularity index remained unchanged in both the early and late postinfectious periods. TCA = total choroidal area; CVI = choroidal vascularity index.**

Retinal thrombotic and microvascular complications are believed to reflect the general thromboembolic complication load of the patients.<sup>18</sup> The choroid is also a potential target for such vascular complications because it is the most densely vascularized tissue in the human body. COVID-19-related retinal vascular pathologies (such as dot-blot, flame-shaped hemorrhages and retinal nerve fibre layer infarcts) were described in these patients because of the microvascular occlusions associated with the infection.<sup>1,19–23</sup> OCT angiography of COVID-19 patients demonstrated a decrease in central retinal vessel density<sup>20</sup> and reduced superficial or deep capillary plexus densities.<sup>21</sup> Roth spots, a hallmark of prothrombotic events, are also described in COVID-19.<sup>22</sup> Cotton wool spots are also believed to be a component of the acute phase of the disease (during which patients are usually quarantined and don't have access to ocular examination), and approximately 22% of these patients were reported to have cotton wool spots during the active phase of the disease.<sup>23</sup> Therefore, retinal blood vessel involvement is a relatively underdiagnosed and well-established complication of COVID-19. Some researchers even suggest that these lesions might serve as biomarkers to predict patients who have prothrombotic tendencies and will need antiaggregant treatment.<sup>23</sup> This study suggests that these ocular vascular changes in COVID-19 are not limited to the retina, and the choroid also was affected by the inflammation and prothrombotic state induced by the disease. Choroidal changes are also observed in the earlier phases of the disease and tend to resolve over time.

COVID-19 also can cause other rare ocular complication, including optic neuritis, sudden vision loss,

Miller–Fisher syndrome, and cranial neuropathies.<sup>24</sup> Optic neuritis secondary to COVID-19 is suggested to be a secondary immune reaction and not a direct vascular pathology.<sup>25</sup> The peripapillary retinal nerve fibre layer decreases after optic neuritis attacks in other diseases such as multiple sclerosis.<sup>26</sup> The prelaminar region of the optic nerve head is fed by arterioles extending from the peripapillary choroid plexus along with the posterior ciliary arteries.<sup>27</sup> OCT angiography demonstrated that radial peripapillary capillary plexus perfusion density decreased in patients with COVID-19.<sup>28</sup> Similarly, this study demonstrated a significant decrease in PPCT in the early postinfectious period after COVID-19, and this choroidal thinning recovered in the long-term follow-up of these patients. However, these peripapillary choroidal changes were asymptomatic, and none of the patients studied had any associated ocular pathology or symptom.

This study had certain limitations. The sample size of the study was relatively small but sufficient to demonstrate statistically significant changes in the choroidal structure of these patients. None of the patients in the study had severe COVID-19 infection, which might cause more vascular damage or prominent ocular involvement. All the participants were health care workers. The exposure of the health care workers to the virus might be more, and their viral load might have been higher than that of the general population infected with the disease. A strength of this study was that we started this study at the early phase of the pandemic when the role of antithrombotic prophylaxis was unknown in COVID-19 management. Therefore, none of the participants used anticoagulant or antithrombotic prophylaxis or treatment, and we could observe the natural course of the disease for the evaluation of choroidal involvement.

Indocyanine green dye is not available commercially in Turkey right now, and we were unfortunately unable to evaluate COVID-19-associated choroidopathy in these patients with indocyanine green angiography.

In conclusion, this study demonstrated the long-term evolution of choroidopathy following COVID-19 infection for the first time. Choroidal thickness and total choroidal area were reduced in the early postinfectious period of the disease, whereas the CVI remained unchanged. These findings indicate a global involvement of the choroid rather than a selective involvement of choroidal stroma or blood vessels. SARS-CoV-2 shares certain antigenic epitopes with the retinal pigment epithelium, which is in direct contact with the choroid and might induce local inflammatory damage to the choroid in these patients.<sup>14</sup> COVID-19 infection induces a very strong systemic inflammation that can cause severe cytokine storms and even death in some of the patients.<sup>29</sup> This severe systemic inflammation can potentially impair local immune privilege of the ocular structures including the choroid, and this choroidopathy might be a local reflection of this severe systemic inflammation as well. Alternatively, microvascular occlusions in the choroid may affect both the circulation of the choroidal stroma and blood vessels simultaneously. Although the exact mechanism of this choroidopathy remains to be studied, this study demonstrates that this damage is reversible. Choroidal thickness of the COVID-19 patients increased 9 months after the initial infection, and the CVI remained still unchanged at this late postinfectious period as well. These observations suggest that choroidal stroma and blood vessels recover at the same time. This study highlights certain aspects of COVID-19-related choroidopathy and long-term follow-up in these patients. This new information raises new questions. What are the risk factors for COVID-19-associated choroidopathy? Can antiaggregant/antithrombotic treatments prevent this pathology? Future clinical and experimental studies with larger sample sizes and different patient populations are required for better understanding of COVID-19-related choroidopathy.

## References

- Pereira LA, Soares LCM, Nascimento PA, et al. Retinal findings in hospitalised patients with severe COVID-19 [e-pub ahead of print]. *Br J Ophthalmol* 2020 Accessed October 16, 2020. doi: 10.1136/bjophthalmol-2020-317576.
- Lai CC, Ko WC, Lee PI, Jean SS, Hsueh PR. Extra-respiratory manifestations of COVID-19. *Int J Antimicrob Agents* 2020;56:106024.
- Hanege FM, Kocoglu E, Kalcioğlu MT, et al. SARS-CoV-2 presence in the saliva, tears, and cerumen of COVID-19 patients. *Laryngoscope* 2021;131:e1677–82.
- Terpos E, Ntanasis-Stathopoulos I, Elalamy I, et al. Hematological findings and complications of COVID-19. *Am J Hematol* 2020;95:834–47.
- Klok FA, Kruip M, van der Meer NJM, et al. Incidence of thrombotic complications in critically ill ICU patients with COVID-19. *Thromb Res* 2020;191:145–7.
- Klok FA, Kruip M, van der Meer NJM, et al. Confirmation of the high cumulative incidence of thrombotic complications in critically ill ICU patients with COVID-19: an updated analysis. *Thromb Res* 2020;191:148–50.
- Helms J, Tacquard C, Severac F, et al. High risk of thrombosis in patients with severe SARS-CoV-2 infection: a multicenter prospective cohort study. *Intensive Care Med* 2020;46:1089–98.
- Choudhary R, Kapoor MS, Singh A, Bodakhe SH. Therapeutic targets of renin-angiotensin system in ocular disorders. *J Curr Ophthalmol* 2017;29:7–16.
- Casagrande M, Fitzek A, Puschel K, et al. Detection of SARS-CoV-2 in human retinal biopsies of deceased COVID-19 patients. *Ocul Immunol Inflamm* 2020;28:721–5.
- Nickla DL, Wallman J. The multifunctional choroid. *Prog Retin Eye Res* 2010;29:144–68.
- Mrejen S, Spaide RF. Optical coherence tomography: imaging of the choroid and beyond. *Surv Ophthalmol* 2013;58:387–429.
- Karabas L, Esen F, Celiker H, et al. Decreased subfoveal choroidal thickness and failure of emmetropisation in patients with oculocutaneous albinism. *Br J Ophthalmol* 2014;98:1087–90.
- Balci S, Ozelik Kose A, Yenerel NM. The effect of optic neuritis attacks on choroidal vascularity index in patients with multiple sclerosis [e-pub ahead of print] *Graefes Arch Clin Exp Ophthalmol* 2021 Accessed March 25, 2021. doi: 10.1007/s00417-021-05143-x.
- Karagoz IK, Munk MR, Kaya M, Ruckert R, Yildirim M, Karabas L. Using bioinformatic protein sequence similarity to investigate if SARS CoV-2 infection could cause an ocular autoimmune inflammatory reactions? *Exp Eye Res* 2021;203:108433.
- Poor HD. Pulmonary thrombosis and thromboembolism in COVID-19 [e-pub ahead of print] *Chest* 2021 S0012-3692 (21)01126-0. Accessed June 18, 2021. doi: 10.1016/j.chest.2021.06.016.
- Balci S, Turan-Vural E. Evaluation of changes in choroidal vascularity during acute anterior uveitis attack in patients with ankylosing spondylitis by using binarization of EDI-optical coherence tomography images. *Photodiagn Photodyn Ther* 2020;31:101778.
- Connors JM, Levy JH. COVID-19 and its implications for thrombosis and anticoagulation. *Blood* 2020;135:2033–40.
- Chahbi M, Bennani M, Massamba N, Sandali O, Tahiri Joutei Hassani R. Mechanisms of retinal damage in patients with COVID-19. *J Fr Ophthalmol* 2020;43:e355–6.
- Lani-Louzada R, Ramos C, Cordeiro RM, Sadun AA. Retinal changes in COVID-19 hospitalized cases. *PLoS One* 2020;15:e0243346.
- Zapata MA, Banderas Garcia S, Sanchez-Moltalva A, et al. Retinal microvascular abnormalities in patients after COVID-19 depending on disease severity [e-pub ahead of print] *Br J Ophthalmol* 2020 Accessed December 16, 2020. doi: 10.1136/bjophthalmol-2020-317953.
- Abrishami M, Emamveridian Z, Shoeibi N, et al. Optical coherence tomography angiography analysis of the retina in patients recovered from COVID-19: a case-control study. *Can J Ophthalmol* 2021;56:24–30.
- Gascon P, Briantais A, Bertrand E, et al. COVID-19-associated retinopathy: a case report. *Ocul Immunol Inflamm* 2020;28:1293–7.

23. Landecho MF, Yuste JR, Gandara E, et al. COVID-19 retinal microangiopathy as an in vivo biomarker of systemic vascular disease? *J Intern Med* 2021;289:116–20.
24. Tisdale AK, Chwalisz BK. Neuro-ophthalmic manifestations of coronavirus disease 19. *Curr Opin Ophthalmol* 2020;31:489–94.
25. Sawalha K, Adeodokun S, Kamoga GR. COVID-19-induced acute bilateral optic neuritis. *J Investig Med High Impact Case Rep* 2020;8:2324709620976018 Accessed Jan-Dec 8, 2020.
26. Balci S, Yildiz MB, Ozcelik Kose A, et al. Optic nerve head changes in patients with optic neuritis secondary to multiple sclerosis: a comparison of the affected and fellow healthy eyes. *Medeni Med J* 2020;35:330–7.
27. Na KI, Lee WJ, Kim YK, Jeoung JW, Park KH. Evaluation of optic nerve head and peripapillary choroidal vasculature using swept-source optical coherence tomography angiography. *J Glaucoma* 2017;26:665–8.
28. Savastano A, Crincoli E, Savastano MC, et al. Peripapillary retinal vascular involvement in early post-COVID-19 patients. *J Clin Med* 2020;9:2895.
29. Basaran S, Simsek-Yavuz S, Mese S, et al. The effect of tocilizumab, anakinra and prednisolone on antibody response to SARS-CoV-2 in patients with COVID-19: a

prospective cohort study with multivariate analysis of factors affecting the antibody response. *Int J Infect Dis* 2021;105:756–62.

## Footnotes and Disclosure

---

The authors have no proprietary or commercial interest in any materials discussed in this article.

**Supported by:** This research did not receive any specific grant from funding agencies in the public, commercial, or not-for-profit sectors.

From the \*Ophthalmology Clinic, Göztepe Prof.Dr. Süleyman Yalçın City Hospital, Istanbul, Turkey; †Department of Ophthalmology, Istanbul Medeniyet University Medical Faculty, Istanbul, Turkey.

Originally received Apr. 29, 2021. Final revision Jun. 22, 2021. Accepted Jun. 28, 2021.

Correspondence to Mustafa Hepokur, MD, Department of Ophthalmology, Göztepe Prof.Dr. Süleyman Yalçın State Hospital, Fahrettin Kerim Gökay Cd. No:140, Kadıköy/Istanbul, 34722, Istanbul, Turkey. [hepokur34@gmail.com](mailto:hepokur34@gmail.com)