



Oral Administration and Intralesional Injection of Hyaluronic Acid Versus Intralesional Injection Alone in Peyronie's Disease: Results from a Phase III Study

Tommaso Cai¹, Daniele Tiscione¹, Vincenzo Favilla², Marco Puglisi¹, Fabrizio Palumbo³, Alessandro Zucchi^{4,*}, Gianni Malossini¹, Alessandro Palmieri⁵, Truls E. Bjerklund Johansen^{6,7}

¹Department of Urology, Santa Chiara Regional Hospital, Trento, ²Department of Urology, University of Catania, Catania, ³Department of Urology, San Giacomo Hospital, Monopoli, ⁴Department of Urology, University of Perugia, Perugia, ⁵Department of Urology, University of Naples Federico II, Naples, Italy, ⁶Department of Urology, Oslo University Hospital, Oslo, Norway, ⁷Institute of Clinical Medicine, University of Oslo and Institute of Clinical Medicine, University of Aarhus, Aarhus, Denmark

Purpose: The aim of this study was to compare the effect of combined oral administration and intralesional injection of hyaluronic acid (HA) with intralesional injections alone, in patients with early onset of Peyronie's disease (PD).

Materials and Methods: For this prospective, randomized phase III clinical trial we included patients with recent diagnosis of PD. Eighty-one patients were randomized into two groups. Group A consisted of 41 patients receiving oral administration of HA in combination with weekly intralesional injection of HA for 6 weeks. Group B consisted of 40 patients group B who received weekly intralesional injections of HA for 6 weeks, only. The main outcome measures were the changes from baseline to the end of therapy after three months in penile curvature (°) and changes in the international index of erectile function (IIEF-5) score and patient's global impressions of improvement (PGI-I) score.

Results: Group A had a significantly larger reduction in penile curvature as compared with group B (Group A: -7.8°, Group B: -4.1° [p<0.001]). Group A also showed a higher improvement in IIEF-5 and PGI-I scores in comparison with Group B (Group A: +4 IIEF-5, Group B: +2 IIEF-5 [p<0.001]; Group A: 3 PGI-I, Group B: 1 PGI-I, [p<0.001]). At three months both groups had a significant reduction of penile curvature from baseline (p<0.001).

Conclusions: Oral administration combined with intralesional treatment with HA shows greater efficacy to improve penile curvature and overall sexual satisfaction in comparison with intralesional HA treatment alone.

Keywords: Hyaluronic acid; Injections intralesional; International index of erectile function-5; Penile induration; Quality of life; Therapeutics

This is an Open Access article distributed under the terms of the Creative Commons Attribution Non-Commercial License (<http://creativecommons.org/licenses/by-nc/4.0>) which permits unrestricted non-commercial use, distribution, and reproduction in any medium, provided the original work is properly cited.

Received: Mar 25, 2020 **Revised:** Jun 25, 2020 **Accepted:** Jul 20, 2020 **Published online** Aug 14, 2020

Correspondence to: Tommaso Cai <https://orcid.org/0000-0002-7234-3526>
Department of Urology, Santa Chiara Regional Hospital, Largo Medaglie d'Oro 9, 38122 Trento, Italy.

Tel: +39-0461-903306, **Fax:** +39-0461-903101, **E-mail:** ktommy@libero.it

*Currunt affiliation: Department of Urology, University of Pisa, Pisa, Italy.

INTRODUCTION

Peyronie's disease (PD) is a challenging andrological condition characterized by the deposition of collagen and fibrin in plaques on the tunica albuginea of the penis, resulting in penile deformity, penile pain, erectile dysfunction, distress and reduced quality of life [1,2]. Due to lack of knowledge about the pathophysiology and the natural history of PD, the management is not standardized and the outcome of treatment is not optimal. There is no consensus on the best management of PD, especially in the first phase of the disease. The first phase is characterized by acute inflammation (painful erections, 'soft' nodule/plaque), and the second phase is a characterized by fibrosis and calcification with formation of hard palpable plaques (disease stabilization) as described in the European Association of Urology (EAU) guidelines [3]. About half of all patients experience a progression of the disease with a negative impact on quality of life. Based on these considerations, the most important aims of PD therapy in the acute phase are to avoid disease progression and to obtain resolution of pain and penile curvature. Clostridium collagenase is currently the only drug approved for treatment of PD by US Food and Drug Administration and European Medicines Agency, but several other options have been suggested. These include oral phytotherapy, oral pharmacotherapy, topical treatment including shockwaves, intralesional injection therapy and surgery. In the present paper we focus our attention on the use of hyaluronic acid (HA). HA is an

extracellular matrix glycosaminoglycan (GAG) which is highly polarized at physiological pH and maintains hydration, turgor, plasticity, and viscosity in the amorphous connective tissue matrix, as reported by Favilla et al [2]. Some studies on the use of injectable HA have shown encouraging results with reduction of plaque size, penile curvature, and improvement of overall sexual satisfaction [2,4,5]. Our aim was to test the efficacy of an oral administration of HA in combination with intralesional injections compared with intralesional injections alone in patients with early onset of PD.

MATERIALS AND METHODS

1. Study design and treatment schedule

Our study is a prospective, randomized phase III study. From December 2018 to December 2019, we enrolled all patients with early onset of PD in two andrological centers. Early onset of PD meant less than 12 months duration of symptoms. The two centers were randomized to give either combined oral and intralesional treatment or intralesional treatment only. Thus, all patients with early onset of PD were allocated to one of two groups. Group A: All patients attending Center A received oral administration of HA (a combination of HA, avocado and soya unsaponifiables extracts), 1 tablet every 48 hours in combination with weekly intralesional injections of HA for 6 weeks (1.6% highly purified sodium salt HA 16 mg/2 mL); Group B: All patients attending Center B received weekly intralesional injections of HA for 6 weeks, only. We decided

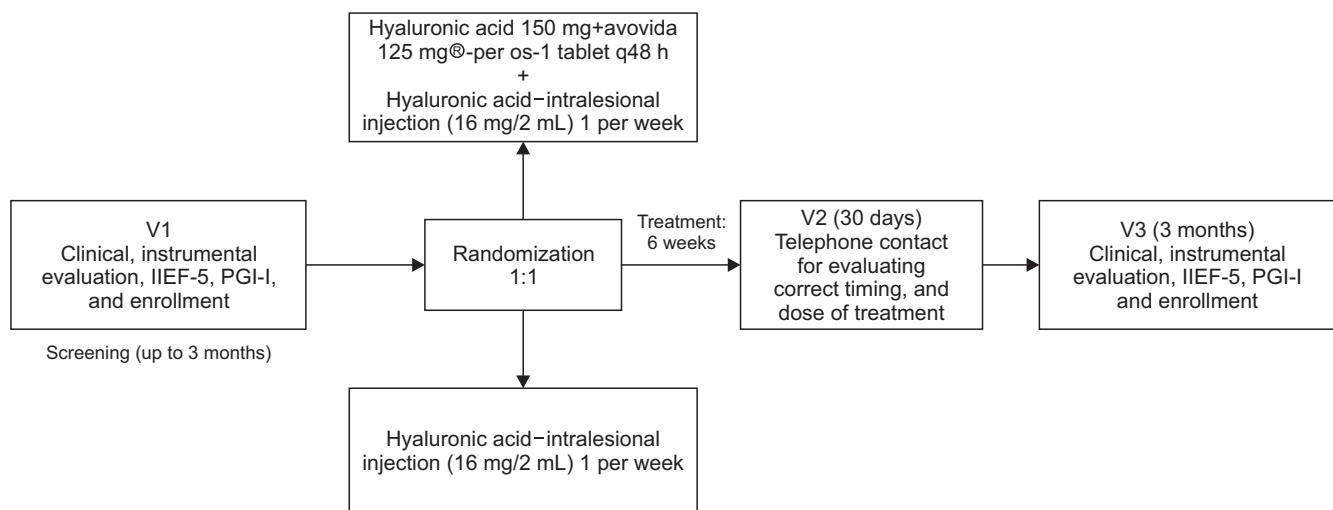


Fig. 1. The figure shows the study schedule. IIEF-5: international index of erectile function, PGI-I: patient's global impressions of improvement, per os: by mouth or orally.

to administer oral HA every 48 hours in line with the manufacturer's indication. Thirty days after initiation of treatment, all patients were contacted by phone to ensure compliance with the treatment protocol. The subsequent follow-up schedule included a urological visit with questionnaires 3 months after cessation of therapy. Fig. 1 shows the study schedule. The treatment schedule was designed on the basis of previous studies [2,5].

2. Inclusion and exclusion criteria

In this study we included men older than 18 years with clinically diagnosed acute phase of PD who were sexually active and had an international index of erectile function (IIEF-5) greater than 11. Exclusion criteria were allergy to one or more treatment compounds, inability to follow a clinical trial and follow-up evaluations and reluctance to penile injection. Any other previous treatment was also considered an exclusion criterion.

3. Composition and characterization of the drugs used

1) Oral formula of hyaluronic acid

Each oral dose contained a combination of 150 mg high molecular weight HA and 125 mg of avocado and soya unsaponifiables extracts. All patients were treated in line with the manufacturer's instructions (Anatek Health Italia s.r.l., Milan, Italy).

2) Injectable formula of hyaluronic acid

Each injection contained HA (0.8% highly purified sodium salt HA 16 mg/2 mL; Sinovial, IBSA, Lodi, Italy).

4. Clinical variables, statistical analysis and estimation of sample size

All patients underwent a clinical genitourinary examination. This included plaque location, stretched penile length and objective measurement of curvature after Doppler ultrasonography in line with EAU guidelines recommendations [3]. Penile curvature was measured using a goniometer at maximum penile rigidity. All patients were diagnosed with acute inflammatory phase of the disease with duration of symptoms less than 12 months, a soft penile nodule or plaque and/or painful erection and/or a recent change in penile curvature. One experienced urologist in each center performed all clinical and instrumental evaluations in his

center. Treatment was administered according to the randomization of the center. Doppler ultrasonography and goniometer measurement have been performed at the end of follow-up period, too. Changes in plaque size, penile curvature, and IIEF-5 score from baseline to the end of treatment were assessed and analyzed using ranked one-way analysis of variance (ANOVA) with a term for treatment group. Treatment group differences were determined using *post hoc* analysis. Data were reported as means±standard deviations or median and nominal p-values were presented. In order to obtain significant results for analysis, sample size calculation was based on the following assumptions: difference between the groups, 2±1 score points in the quality of life questionnaire; α error level, 0.05 two-sided; statistical power, 80%; anticipated effect size, Cohen's $d=0.5$. These calculations yielded 2×40 individuals per group. Considering a drop-out rate of 10%, the final total sample size was set to 90 patients. Statistical analyses were performed with IBM SPSS (Italian version) (IBM Corp., Armonk, NY, USA).

5. Main outcome measures

The main outcome measures were the change from baseline to the end of therapy in penile curvature (°) and improvements in the IIEF-5 score and patient's global impressions of improvement (PGI-I) score. Moreover, self-assessment of penile pain was measured using a visual analogue scale (VAS) ranging from 0 to 10.

6. Ethical considerations

Our study was conducted in line with Good Clinical Practice guidelines and the ethical principles laid down in the latest version of the Declaration of Helsinki (2013). Before inclusion, all participants signed a written informed consent about collection and storage of personal data in accordance with national bylaws. All anamnestic, clinical and laboratory data containing sensitive information about patients were de-identified in order to ensure analysis of anonymous data only. Non-medical staff members performed the de-identification process by means of dedicated software. The present study protocol was reviewed by Internal Review Board of Santa Chiara Regional Hospital.

RESULTS

Ninety-two patients were considered eligible for the

study. Two patients did not give consent to participate and 9 were lost during follow-up. Finally, 81 patients (mean age: 57.3±8.3 years) were included and randomized into the two groups: 41 in Group A and 40 in Group B. All patients' characteristics at baseline are detailed in Table 1.

1. Comparison between groups at follow-up evaluation

At 3 months follow-up evaluation patients in Group

Table 1. Patient's sociodemographic anamnestic, clinical characteristics at enrolment time

Variable	Group A ^b	Group B ^c	p-value
No. of enrolled patients ^a	41	40	
Median age (y)	56.2±9.1	57.9±8.6	0.39
Educational level			0.33
Primary school	-	-	
Secondary school	15 (36.6)	10 (25.0)	
Post-secondary education	26 (63.4)	30 (75.0)	
Sexually active (past mo)	41 (100)	40 (100)	>0.99
Current smoker			0.45
No	28 (68.3)	31 (77.5)	
Yes	13 (31.7)	9 (22.5)	
BMI (kg/m ²)	23.5±8.6	24.9±7.3	0.43
Charlson comorbidities index			0.67
0-1	39 (95.1)	37 (92.5)	
2	-	-	
>2	-	-	
Starting of symptoms (mo)	3.5±1.8	2.8±2	0.15
Mean penile curvature (°)	40 (30-45)	35 (27-40)	0.08
Mean plaque size (mm)	18±10	19±11	0.66
Incurvation side			
Dorsal	28 (68.3)	31 (77.5)	0.39
Right lateral	1 (2.4)	1 (2.5)	
Left lateral	3 (7.3)	-	
Right lateral-dorsal	9 (22.0)	8 (20.0)	
Plaque position			0.89
Proximal	10 (24.4)	12 (30.0)	
Medium	6 (14.6)	5 (12.5)	
Distal	25 (61.0)	23 (57.5)	
Mean IIEF-5	21 (19-23)	20 (19-23)	0.55
Mean VAS	5 (3-5)	5 (3-5)	>0.99

Values are presented as number only, mean±standard deviation, or number (%).

BMI: body mass index, IIEF-5: international index of erectile function, VAS: visual analogue scale.

^aTotal number of screened patients: 92; total number of analyzed patients: 81. ^bOral and intralesional administration hyaluronic acid.

^cIntralesional hyaluronic acid administration.

A (combined treatment) had a significantly larger penile curvature reduction than patients in Group B of -4.0°±0.7° (p<0.001) (Table 2). Patients in Group A also showed a significantly higher improvement in IIEF-5 (Group A: +4±0.3, Group B: +2±0.5; p<0.001) and PGI-I scores (Group A: 3, Group B: 1; p<0.001) in comparison with Group B (Table 2). Both groups showed a significant reduction in penile curvature from baseline (Group A: -7.8°±3.9° [p<0.001], Group B: -4.1°±2.7° [p<0.001]). A statistically significant difference has been reported in terms of VAS, too (-4.0±2, p<0.001), in the both groups between baseline and follow-up evaluation (Table 2). Finally, a statistically significant post-treatment improvements were detected in terms of plaque size in the both groups (Group A: -3.0±10 mm, Group B: -2.0±9 mm; p<0.001).

2. Protocol adherence and treatment related adverse effects

All patients adhered to the treatment protocol throughout the study period and no patients discontinued the prescribed therapy. No significant adverse effects were reported. No injection-site ecchymosis or hematomas have been reported.

Table 2. Clinical and instrumental results at the follow-up evaluation

Variable	Group A ^a	Group B ^b	Difference between the groups (p-value)
Mean penile curvature (°)			<0.001
Baseline	40 (30-45)	35 (27-40)	
Follow-up	32 (28-34)	31 (28-33)	
Difference between baseline and follow-up (p)			
Mean plaque size (mm)			<0.001
Baseline	18±10	19±11	0.34
Follow-up	15±10	17±9	
Mean IIEF-5 (range)			<0.001
Baseline	21 (19-23)	20 (19-23)	<0.001
Follow-up	24 (21-27)	22 (20-22)	
Mean VAS (range)			<0.001
Baseline	5 (3-5)	5 (3-5)	>0.99
Follow-up	1 (0-1)	1 (0-1)	
PGI-I	1±1	3±2	<0.001

Values are presented as median (range) or mean±standard deviation. Total number of patients who completed the follow-up: 81.

IIEF-5: international index of erectile function, VAS: visual analogue scale, PGI-I: patient's global impressions of improvement.

^aOral and intralesional administration hyaluronic acid. ^bIntralesional hyaluronic acid administration.

DISCUSSION

1. Main findings

This is the first prospective, randomized study evaluating the efficacy of an oral administration of HA in combination with intralesional injections compared with intralesional injections alone, in patients with early onset of PD. We found that the combination of oral administration and intralesional treatment with HA showed greater improvement in penile curvature and overall sexual satisfaction in comparison with intralesional HA treatment alone.

2. Results in the context of existing literature

For a long time, the most common treatment in the acute phase of PD has been intralesional verapamil which however, has had conflicting results [6,7]. In early stage of the disease international guidelines suggest a conservative approach with oral pharmacotherapy, topical treatments or intralesional injection therapy [3]. The high number of proposed treatments for PD and the fact that the results of studies on conservative treatment are often contradictory make it difficult to provide clear treatment recommendations. In particular, the uncertain effect of conservative treatment on the natural history of PD puts a veil of uncertainty over the treatment of early onset PD. Some authors focused their attention on HA, which is the predominant GAG in the 'amorphous ground substance' of connective tissue [2]. It consists of glucuronic acid and N-acetylglucosamine, held together by beta-glycosidic bonds. HA is present in high concentrations in the tunica albuginea and controls the distribution of nutrients in the connective tissue through its hydrating effect [3]. Some authors stated that HA counteracts interleukin (IL)-1-induced inhibition of collagen biosynthesis in cultured human chondrocytes, thereby highlighting a possible role in the management of PD [8]. Gennaro and co-workers [4], pioneered the testing of HA in PD, and could show a decrease of plaque size and penile curvature and an improved IIEF. Quite similar results were reported by Zucchi et al [5] in 2016 in a pilot study in 65 patients. Recently, Favilla et al [6] showed, in a prospective, double-arm, randomized, double-blinded study, that HA has a greater efficacy of in terms of penile curvature and patients' satisfaction when compared with intralesional verapamil. The studies by Zucchi et al [5] and Favilla et al [6] included,

as our study, only patients with an acute inflammatory phase of the disease with duration of symptoms <12 months. Their findings highlight that HA treatment should undergo further studies in patients with early onset of PD. Zucchi et al [5] used 10 weeks treatment duration, Favilla et al [6] used 12 weeks, while we used 6 weeks treatment schedule in our study. In the 2020, Cocci et al [9] reported a better outcome in terms of VAS score reduction, IIEF-5 improvement and reduction of penile curvature in patients treated with HA when compared with intralesional verapamil. We believe that the efficacy reported with our shorter treatment schedule is due to the addition of the oral administration of HA. Moreover, we used an oral administration of HA in combination with avocado and soya unsaponifiables extracts. Several *in vitro* and animal model studies demonstrated that avocado and soya unsaponifiables extracts are able to suppress IL-6, IL-8, MIP-1 β , prostaglandin E2, and to induce a significant decrease in matrix metalloproteinase (MMP)-2, MMP-3, and tissue inhibitors of MMP-1 in the presence of IL-1 β [10-12]. Moreover, Au et al [13] demonstrated that avocado and soya unsaponifiables extracts suppress the gene expression of potent proinflammatory cytokines, tumor necrosis factor alpha (TNF- α) and IL-1 β , in an LPS-stimulated monocyte/macrophage-like cell model in addition to suppressing gene expression of TNF- α , IL-1 β cyclooxygenase-2, and inducible nitric oxide synthase in cultured chondrocytes. These pharmacological effects might explain the pain relief and the improved satisfaction in our patients with early onset PD. Furthermore, we believe that avocado and soya unsaponifiables extracts may potentiate the effect of intralesional HA on the plaque size and the penile curvature.

3. Strengths and limitations of the study

We consider the selected and homogenous patient population to be study strengths. All patients had early onset of PD and no patients were previously treated for this disease. A major limitation is the lack of a control group with on-label standard therapy. We did not have access to *Clostridium histolyticum* therapy in our centers and therefore we did not include this treatment arm in the study design. The not-blinded feature of the study might be considered a study limitation. However, in each center only one arm of the study was performed. Each trialist reported the results from only one arm without any information about the other one.

Finally, future studies addressing the pharmacokinetics of oral HA are required.

CONCLUSIONS

The combination of oral administration and intralesional treatment with HA shows greater efficacy than intralesional HA treatment alone to improve penile curvature and overall sexual satisfaction in men with early onset PD. Even though further studies and larger series are needed to validate our results, this first prospective randomized trial highlights the increased potential of combined oral and intralesional HA treatment to increase quality of life for many men suffering from PD.

ACKNOWLEDGEMENTS

The authors thank all Medical and Nursing staff of Department of Urology, Santa Chiara Regional Hospital, for their clinical assistance and support for this study.

Conflict of Interest

Dr. Tommaso Cai, Dr. Alessandro Zucchi, and Dr. Alessandro Palmieri received speaker grants by IBSA, Italy, during national and international meetings but he made no influence on this work in relation with the company or its products. Other authors have no potential conflicts of interest to disclose.

Author Contribution

Conceptualization: TC, DT. Data curation: MP, FP. Methodology: TC, VF, AZ. Supervision: G, AP. Writing – original draft: TC. Writing – review & editing: TEBJ.

Data Sharing Statement

The data required to reproduce these findings cannot be shared at this time due to legal and ethical reasons.

REFERENCES

1. Brock G, Hsu GL, Nunes L, von Heyden B, Lue TF. The anatomy of the tunica albuginea in the normal penis and Peyronie's disease. *J Urol* 1997;157:276-81.
2. Favilla V, Russo GI, Zucchi A, Siracusa G, Privitera S, Cimino

3. S, et al. Evaluation of intralesional injection of hyaluronic acid compared with verapamil in Peyronie's disease: preliminary results from a prospective, double-blinded, randomized study. *Andrology* 2017;5:771-5.
4. European Association of Urology. Male Sexual Dysfunction [Internet]. Arnhem: European Association of Urology; c2014 [cited 2020 Feb 22]. Available from: <https://uroweb.org/guideline/male-sexual-dysfunction/>.
5. Gennaro R, Barletta D, Paulis G. Intralesional hyaluronic acid: an innovative treatment for Peyronie's disease. *Int Urol Nephrol* 2015;47:1595-602.
6. Zucchi A, Costantini E, Cai T, Cavallini G, Liguori G, Favilla V, et al. Intralesional injection of hyaluronic acid in patients affected with Peyronie's disease: preliminary results from a prospective, multicenter, pilot study. *Sex Med* 2016;4:e83-8.
7. Favilla V, Russo GI, Privitera S, Castelli T, Madonia M, La Vignera S, et al. Combination of intralesional verapamil and oral antioxidants for Peyronie's disease: a prospective, randomised controlled study. *Andrologia* 2014;46:936-42.
8. Shirazi M, Haghpanah AR, Badiie M, Afrasiabi MA, Haghpanah S. Effect of intralesional verapamil for treatment of Peyronie's disease: a randomized single-blind, placebo-controlled study. *Int Urol Nephrol* 2009;41:467-71.
9. Karna E, Milyk W, Pałka JA, Jarzabek K, Wołczyński S. Hyaluronic acid counteracts interleukin-1-induced inhibition of collagen biosynthesis in cultured human chondrocytes. *Pharmacol Res* 2006;54:275-81.
10. Cocci A, Di Maida F, Cito G, Verrienti P, Laruccia N, Campi R, et al. Comparison of intralesional hyaluronic acid vs. verapamil for the treatment of acute phase Peyronie's disease: a prospective, open-label non-randomized clinical study. *World J Mens Health* 2020. doi: 10.5534/wjmh.190108 [Epub].
11. Henrotin YE, Labasse AH, Jaspar JM, De Groote DD, Zheng SX, Guillou GB, et al. Effects of three avocado/soybean unsaponifiable mixtures on metalloproteinases, cytokines and prostaglandin E2 production by human articular chondrocytes. *Clin Rheumatol* 1998;17:31-9.
12. Henrotin YE, Sanchez C, Deberg MA, Piccardi N, Guillou GB, Msika P, et al. Avocado/soybean unsaponifiables increase aggrecan synthesis and reduce catabolic and proinflammatory mediator production by human osteoarthritic chondrocytes. *J Rheumatol* 2003;30:1825-34.
13. Kut-Lasserre C, Miller CC, Ejeil AL, Gogly B, Dridi M, Piccardi N, et al. Effect of avocado and soybean unsaponifiables on gelatinase A (MMP-2), stromelysin 1 (MMP-3), and tissue inhibitors of matrix metalloproteinase (TIMP-1 and TIMP-2) secretion by human fibroblasts in culture. *J Periodontol* 2001;72:1685-94.

13. Au RY, Al-Talib TK, Au AY, Phan PV, Frondoza CG. Avocado soybean unsaponifiables (ASU) suppress TNF-alpha, IL-1beta, COX-2, iNOS gene expression, and prostaglandin E2 and

nitric oxide production in articular chondrocytes and monocyte/macrophages. *Osteoarthritis Cartilage* 2007;15:1249-55.