

# Severe Pulmonary *Mycobacterium abscessus* Cases Due to Co-Infection with Other Microorganisms Well Treated by Clarithromycin and Sitafloxacin in Japan

Kazuki Takano<sup>1,2</sup>

Daishi Shimada<sup>1</sup>

Shota Kashiwagura<sup>1,3</sup>

Yasuhiro Kamioka<sup>1,3</sup>

Maya Hariu<sup>1,2</sup>

Yuji Watanabe<sup>1,2</sup>

Masafumi Seki<sup>1</sup>

<sup>1</sup>Division of Infectious Diseases and Infection Control, Faculty of Medicine,

<sup>2</sup>Laboratory for Clinical Microbiology,

<sup>3</sup>Division of Pharmacy, Tohoku Medical and Pharmaceutical University Hospital, Sendai City, Miyagi, Japan

**Background:** *Mycobacterium abscessus* frequently causes severe infections, yet its pathophysiological features and treatment regimens have not been established.

**Case Report:** We present five cases of severe pneumonia due to *Mycobacterium abscessus* infection in Japan. All cases were diabetic patients, with possible acceleration to pneumonia due to co-infection with other microorganisms. However, following a short period of hospitalization and combination therapy with intravenous imipenem/cilastatin and amikacin, all the cases were successfully treated as outpatients with oral clarithromycin and sitafloxacin.

**Conclusion:** *M. abscessus* infections can become severe in the presence of diabetes mellitus and co-infection with other chronic infectious organisms. Sitafloxacin might be a key drug in the treatment of *M. abscessus* infection in future.

**Keywords:** non-tuberculosis mycobacterium, macrolides, clarithromycin, fluoroquinolone, sitafloxacin

## Background

Globally, infections caused by non-tuberculous mycobacteria (NTM) are increasing and are notoriously difficult to treat due to intrinsic resistance of these bacteria to many common antibiotics.<sup>1</sup> Although NTM are ubiquitous and diverse in the environment, only a few species, including *Mycobacterium abscessus*, cause serious and often opportunistic infections in humans.<sup>2</sup> This rapidly growing mycobacterium is one of the most commonly identified NTM species responsible for severe respiratory, skin and mucosal infections in humans, and is frequently found in immunocompromised patients with underlying diseases and complicated co-infections.<sup>3,4</sup>

Although *M. abscessus* is usually treated with a combination of antibiotics, including macrolides, carbapenems and aminoglycosides, it is often regarded as one of the most antibiotic-resistant mycobacteria, with few therapeutic options.<sup>5</sup> Recently, some quinolones, including levofloxacin (LVFX), have demonstrated antimycobacterial activities and degrees of chemotherapeutic efficacy against certain types of mycobacterial infections, and are used as an alternative to and/or as combination agents with antimycobacterial agents, such as isoniazid, rifampicin and ethambutol, although the NTM are sometimes resistant.<sup>6,7</sup>

Correspondence: Masafumi Seki  
Division of Infectious Diseases and Infection Control, Faculty of Medicine, Tohoku Medical and Pharmaceutical University, 1-15-1 Fukumuro, Miyagino-ku, Sendai City, Miyagi, 983-8612, Japan  
Tel +81-22-259-1221  
Fax +81-22-290-8956  
Email m-seki@tohoku-mpu.ac.jp

Here, we report five cases of definite *M. abscessus*-associated pneumonia that were treated and maintained with clarithromycin (CAM) and sitafloxacin (SFTX), a novel respiratory quinolone, with all the isolated *M. abscessus* showing susceptibility to this therapy. These cases might have been exacerbated by co-infection with other microorganisms, such as *Pseudomonas aeruginosa*, *Aspergillus fumigatus*, *Staphylococcus aureus* and *Mycobacterium avium* complex (MAC). All our patients had diabetes mellitus (DM), which might have led to their immunocompromised status.

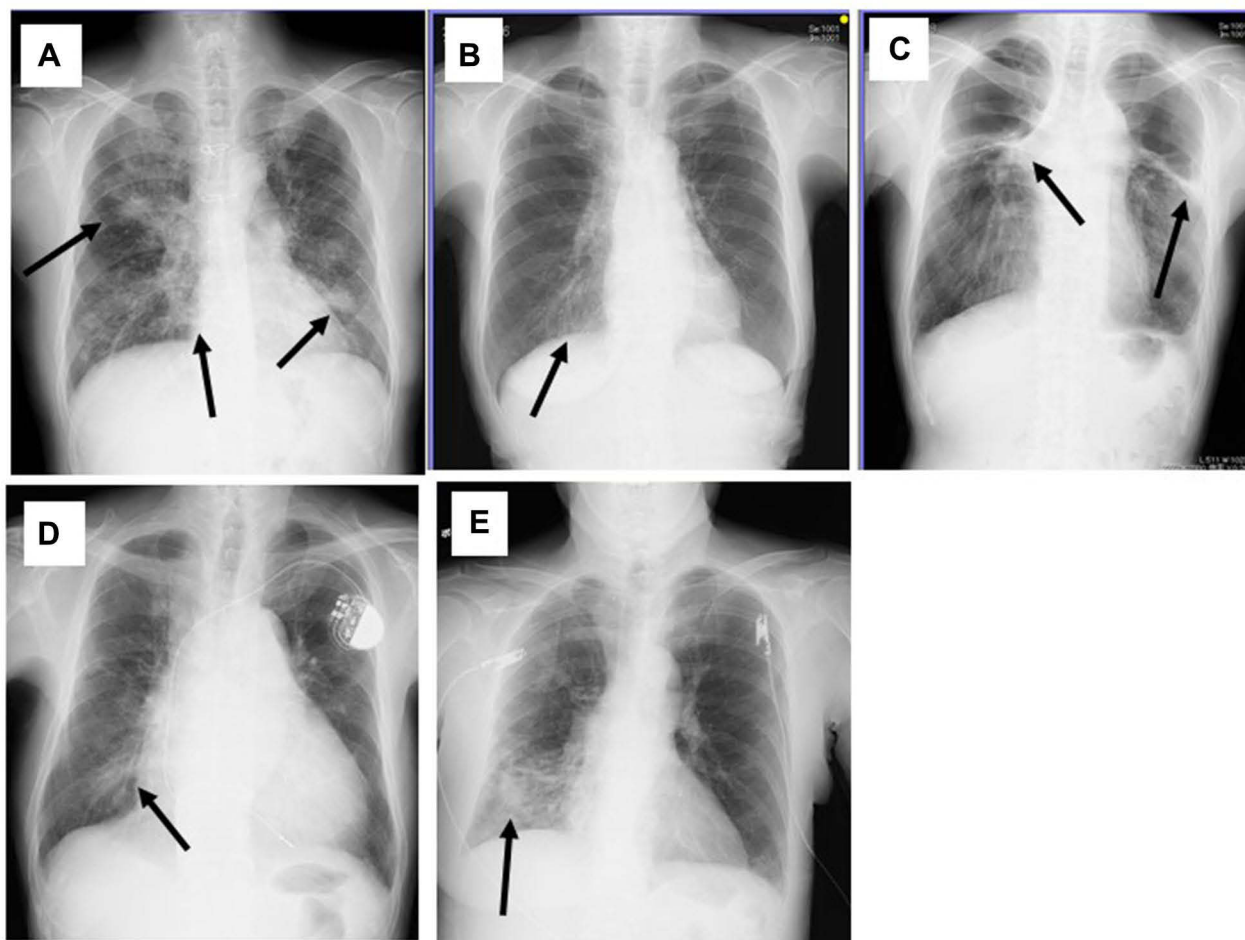
This study was approved by the Committee for Clinical Scientific Research of Tohoku Medical and Pharmaceutical University Hospital on Oct 09, 2015 (approval no. ID2015-2-028) and the patients whose specimens were used provided written informed consent to have their case details and any accompanying images published.

## Case Report

### Case 1

A 51-year-old diabetic (HbA1c: 7.1%, National Glycohemoglobin Standardization Program (NGSP)) male patient developed severe *M. abscessus* pneumonia, although he had been treated with clarithromycin (CAM) 800 mg/day, minocycline (MINO) 100 mg/day and levofloxacin (LVFX) 500 mg/day orally for three years before the bacterium was isolated (Figure 1A). His initial white blood cell (WBC) count was 11,700/L, C-reactive protein (CRP) was 18.5 mg/dL, and HbA1c was 7.8 (NGSP). *P. aeruginosa* was also isolated from his sputum.

After admission, he received CAM 800 mg/day, intravenous imipenem/cilastatin (IPM/CS) 3 g/day and amikacin (AMK) 10 mg/kg/day, with improvement in his chest radiograph findings and inflammatory markers, such as WBC count (5400/L) and CRP level (0.86 mg/dL). His clinical parameters, such as inflammation, chest X-ray, and



**Figure 1** Chest X-ray findings in the five patients. Shadows suggestive of infiltration and/or bronchiectasis were observed (arrows).

nutritional status have since been well controlled with outpatient administration of CAM 800 mg/day and SFTX 100 mg/day for a year, and *M. abscessus* has not been further isolated. Liver dysfunction and diarrhea, as side effects of SFTX, have also not occurred.

## Case 2

A 78-year-old diabetic female (HbA1c: 6.6%, NGSP) was admitted due to exacerbation of *Mycobacterium* pulmonary infection (Figure 1B). She weighed less than 40 kg and was initially suspected to have MAC infection, although *M. abscessus* was isolated by bronchoscopic analysis after three weeks. *S. aureus* was also isolated from her sputum although she had been receiving erythromycin (EM) 200 mg/day as an immune-modulatory agent, along with the anti-diabetic agent, sitagliptin phosphate hydrate 50 mg/day. Subsequently, relatively low doses of CAM 600 mg/day and SFTX 50 mg/day were started as outpatient treatment, with no further recurrences of pneumonia or *M. abscessus* isolation from sputum. Liver dysfunction and severe diarrhea did not occur and her weight increased above 40 kg.

## Case 3

A 63-year-old male with heart failure and DM (HbA1c: 6.1%, under observation without anti-diabetics), who had been receiving voriconazole 300 mg/day orally for chronic pulmonary aspergillosis, was admitted for follow-up because of exacerbation of pulmonary symptoms. He received oral LVFX 500 mg/day as outpatient therapy for pneumonia, but with no improvement. His chest x-ray worsened and *M. abscessus* was isolated from his sputum, although *A. fumigatus* was not isolated (Figure 1C). Combination therapy with CAM 800 mg/day, IPM/CS 3 g/day and AMK 10 mg/kg/day were started after admission, with significant improvement in his condition. He was effectively treated and has been maintained with CAM 800 mg/day and SFTX 100 mg/day, respectively for 6 months, with no liver dysfunction or diarrhea, and no further isolation of *M. abscessus* after SFTX commencement.

## Case 4

A 54-year-old male patient with chronic heart failure with pacemaker implantation and DM was admitted because of suspected pneumonia (Figure 1D). His initial WBC count was 6400/L, C-reactive protein (CRP) was 6.8 mg/dL, and HbA1c was 6.4% (NGSP) on sitagliptin phosphate hydrate

50 mg/day. He received LVFX 500 mg/day intravenously, with no improvement. Subsequently, *M. abscessus* and *P. aeruginosa* were isolated from his sputum twice.

We changed the antibiotic regimen to CAM 800 mg/day, intravenous IPM/CS 3 g/day and AMK 10 mg/kg/day, which resulted in improvement in his chest radiograph findings and inflammatory markers: WBC (3400/L) and CRP (1.02 mg/dL). His condition has since been well controlled with CAM 800 mg/day and SFTX 100 mg/day as outpatient treatment. Although *M. abscessus* was subsequently isolated, recurrent pneumonia and side effects were not observed.

## Case 5

A 74-year-old female patient under treatment for DM (HbA1c: 5.8%, NGSP) that was well controlled with sitagliptin phosphate hydrate 50 mg/day was admitted for sudden hemoptysis, and underwent emergency bronchial artery embolization. Her chest X-ray showed infiltrative shadows with cavity formation (Figure 1E), and *M. abscessus* was isolated from her sputum. Her serum was strongly positive for MAC antibodies (6.8 U/mL), although MAC was not isolated from sputum. We started CAM 600 mg/day and SFTX 50 mg/day therapy, and her condition has been stable since then and hemoptysis has not recurred, and with no further *M. abscessus* isolation. Her liver and gastrointestinal functions remained stable.

The *M. abscessus* isolated from all five patients had relatively high susceptibility/low minimum inhibitory concentration (MIC) to CAM, but lower susceptibility/higher MIC to IPM/CS and AMK in vitro, although all these agents were clinically effective (Table 1). For drug susceptibility analysis, the broth microdilution method was performed according to Clinical and Laboratory Standards Institute (CLSI) guidelines, using a 96-well round bottom microtiter plates kit (Kyokuto Co. Ltd. Tokyo, Japan). Briefly, the prepared MIC plates were incubated aerobically at 30°C. MICs were measured on day 3 or 4 and compared with control wells without antibiotics, showing sufficient bacterial growth.<sup>8</sup> MIC was defined as the lowest drug concentration at which bacterial growth was not visualized. The isolated organisms were resistant to most of the other antibiotics, including levofloxacin and moxifloxacin. Clofazimine and SFTX were found to be effective against the isolated *M. abscessus* strains in all five cases.

## Discussion

*M. abscessus* is the most important rapidly growing mycobacterium species; approximately 80% of chronic

**Table 1** Minimum Inhibitory Concentration (MIC) of Various Antibiotics for the *Mycobacterium abscessus* Isolated from the Five Patients

Age, M/F	AMK	TOB	IPM	FRPM	LVFX	MFLX	ST	DOXY	MEPM	LZD	CLF	SFTX	AZM	CAM
38, Female	8	16	16	64	32	4	>152/8	>16	64	4	0.5	1	0.5	0.06
51, Male	8	8	16	>64	32	>8	>152/8	>16	32	32	0.5	1	>64	>64
65, Male	16	16	8	>64	32	>8	>152/8	>16	64	32	0.5	1	2	0.125
72, Female	16	>16	16	>64	>32	4	>152/8	>16	>64	8	0.5	2	0.125	0.06
78, Female	16	16	16	>64	32	>8	>152/8	>16	>64	32	0.5	2	4	0.5

**Abbreviations:** AMK, amikacin; TOB, tobramycin; IMP, imipenem; FRPM, faropenem; LVFX, levofloxacin; MFLX, moxifloxacin; ST, Sulfamethoxazole-Trimethoprim; DOXY, Doxycycline; MEPM, Meropenem; LZD, linezolid; CLF, clofazimine; SFTX, sitafloxacin; AZM, Azithromycin; CAM, clarithromycin, respectively.

pulmonary diseases are caused by these rapid growth type mycobacteria, with the infections frequently becoming severe.<sup>2,5,9</sup>

Among our presented cases, almost all the cases were not controlled by oral antibiotics, including LVFX administered as outpatient treatment, and the patients required admission for intravenous administration of IPM/CS and AMK along with oral CAM. All five patients had DM as the underlying disease and co-infections with microorganisms in addition to *M. abscessus* infection. Our experience suggests that DM and/or co-infections might be the most important factors contributing to exacerbation of *M. abscessus* infection.

Immunocompromised patients, including those with HIV infection and some autoimmune diseases with steroid use, are known to develop severe mycobacterium infection, with disseminated infection in some cases. A 57-year-old Japanese male with Good's syndrome and myasthenia gravis, who was treated with prednisolone and tacrolimus, was reported to have disseminated NTM infection caused by *M. abscessus* subsp. *massiliense*.<sup>10</sup> He also had type 2 DM, and the correlation between an immunosuppressed status, including DM, and severe *M. abscessus* infection as an opportunistic infection was suggested. It was previously reported that non-classical monocytes from obesity-based DM and non-obese tuberculosis patients exhibit similar activation profiles (CD86/CD206/TLR-2 and TLR-4 expressions), and serum adiponectin levels increased similarly in tuberculosis and obesity-based DM patients.<sup>11</sup> The authors found that monocytes from active tuberculosis patients and obesity-based DM were more permissive to mycobacterium growth, including *M. abscessus*, than in obese individuals without DM, suggesting that a background of DM might be unfavorable in terms of controlling the mycobacterium infection.

In contrast, it was reported that DM was not a risk factor for *M. abscessus* infection among cystic fibrosis (CF) patients, although a history of *Stenotrophomonas maltophilia*, one of the representative chronic infectious bacteria, was significantly more frequent among cases than among controls, and that there might be a correlation with *A. fumigatus*, an organism commonly found in CF patients with NTM infection, or that both might be signs of advanced lung damage that predisposes to mycobacterial disease.<sup>12</sup> *A. fumigatus* was reported to worsen pulmonary inflammation and impact *M. abscessus* control in a mouse model.<sup>13</sup> Furthermore, *M. abscessus* with *P. aeruginosa* and MAC were also suggested as risk factors for *M. abscessus* infection.<sup>6,14</sup> This suggests that we should consider the co-existence of these other chronic infectious microorganisms, and treat or control them with other antibiotics, including macrolides, as immunomodulatory agents.<sup>15</sup>

CAM was one of the rare antibacterial agents used in our patients, although *M. abscessus* is intrinsically resistant to most antibacterial agents. Several studies have evaluated the efficiency of combined drug therapy in the treatment of *M. abscessus* infections according to the recommendations of guidelines, such as the treatment combining CAM, AMK, cefoxitin or IPM/CS, faropenem and linezolid (LZD).<sup>4,16,17</sup> Although these drugs are relatively well tolerated, treatment failure was still observed in about 20 to 70% of cases.<sup>18,19</sup> Although clofazimine is not available in Japan, use of inhaled amikacin, Arikayce (amikacin liposome inhalation suspension or ALIS), for refractory pulmonary NTM disease has recently been accepted.<sup>20</sup> The use of Arikayce led to negative sputum cultures for NTM by month 6 in 29% of patients compared to 8.9% of patients treated with guideline-based therapy alone. The effectiveness of Arikayce thus holds promise. However, there is limited data on Arikayce's safety in

Japanese patients. Additionally, difficulty in outpatient control has been suggested because most of the recommended drugs are not oral agents, and because of the significant side-effects, including thrombocytopenia with LZD.<sup>4</sup> Therefore, some other antimicrobial agents, including fluoroquinolones, were suggested as key agents for the long term treatment and maintenance follow up of *M. abscessus* infections.

Among the fluoroquinolones, SFTX is considered a favorable agent against *M. abscessus* because it shows high susceptibility/low MIC in contrast to the other fluoroquinolones, including LVFX.<sup>7</sup> SFTX is a novel respiratory quinolone that is reportedly often used for patients with severe *M. abscessus* infection as an alternative and/or adjunct to standard antibiotic regimens.<sup>10</sup> SFTX generally shows 2- to 16-fold higher antimicrobial effects compared with previous new quinolones, such as LVFX and ciprofloxacin.<sup>7</sup> In our cases, SFTX showed both microbiological susceptibility (Table 1) and clinical efficiency in all patients, suggesting its usefulness as outpatient treatment for *M. abscessus* infection in combination with CAM. Our cases also suggested synergistic effects between SFTX and CAM, as with d-cycloserine.<sup>8</sup> Khosravi et al analyzed 714 positive acid fast-bacilli, and found the effect of d-cycloserine was better than that of CAM. In addition, a synergistic effect of d-cycloserine with CAM was observed against six (100%) and five (71.5%) strains of *M. fortuitum* and *M. abscessus*, respectively. Unfortunately, however, we could not analyze synergistic MIC changes in our cases, and further detailed analysis is required to assess the synergistic effects of SFTX and other antibiotics.

In conclusion, we experienced five severe *M. abscessus* cases, with disease exacerbation probably due to the presence of underlying DM, and co-infection with other chronic infectious organisms, including *P. aeruginosa*, *S. aureus*, *A. fumigatus* and MAC. The patients finally improved by administration of a combination of antibiotics, including CAM and other recommended intravenous drugs. Additionally, SFTX had good clinical and microbiological efficacy in outpatients with *M. abscessus*, suggesting synergistic effects between CAM and SFTX. Thus, SFTX might be a strong candidate drug in the outpatient treatment of *M. abscessus* infection not only in Japan, but also in other NTM endemic countries.

## For Review

We present five cases of severe pneumonia due to *Mycobacterium abscessus* infection in Japan. All the

patients were diabetic, with possible acceleration to pneumonia due to co-infection with other microorganisms. However, following a short period of hospitalization and combination therapy with intravenous imipenem/cilastatin and amikacin, all the cases were successfully treated as outpatients with oral clarithromycin and sitafloxacin, which might be a key drug for treatment of *M. abscessus* in future.

## Disclosure

The authors report no conflicts of interest in this work.

## References

- Johansen MD, Herrmann JL, Kremer L. Non-tuberculous mycobacteria and the rise of *Mycobacterium abscessus*. *Nat Rev Microbiol*. 2020;18:392–407. doi:10.1038/s41579-020-0331-1
- Chen J, Zhao L, Mao Y, et al. Clinical efficacy and adverse effects of antibiotics used to treat mycobacterium abscessus pulmonary disease. *Front Microbiol*. 2019;10:1977. doi:10.3389/fmicb.2019.01977
- Miyashita E, Yoshida H, Mori D, et al. Mycobacterium avium complex-associated peritonitis with CAPD after unrelated bone marrow transplantation. *Pediatr Int*. 2014;56:e96–e8. doi:10.1111/ped.12463
- Seki M, Kamioka Y, Takano K, et al. Mycobacterium abscessus associated peritonitis with CAPD successfully treated using a linezolid and tedizolid containing regimen suggested immunomodulatory effects. *Am J Case Rep*. 2020;21. doi:10.12659/AJCR.924642.
- Shen Y, Wang X, Jin J, et al. In vitro susceptibility of mycobacterium abscessus and mycobacterium fortuitum isolates to 30 antibiotics. *Biomed Res Int*. 2018;4902921. doi:10.1155/2018/4902941
- Birmes FS, Wolf T, Kohl TA, et al. Mycobacterium abscessus subsp. abscessus is capable of degrading pseudomonas aeruginosa quinolone signals. *Front Microbiol*. 2017;8. doi:10.3389/fmicb.2017.00339.
- Saito H, Tomioka H, Sato K, Dekio S. In vitro and in vivo antimycobacterial activities of a new quinolone, DU-6859a. *Antimicrob Agents Chemother*. 1994;38:2877–2882. doi:10.1128/AAC.38.12.2877
- Khosravi AD, Mirsaedi M, Farahani A, et al. Prevalence of non-tuberculous mycobacteria and high efficacy of d-cycloserine and its synergistic effect with clarithromycin against mycobacterium fortuitum and mycobacterium abscessus. *Infect Drug Resist*. 2018;11:2521–2532. doi:10.2147/IDR.S187554
- Bostan C, Slim E, Choremis J, et al. Successful management of severe post-LASIK Mycobacterium abscessus keratitis with topical amikacin and linezolid, flap ablation, and topical corticosteroids. *J Cataract Refract Surg*. 2019;45:1032–1035. doi:10.1016/j.jcrs.2019.03.001
- Imoto W, Yamada K, Hajika Y, et al. Disseminated mycobacterium abscessus subsp. massiliense infection in a good's syndrome patient negative for human immunodeficiency virus and anti-interferon- $\gamma$  autoantibody: a case report. *BMC Infect Dis*. 2020;20. doi:10.1186/s12879-020-05136-x.
- Resende DP, da Costa AC, de Souza Rosa LP, et al. Non-classical circulating monocytes in severe obesity and obesity with uncontrolled diabetes: a comparison with tuberculosis and healthy individuals. *Tuberculosis (Edinb)*. 2019;114:30–42. doi:10.1016/j.tube.2018.11.003
- Verregghen M, Heijerman HG, Reijers M, van Ingen J, van der Ent CK. Risk factors for mycobacterium abscessus infection in cystic fibrosis patients; a case-control study. *J Cyst Fibros*. 2012;11:340–343. doi:10.1016/j.jcf.2012.01.006

13. Monin L, Mehta S, Elsegeiny W, et al. Aspergillus fumigatus pre-exposure worsens pathology and improves control of mycobacterium abscessus pulmonary infection in mice. *Infect Immun*. 2018;86. doi:10.1128/IAI.00859-17.
14. Shin SH, Jhun BW, Kim SY, et al. Nontuberculous mycobacterial lung diseases caused by mixed infection with mycobacterium avium complex and mycobacterium abscessus complex. *Antimicrob Agents Chemother*. 2018;62. doi:10.1128/AAC.01105-18.
15. Seki M, Sakata T, Toyokawa M, Nishi I, Tomono K. A chronic respiratory pasteurella multocida infection is well-controlled by long-term macrolide therapy. *Intern Med*. 2016;55:307–310. doi:10.2169/internalmedicine.55.4929
16. Daley CL, Iaccarino JM, Lange C, et al. Treatment of nontuberculous mycobacterial pulmonary disease: an Official ATS/ERS/ESCMID/IDSA clinical practice guideline: executive summary. *Clin Infect Dis*. 2020;71:e1–e36. doi:10.1093/cid/ciaa241
17. Inoue T, Tsunoda A, Nishimoto E, et al. Successful use of linezolid for refractory Mycobacterium abscessus infection: a case report. *Respir Med Case Rep*. 2017;23:43–45. doi:10.1016/j.rmc.2017.11.007
18. Jeon K, Kwon O, Lee NY, et al. Antibiotic treatment of mycobacterium abscessus lung disease: a retrospective analysis of 65 patients. *Am J Respir Crit Care Med*. 2009;180:896–902. doi:10.1164/rccm.200905-0704OC
19. Roux AL, Catherinot E, Soismier N, et al.; OMA group. Comparing mycobacterium massiliense and mycobacterium abscessus lung infections in cystic fibrosis patients. *J Cyst Fibros*. 2015;14:63–69. doi:10.1016/j.jcf.2014.07.004
20. Khan O, Chaudary N. The use of amikacin liposome inhalation suspension (Arikayce) in the treatment of refractory nontuberculous mycobacterial lung disease in adults. *Drug Des Devel Ther*. 2020;14:2287–2294. doi:10.2147/DDDT.S146111

### International Medical Case Reports Journal

Dovepress

### Publish your work in this journal

The International Medical Case Reports Journal is an international, peer-reviewed open-access journal publishing original case reports from all medical specialties. Previously unpublished medical posters are also accepted relating to any area of clinical or preclinical science. Submissions should not normally exceed 2,000 words or 4

published pages including figures, diagrams and references. The manuscript management system is completely online and includes a very quick and fair peer-review system, which is all easy to use. Visit <http://www.dovepress.com/testimonials.php> to read real quotes from published authors.

Submit your manuscript here: <https://www.dovepress.com/international-medical-case-reports-journal-journal>