

CASE REPORT

BEGINNER

CLINICAL CASE

Spontaneous Internal Mammary Artery Graft Dissection Triggered by Emotional Stress



Kosuke Sawami, MD, Masahiro Natsuaki, MD, PhD, Hiroshi Hongo, MD, Masataka Kajiwara, MD, Tetsuya Kaneko, MD, Yohei Inoue, MD, Aiko Komatsu, MD, PhD, Norihiko Kotooka, MD, PhD, Yutaka Hikichi, MD, PhD, Koichi Node, MD, PhD

ABSTRACT

Internal mammary artery graft dissection is a rare condition and is usually caused by iatrogenic complications or mechanical stress. We experienced a case of acute myocardial infarction due to spontaneous internal mammary artery graft dissection that was triggered by emotional stress and was successfully treated by percutaneous intervention using drug-eluting stents. (**Level of Difficulty: Beginner.**) (J Am Coll Cardiol Case Rep 2019;1:732-6) © 2019 The Authors. Published by Elsevier on behalf of the American College of Cardiology Foundation. This is an open access article under the CC BY-NC-ND license (<http://creativecommons.org/licenses/by-nc-nd/4.0/>).

Internal mammary artery (IMA) dissection is a rare condition and could be caused by iatrogenic complications (1,2). Therefore, there are few reports of spontaneous IMA dissection. Here, we present a case of acute myocardial infarction due to spontaneous IMA graft dissection that was triggered by emotional stress and was successfully

treated by percutaneous intervention using drug-eluting stents.

HISTORY OF PRESENTATION

A 78-year-old woman was admitted to our hospital with sudden onset chest pain immediately after receiving notice of her grandchild's death. Chest pain was relieved by oral nitroglycerin but persisted when she arrived at our hospital. She did not complain of backache or nausea. Her blood pressure on arrival was 150/87 mm Hg and her heart rate was 64 beats/min. Her heart had a regular rhythm; S1 and S2 were normal, and there were no murmurs or gallops. There was no lower extremity edema.

PAST MEDICAL HISTORY. She had been treated for hypertension and dyslipidemia by oral medications. She experienced effort angina and underwent coronary artery bypass grafting (CABG) 20 years prior with a left IMA graft to the diagonal branch and saphenous

LEARNING OBJECTIVES

- Spontaneous IMA graft dissection is one of the causes of acute coronary syndrome in patients with a previous history of CABG.
- Emotional stress as well as the mechanical stress due to physical movement is a possible trigger for spontaneous IMA graft dissection.
- Percutaneous intervention using coronary stents is one of the important treatment options in cases of spontaneous IMA graft dissection.

From the Department of Cardiovascular Medicine, Saga University, Saga, Japan. Dr. Kotooka has served as the endowed chair for Asahi-Kasei Corporation. Dr. Node has received honoraria from Ono Pharmaceutical, Takeda Pharmaceutical, Daiichi-Sankyo Healthcare, Boehringer Ingelheim Japan, Merck Sharp and Dohme, and Mitsubishi Tanabe Pharma; has received research funding from Teijin Pharma, Terumo, Mitsubishi Tanabe Pharma, Asahi-Kasei, and Astellas; and has received scholarships from Bayer Yakuhin, Daiichi-Sankyo Healthcare, and Teijin Pharma. All other authors have reported that they have no relationships relevant to the contents of this paper to disclose. Adhir Shroff, MD, served as Guest Associate Editor for this paper.

Informed consent was obtained for this case.

Manuscript received September 9, 2019; revised manuscript received September 23, 2019, accepted September 25, 2019.

vein grafts to the left anterior descending artery (LAD), left circumflex artery (LCX), and right coronary artery. The saphenous vein graft to the LCX was occluded immediately after CABG. The LCX was treated by percutaneous coronary intervention using a 2.5 × 28 mm Cypher sirolimus-eluting stent (Cordis Medical, Hialeah, Florida) owing to unstable angina 11 years prior. Furthermore, the saphenous vein graft to the LAD showed occlusion based on angiography performed 1 year prior.

DIFFERENTIAL DIAGNOSIS. Differential diagnosis included plaque rupture of the bypass graft, acute coronary syndrome due to plaque rupture, spontaneous coronary artery dissection (SCAD), very late stent thrombosis, Takotsubo cardiomyopathy, and myocarditis.

INVESTIGATIONS. The electrocardiogram showed ST-segment elevation in leads I, aVL, and V₂ to V₆ (Figure 1). The left ventricular lateral wall was hypokinetic on echocardiography. Troponin T was elevated to 1.06 ng/ml (normal <0.014 ng/ml).

MANAGEMENT

Urgent angiography showed severe stenosis at the mid portion of the left IMA graft with Thrombolysis In Myocardial Infarction flow grade 2, which was not observed 1 year prior (Figure 2). There were no significant changes in the native coronary artery. Therefore, left IMA stenosis was considered to be the culprit lesion and percutaneous intervention was selected for the treatment of this challenging case.

The left radial artery was selected as an approach site, and a 6-F Judkins Right 3.5 guiding catheter (Medtronic, Minneapolis, Minnesota) was used for the intervention. A SION blue wire (Asahi Intecc USA, Santa Ana, California) did not pass the culprit lesion due to insufficient backup. Therefore, the approach site was changed to the femoral artery, and the wire successfully advanced through the lesion. Intravascular ultrasound revealed dissection with intramural hematoma throughout the stenotic lesion (Figure 3). The intramural hematoma and dissection flap were fully stented using 2 platinum chromium SYNERGY everolimus-eluting stents (2.5 × 38 mm and 2.5 × 12 mm; Boston Scientific, Marlborough, Massachusetts). Final angiography showed good stent expansion with TIMI flow grade 3 (Figure 4).

The patient's symptoms resolved after percutaneous coronary intervention, and the serum creatine kinase increased up to 521 U/l. She was discharged from our hospital on post-operative day 9.

DISCUSSION

IMA graft dissection is considered to be very important condition because of its frequent use for LAD bypass grafting. One of the major causes of IMA graft dissection is iatrogenic complications. Shammam et al. (1) reported a case in which dissection of the IMA graft occurred during diagnostic angiography and was treated successfully with a drug-eluting stent. Spontaneous IMA graft dissection is another cause (2), and it is crucially important, as it can lead to acute coronary syndrome (3-6). Koyama et al. (7) reported spontaneous dissection of an IMA graft causing acute coronary syndrome and ventricular fibrillation. Although spontaneous IMA graft dissection is not common, we should keep in mind that it could be the cause of acute coronary syndrome or life-threatening arrhythmia in those with previous CABG.

The main cause of spontaneous IMA dissection has been reported to be associated with mechanical stress owing to physical movement (Table 1) (3,4,6). Freixa and Gallo (6) proposed that the shear stress between the chest wall and IMA triggered dissection. In this case, the patient was exposed to emotional stress

ABBREVIATIONS AND ACRONYMS

- CABG** = coronary artery bypass grafting
- IMA** = internal mammary artery
- LAD** = left anterior descending artery
- LCX** = left circumflex artery
- SCAD** = spontaneous coronary artery dissection

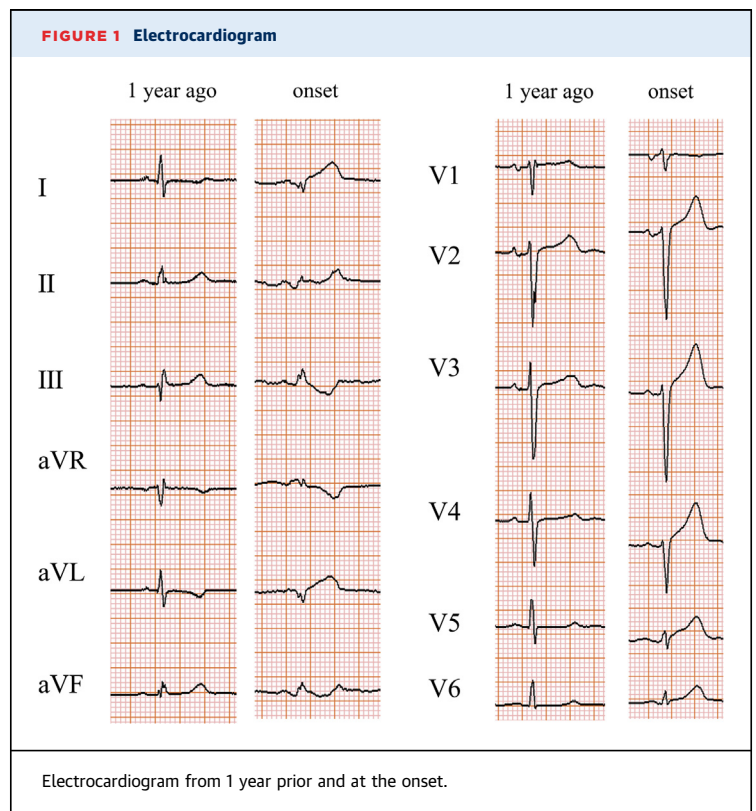


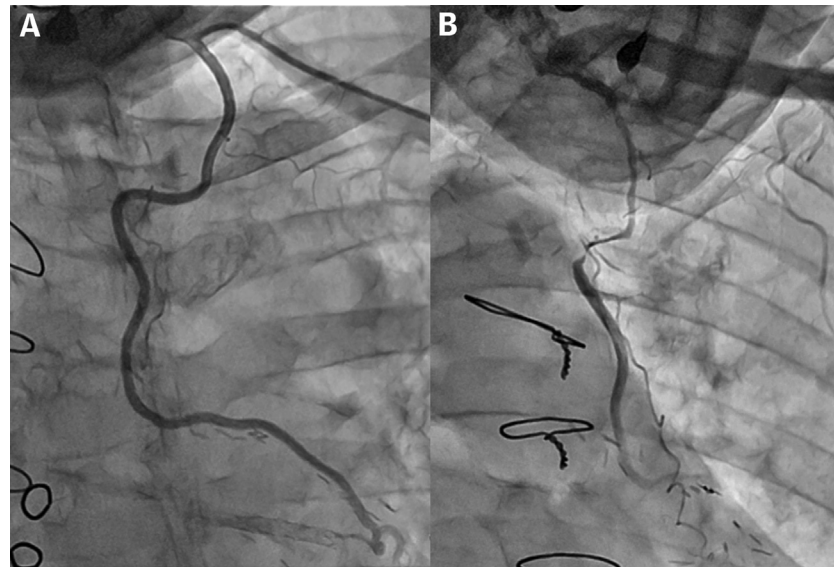
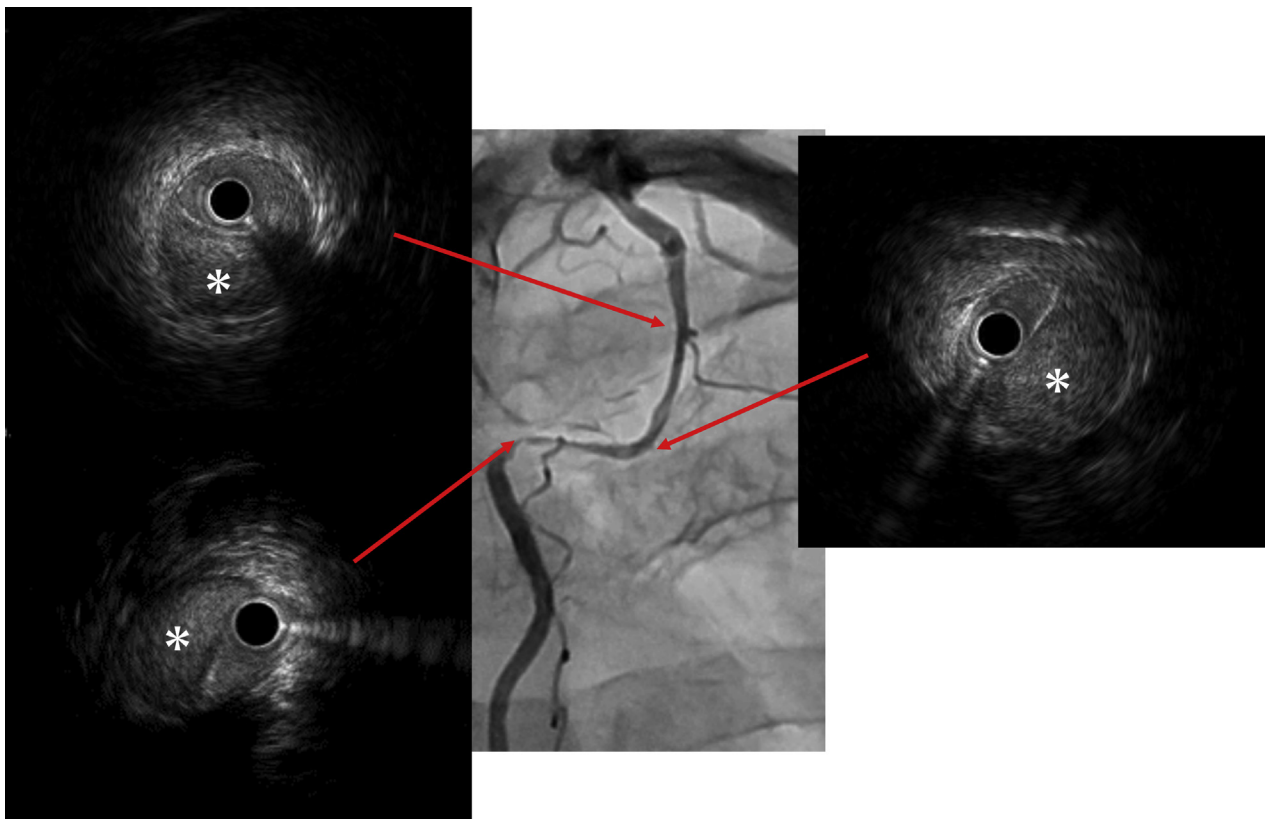
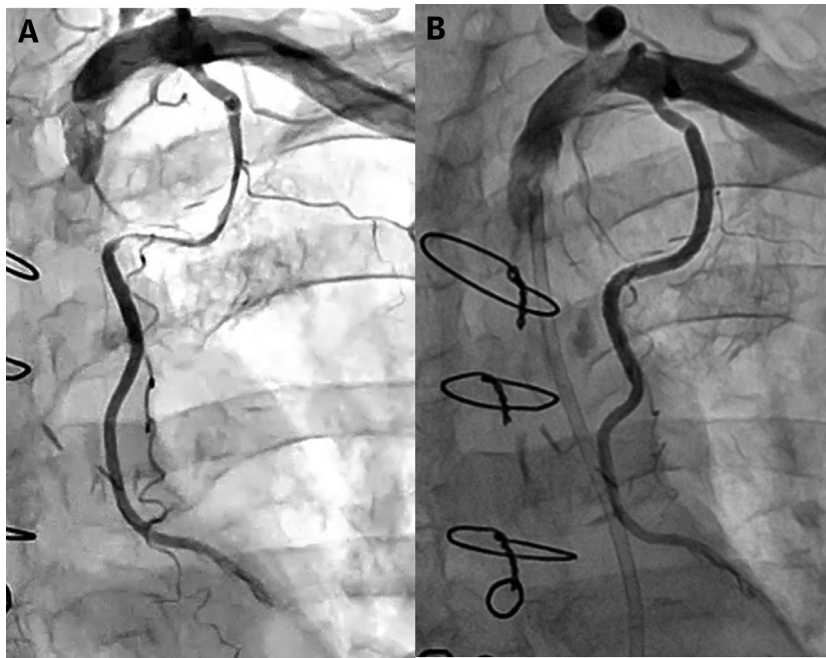
FIGURE 2 Angiography of the IMA Graft**(A)** Internal mammary artery (IMA) angiography from 1 year ago. **(B)** IMA graft angiography at the onset with Thrombolysis In Myocardial Infarction flow grade 2.**FIGURE 3** Intravascular Ultrasound FindingsAngiography and intravascular ultrasound findings. **Asterisks** show intramural hematoma.

FIGURE 4 Angiography of the IMA Graft



(A) Internal mammary artery (IMA) graft angiography before percutaneous coronary intervention. **(B)** IMA graft angiography after percutaneous coronary intervention with Thrombolysis In Myocardial Infarction flow grade 3.

upon notification of her grandchild's death, and then chest pain occurred. It is possible that emotional stress could have been the cause of IMA dissection in this case. Emotional stress is reported to be a major trigger of SCAD (8). Stress catecholamines could increase the arterial shear stress, resulting in dissection (9). The same mechanism may have caused dissection of the IMA in this case.

On the one hand, a conservative strategy is mostly selected in cases of SCAD. Only 14% of patients had percutaneous coronary intervention in the Canadian SCAD cohort study (8). On the other hand, percutaneous intervention using coronary stents is the major treatment strategy for IMA dissection (Table 1) (3,4,6,7). Percutaneous intervention to the IMA is usually challenging because of the acute angle, tortuous course, and small lumen of the IMA. However, balloon angioplasty and stenting of IMA is reported to be safe and effective (10). Although the prior report did not refer to dissection cases, percutaneous intervention could be a valuable treatment option to treat flow-limited IMA dissection cases, considering the risk of reoperation in those with

previous CABG. Nevertheless, the dilemma of whether to perform intervention or not remains in the spontaneous IMA dissection. As there was no evidence of any disease 1 year prior, the dissected IMA could have been healed completely without intervention. Furthermore, there is a risk of propagating dissection by the wiring to the false lumen. In this case, intervention was selected due to the ongoing chest pain and flow limitation of IMA. Arrhythmias or hemodynamic instability could also be

TABLE 1 Reported Cases of Spontaneous IMA Dissection

First Author (Ref. #)	Year	Age (yrs)	Sex	Trigger	Treatment
Wong et al. (3)	2004	69	M	Digging up a postbox	4 stents
Suresh and Evans (4)	2007	75	M	Lifting a heavy bookcase	Multiple stents
Karabulut and Tanriverdi (5)	2011	59	F	Kinking of the IMA	CABG
Freixa and Gallo (6)	2013	61	M	Raising arms	3 stents
Koyama et al. (7)	2015	47	M	No specific trigger	2 stents
Current case	2019	78	F	Emotional stress	2 stents

CABG = coronary artery bypass grafting; IMA = internal mammary artery.

the indication of intervention for spontaneous IMA dissection.

This case uniquely demonstrates emotional stress as a possible trigger of IMA graft dissection and complements previous case reports demonstrating the role of percutaneous intervention in its management.

FOLLOW-UP. The patient did well at 1 month of follow-up in our hospital. Echocardiography showed left ventricular lateral wall motion that was mildly hypokinetic, but it was better than that at the onset.

CONCLUSIONS

To the best of our knowledge, this could be the first case of spontaneous IMA graft dissection that was triggered by emotional stress and successfully treated by percutaneous intervention.

ADDRESS FOR CORRESPONDENCE: Dr. Masahiro Natsuaki, Department of Cardiovascular Medicine, Saga University, 5-1-1 Nabeshima, Saga 8498501, Japan. E-mail: natsuaki@kuhp.kyoto-u.ac.jp.

REFERENCES

1. Shammam N, Karia R. Iatrogenic intramural hematoma identified by intravascular ultrasound following selective angiography of the left internal mammary artery. *J Am Coll Cardiol Case Rep* 2019;1:127-30.
2. Khan Z, Latif F, Dasari TW. Internal mammary artery graft dissection: a case-based retrospective study and brief review. *Tex Heart Inst J* 2014;41:653-6.
3. Wong P, Rubenstein M, Inglessis I, et al. Spontaneous spiral dissection of a LIMA-LAD bypass graft: a case report. *J Interv Cardiol* 2004;17:211-3.
4. Suresh V, Evans S. Successful stenting of stenotic lesion and spontaneous dissection of left internal mammary artery graft. *Heart* 2007;93:44.
5. Karabulut A, Tanriverdi S. Acute coronary syndrome secondary to spontaneous dissection of left internal mammary artery bypass graft nine years after surgery. *Kardiol Pol* 2011;69:970-2.
6. Freixa X, Gallo R. Internal thoracic artery dissection: a proposed mechanistic explanation. *J Am Coll Cardiol Intv* 2013;6:533-4.
7. Koyama K, Yoneyama K, Tsukahara M, et al. A rare case of spontaneous dissection in a left internal mammary artery bypass graft in acute coronary syndrome. *J Am Coll Cardiol Intv* 2015;8:996-7.
8. Saw J, Starovoytov A, Humphries K, et al. Canadian spontaneous coronary artery dissection cohort study: in-hospital and 30-day outcomes. *Eur Heart J* 2019;40:1188-97.
9. Saw J, Aymong E, Sedlak T, et al. Spontaneous coronary artery dissection: association with predisposing arteriopathies and precipitating stressors and cardiovascular outcomes. *Circ Cardiovasc Interv* 2014;7:645-55.
10. Gruberg L, Dangas G, Mehran R, et al. Percutaneous revascularization of the internal mammary artery graft: short- and long-term outcomes. *J Am Coll Cardiol* 2000;35:944-8.

KEY WORDS acute coronary syndrome, coronary artery bypass, dissection