

CASE REPORT

BEGINNER

CLINICAL CASE

# Atrial Septal Defect Closure Device-Related Infective Endocarditis in a 20-Week Pregnant Woman



Navneet Sharma, MD,<sup>a</sup> Ul Weena, MD,<sup>a</sup> John Medamana, MD,<sup>b</sup> Noelle Mann, MD,<sup>a</sup> Paul Strachan, MD,<sup>c</sup> Joanna Chikwe, MD,<sup>d</sup> Smadar Kort, MD<sup>a</sup>

## ABSTRACT

With increasing atrial septal defect (ASD) repairs, more women of childbearing age will have ASD closure devices. Current ASD closure trials have excluded women planning pregnancy, making their management challenging. We present a pregnant woman, with a repaired ASD, who presented with device-related infective endocarditis. (**Level of Difficulty: Beginner.**) (J Am Coll Cardiol Case Rep 2021;3:300-3) © 2021 Published by Elsevier on behalf of the American College of Cardiology Foundation. This is an open access article under the CC BY-NC-ND license (<http://creativecommons.org/licenses/by-nc-nd/4.0/>).

A 29-year-old G1P0 woman at 20 weeks' gestation, with a history of atrial septal defect (ASD) closure, presented with fevers and myalgias. Physical examination and imaging demonstrated Janeway lesions and patchy bilateral pulmonary infiltrates concerning for septic emboli. She was treated with vancomycin and ceftriaxone starting on day 2 of hospitalization and blood cultures grew methicillin-sensitive *Staphylococcus aureus*.

## PAST MEDICAL HISTORY

The patient's medical history was significant only for an ASD, which was closed percutaneously using an Amplatzer device (Abbott Medical, Plymouth, Minnesota) 7 months before presentation, at another institution, for primary stroke prevention. Before device placement, she described episodes of migraines, which were attributed to her ASD. In addition, her father had been treated with an ASD closure device after a cryptogenic stroke. During the year following ASD closure, she underwent multiple dental cleanings and received prophylactic antibiotics during the first 6 months after ASD closure, in accordance with American Heart Association guidelines (1).

## LEARNING OBJECTIVES

- To review the current indications for prophylactic antibiotic therapy after ASD closure.
- To understand the challenges of treating IE during pregnancy.

## DIFFERENTIAL DIAGNOSIS

Given the patient's history of ASD closure with a prosthetic device, positive blood cultures, and

From the <sup>a</sup>Division of Cardiovascular Medicine, Department of Medicine, State University of New York at Stony Brook, Stony Brook, New York, USA; <sup>b</sup>Department of Medicine, NYU Langone Health, New York, New York, USA; <sup>c</sup>Division of Pulmonary Critical Care, Department of Medicine, State University of New York at Stony Brook, Stony Brook, New York, USA; and the <sup>d</sup>Department of Cardiac Surgery, Smidt Heart Institute at Cedars-Sinai Los Angeles, Los Angeles, California, USA.

The authors attest they are in compliance with human studies committees and animal welfare regulations of the authors' institutions and Food and Drug Administration guidelines, including patient consent where appropriate. For more information, visit the [Author Center](#).

Manuscript received February 10, 2020; revised manuscript received September 8, 2020, accepted September 23, 2020.

bilateral pulmonary infiltrates suggestive of septic emboli, the leading differential diagnosis was infective endocarditis (IE). Other differential diagnoses included bacteremia from complicated pneumonia and infectious vasculitis.

## INVESTIGATIONS

Initial transthoracic echocardiogram (TTE) showed a well-seated Amplatzer device with no residual shunt and no vegetations. Because of persistent bacteremia and high suspicion of IE, a transesophageal echocardiogram (TEE) was obtained that demonstrated a  $2.3 \times 1.1$ -cm. mobile tissue density on the left atrial surface of the device, consistent with a vegetation (Figure 1, Video 1).

## MANAGEMENT

On day 5 of hospitalization, she developed visual field deficits concerning for septic emboli. Although the patient hoped to delay surgery until the infant was viable, the obstetrics, infectious disease, and cardiothoracic surgery teams concluded that the balance of risks favored urgent surgery, given the persistent bacteremia and visual disturbances due to systemic embolization. After extensive multidisciplinary discussions with the patient, a decision was made to pursue surgery. At 20 weeks' gestation, she was taken for emergent surgery where the vegetation and Amplatzer device were successfully removed and the interatrial septum was repaired with a pericardial patch.

## DISCUSSION

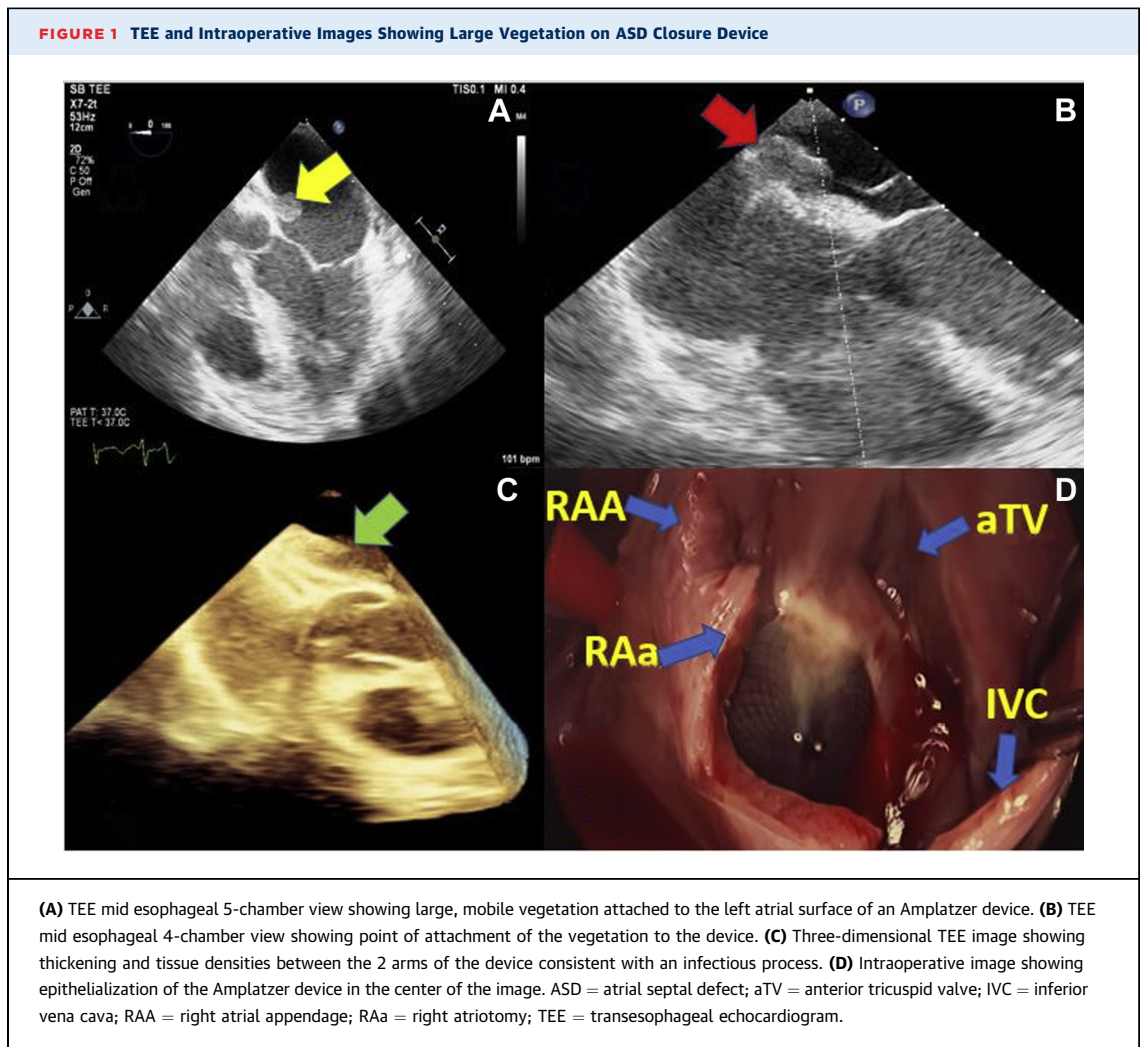
Cardiac disease complicates 1% to 4% of all pregnancies in the United States and accounts for 10% to 25% of maternal mortality (2). IE is an infection of damaged endothelial cells, particularly valve leaflets, with an incidence of 5 to 7 per 100,000 patient-years and has a poor prognosis, with in-hospital mortality rates as high as 15% to 20% at 1 year (3). A systematic review looking at IE in pregnancy estimated maternal and fetal mortality rates of 11% and 14%, respectively; however, this was thought to be an underestimation, as not all cases of pregnancy-related IE are published. Major risk factors for pregnancy-related IE are intravenous drug use, congenital heart disease (CHD), and rheumatic heart disease. Underlying heart disease remains a significant risk factor, as 34% of the included patients in the systematic review had predisposing cardiac conditions (4). Incidence of IE in adults with CHD is much higher, at approximately

0.9 to 1.3 cases per 1,000 patient-years, with a 20% recurrence rate (5). Lifelong antibiotic prophylaxis before dental procedures is indicated in unrepaired cyanotic congenital heart defects and in repaired defects with residual shunt or valvular regurgitation. Prophylaxis before dental procedures is also recommended for the first 6 months following successful defect repair (1). Prosthetic device IE at 1 year after ASD closure is extremely rare. In a recent case series of 22 patients with IE, none were reported at or after the 1-year mark (6). Bacterial seeding that causes infection likely occurs before complete neo-endothelialization of the prosthetic device, which is thought to occur between 1 and 3 months after implantation (7). Our patient developed IE 7 months after ASD closure, at that point complete neo-endothelialization was expected to be complete, especially because no residual shunt was seen on TTE. Although our patient received appropriate antibiotic prophylaxis in the high-risk period after device placement, her presentation of IE suggests that some patients may require prophylactic antibiotics beyond 6 months. It is possible pregnancy may potentially lead to immunocompromised state, therefore increasing the risk of IE.

ASDs and patent foramen ovals (PFOs) occur when there is a failure to close the communication between the right and left atria. Although an ASD is a deficiency in the atrial septum resulting in failure to overlap, causing continuous left-to-right shunting, a PFO is not a defect of the true septum but rather a failure of fusion of the primum and secundum atrial septa. This failure creates a flap valve opening that results in a transient right-to-left shunt when right atrial pressures exceed left atrial pressures. Although recent trials have demonstrated that PFO closure, as compared with antiplatelet or anticoagulation alone, reduces the risk of recurrent cryptogenic stroke, PFO closure has not been shown to be an effective migraine treatment (8,9). Although studies of transcatheter closure of ASDs did not indicate whether or not pregnant women were included, PFO closure trials specifically excluded women who were pregnant, lactating, or had a desire to become pregnant (9,10). The RESPECT (Randomized Evaluation of Recurrent Stroke Comparing PFO Closure to Established Current Standard of Care Treatment) trial excluded women who intended to become pregnant within the next year and the Gore REDUCE (GORE HELEX Septal Occluder/GORE CARDIOFORM Septal Occluder and

## ABBREVIATIONS AND ACRONYMS

<b>ASD</b>	= atrial septal defect
<b>CHD</b>	= congenital heart disease
<b>IE</b>	= infective endocarditis
<b>PFO</b>	= patent foramen ovale
<b>TEE</b>	= transesophageal echocardiogram
<b>TTE</b>	= transthoracic echocardiogram



Antiplatelet Medical Management for Reduction of Recurrent Stroke or Imaging-Confirmed TIA in Patients With Patent Foramen Ovale) trial excluded women planning to become pregnant within the next 2 years (8). Each of the PFO closure trials had strict entry criteria and therefore clinical application is most appropriate for patients who are not planning pregnancy in the near future and are younger than 60 years, with moderate to large interatrial shunt and/or an atrial septal aneurysm (8).

Special anesthetic considerations were made before both TEE and surgery for our patient. Before the TEE, pre-procedural planning with the cardiac team enabled a focused examination to obtain views of the suspected area of IE to minimize procedure time and discomfort. Only topical, rather than systemic, anesthesia was used to avoid reduction in cardiac output

and fetal hypoperfusion. During surgery, the most important consideration was the avoidance of sudden changes in cardiac output and early implementation of extracorporeal membrane oxygenation to maintain perfusion of the fetus, if necessary.

#### FOLLOW-UP

The patient had an uncomplicated postoperative course and went on to deliver a healthy infant without any sequelae of IE 17 weeks after surgery. Repeat TTE at 6 and 12 months post-procedure demonstrated no evidence of interatrial shunt. Both mother and child continue to do well 1 year after surgery. The subject of this case report provided consent to publication, which was obtained through our institution's standard protocol.

## CONCLUSIONS

IE of an intracardiac closure device is rare and can present unique challenges in pregnant patients. Although indications for ASD and PFO closure are increasing with recent trials, they largely exclude women planning pregnancy. Duration of antibiotic prophylaxis may need to be prolonged beyond 6 months in those with prosthetic intracardiac devices for CHD.

## FUNDING SUPPORT AND AUTHOR DISCLOSURES

The authors have reported that they have no relationships relevant to the contents of this paper to disclose.

**ADDRESS FOR CORRESPONDENCE:** Dr. Smadar Kort, Division of Cardiovascular Medicine, Stony Brook Medicine, Health Sciences Center T16-080, Stony Brook, New York 11794, USA. E-mail: [Smadar.kort@stonybrookmedicine.edu](mailto:Smadar.kort@stonybrookmedicine.edu). Twitter: [@SmadarKort](https://twitter.com/SmadarKort).

## REFERENCES

1. Lafaurie GI, Noriega LA, Torres CC, et al. Impact of antibiotic prophylaxis on the incidence, nature, magnitude, and duration of bacteremia associated with dental procedures: a systematic review. *J Am Dent Assoc* 2019;150:948-59.e4.
2. Petersen EE, Davis NL, Goodman D, et al. Racial/ethnic disparities in pregnancy-related deaths - United States, 2007-2016. *MMWR Morb Mortal Wkly Rep* 2019;68:762-5.
3. Cahill TJ, Prendergast BD. Infective endocarditis. *Lancet* 2016;387:882-93.
4. Kebed KY, Bishu K, Al Adham RI, et al. Pregnancy and postpartum infective endocarditis: a systematic review. *Mayo Clin Proc* 2014;89:1143-52.
5. Montanaro C, Dimopoulos K, Shore DF. Infective endocarditis in patients with congenital heart disease: when, where and how. *Int J Cardiol* 2017;249:171-2.
6. Amedro P, Soulatges C, Fraisse A. Infective endocarditis after device closure of atrial septal defects: case report and review of the literature. *Catheter Cardiovasc Interv* 2017;89:324-34.
7. Lock JE, Rome JJ, Davis R, et al. Transcatheter closure of atrial septal defects. Experimental studies. *Circulation* 1989;79:1091-9.
8. Osteraas ND, Vargas A, Cherian L, Song S. Role of PFO closure in ischemic stroke prevention. *Curr Treat Options Cardiovasc Med* 2019;21:63.
9. Majunke N, Bialkowski J, Wilson N, et al. Closure of atrial septal defect with the Amplatzer septal occluder in adults. *Am J Cardiol* 2009;103:550-4.
10. Fraisse A, Latchman M, Sharma SR, et al. Atrial septal defect closure: indications and contraindications. *J Thorac Dis* 2018;10:52874-81.

**KEY WORDS** atrial septal defect, echocardiography, endocarditis, pregnancy

**APPENDIX** For a supplemental video, please see the online version of this paper.