

# Comparison of analgesic efficacy of the conventional approach and mid-transverse process to pleura approach of the paravertebral block in video-assisted thoracoscopy surgeries: A randomised controlled trial

**Address for correspondence:**  
Dr. Manoj Kamal,  
123, Vaishali Avenue, Jhanwar  
Road, Jodhpur – 342 008,  
Rajasthan, India.  
E-mail: geetamanoj007@  
yahoo.co.in

**Submitted:** 17-Feb-2021

**Revised:** 21-Mar-2021

**Accepted:** 06-May-2021

**Published:** 23-Jul-2021

**Swathi KB, Manoj Kamal, Mritunjay Kumar<sup>1</sup>, Rakesh Kumar, Swati Chhabra, Pradeep Bhatia**

Department of Anaesthesiology and Critical Care, All India Institute of Medical Sciences, Jodhpur, Rajasthan, <sup>1</sup>Department of Anaesthesiology, Critical Care and Pain Medicine, All India Institute of Medical Sciences, New Delhi, India

## ABSTRACT

**Background and Aims:** The paravertebral block (PVB) is an effective alternative to thoracic epidural analgesia for post-operative analgesia in thoracic surgeries. Despite the use of ultrasound in PVB, the search for a safer approach continues. This study was conducted to compare the analgesic efficacy of conventional and mid-transverse process to the pleura (MTP) approach of the PVB. **Methods:** Forty patients aged between 18-60 years, posted for video-assisted thoracoscopic surgery, were enrolled for this study. Patients were randomised into two groups using a random number table, and group allocation was done by the sealed opaque envelope method. One group received PVB by conventional approach (group CP). In contrast, patients in the other group (group MP) received PVB by the mid-transverse process to pleura (MTP) approach before induction of general anaesthesia under ultrasound guidance. The study's primary aim was to compare analgesic consumption in the first 24 hours. Secondary aims were comparing the Visual Analogue Scale (VAS) score, block performance time, dermatomal spread, haemodynamic parameters such as heart rate (HR), oxygen saturation (SpO<sub>2</sub>), and non-invasive blood pressure (NIBP), patient satisfaction scores, and complications observed. Data were analysed using Statistical Package for the Social Sciences version 23. **Results:** Demographic parameters, block performance time, and dermatomal distribution were comparable in both groups. We did not find any statistical difference in the analgesic consumption in the first 24 hours ( $P = 0.38$ ), VAS at rest or on movement, complication rates, and patient satisfaction scores between the groups. **Conclusion:** The MTP approach of the PVB is as effective as the conventional thoracic paravertebral approach for post-operative analgesia in video-assisted thoracoscopic surgeries.

**Key words:** Analgesia, nerve block, pain, post-operative, thoracoscopic surgery, video-assisted, visual analogue scale

### Access this article online

Website: [www.ijaweb.org](http://www.ijaweb.org)

DOI: 10.4103/ija.IJA\_64\_21

Quick response code



## INTRODUCTION

Video-assisted thoracoscopic surgery (VATS) is a commonly performed surgical procedure for pathologies involving the thorax because of various advantages like small surgical incision, less post-operative pain, shorter hospital stays with lower costs, early mobilisation, lower overall morbidity, and shorter operating time in some procedures.<sup>[1]</sup> The intercostal nerve dysfunction

This is an open access journal, and articles are distributed under the terms of the Creative Commons Attribution-NonCommercial-ShareAlike 4.0 License, which allows others to remix, tweak, and build upon the work non-commercially, as long as appropriate credit is given and the new creations are licensed under the identical terms.

**For reprints contact:** WKHLRPMedknow\_reprints@wolterskluwer.com

**How to cite this article:** Swathi KB, Kamal M, Kumar M, Kumar R, Chhabra S, Bhatia P. Comparison of analgesic efficacy of the conventional approach and mid-transverse process to pleura approach of the paravertebral block in video-assisted thoracoscopy surgeries: A randomised controlled trial. Indian J Anaesth 2021;65:512-8.

due to incision, retraction of rib, irritation of rib, and trocar placement are the likely cause of pain in VATS.<sup>[2]</sup> Inadequate pain relief can adversely affect the patient's ability to take deep breaths, cough and clear secretions. It can lead to atelectasis, pneumonia, and respiratory failure, which further results in an increased hospital stay and morbidity/mortality. Suboptimal pain management may also cause the development of chronic pain. Persistent pain of moderate intensity beyond six months has been observed in 6.9% of patients following VATS.<sup>[3]</sup>

With the advent of ultrasound, truncal blocks can be performed with more accuracy.<sup>[4]</sup> Paravertebral block (PVB) has been used for analgesia in thoracotomy, breast surgery, chest wall trauma, scapular surgery,<sup>[5]</sup> hernia repair or renal surgery. It is a commonly performed truncal block in VATS too.<sup>[6]</sup> Krediet *et al.*,<sup>[7]</sup> described nine different ultrasound-guided approaches of the PVB. Costache *et al.*,<sup>[8]</sup> described the mid-point transverse process to pleura (MTP) block approach of PVB, in which they deposited local anaesthetic (LA) between the transverse process and pleura. Theoretically, PVB performed by conventional approach is associated with more complications due to proximity to pleura compared to the MTP approach.

No study has compared the analgesic effects of conventional and MTP approach of PVB. We planned a study to compare the effectiveness of both approaches. The primary objective of the study was to compare analgesic consumption in the first 24 hours. The secondary objectives were block performance time, Visual Analogue Scale (VAS) score at different time intervals in the first 24 hours, haemodynamic parameters, block failure rate, complications related to the procedure, and patient satisfaction rate.

## METHODS

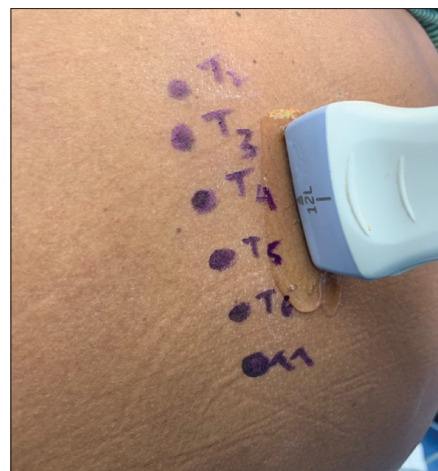After ethical committee approval and registration with the Clinical Trials Registry-India, this prospective, non-inferiority, randomised, double-blinded, comparative clinical trial was conducted in a tertiary health care centre between October 2018 and January 2020 in accordance with the Declaration of Helsinki and Good Clinical Practice. Written informed consent was obtained from all the participants. Forty-three American Society of Anesthesiologists (ASA) physical status I/II, aged between 18 to 60 years, scheduled to undergo VATS surgeries were included. Patients with pre-existing infection at block site, known

allergy to study drugs, coagulation disorder, history of psychiatric illness, pre-existing neurological deficits, patient with morbid obesity (body mass index >40 kg/m<sup>2</sup>), presence of any pre-operative pain or history of chronic pain and history of regular analgesic use were excluded. During the pre-operative visit, patients were made conversant with the VAS score. The severity of pain was assessed using VAS numbers from 0 to 10 cm (0 cm indicates no pain, and 10 indicates the worst pain imaginable).

The patients were randomised into two equal groups using a computer-generated random number table, and group allocation was done by a sequentially numbered, sealed, opaque envelope method in 1:1 allocation ratio into conventional approach (group CP) and mid-transverse process to pleura approach (group MP) by an anaesthesiologist who was not a part of the study.

Standard ASA monitors like electrocardiogram (ECG), non-invasive blood pressure (NIBP), pulse oximetry were attached, and baseline vitals were recorded in the procedure room. Patients were premedicated with intravenous (IV) midazolam 0.04–0.06 mg/kg and fentanyl 1 µg/kg. All blocks were performed in the sitting position with 18G block needle 100 mm (Contiplex®, B Braun Melsungen, Germany), under ultrasonography (USG) guidance (LOGIQe, GE Healthcare, China) with a high-frequency ultrasound linear array probe (8-13 MHz; 38 mm footprint) by the same anaesthesiologists.

The probe was placed 3-4 cm in parasagittal position at the back in the cephalad-caudal direction at the T4-T5 transverse process on the operative side. Parietal pleura



**Figure 1:** Surface landmarks and probe position

and superior costotransverse ligament (SCTL) were identified [Figure 1]. The skin infiltration was done with 2% lidocaine with a 24G hypodermic needle.

In group CP, the needle was inserted in-plane till it pierced the SCTL. The correct placement of the needle tip was confirmed by downward displacement of parietal pleura after injection of normal saline (NS). In group MP, the needle was introduced in-plane, till tip lies between the mid-point of the posterior border of the transverse process and the pleura (superficial to the SCTL) [Figure 2]. In both groups, after confirmation of the needle tip, ropivacaine 0.2%, 20 mL was injected, followed by catheter insertion 3 cm distal to the needle tip and secured at the back. Infusion of 0.2% ropivacaine, 0.1 ml/kg/h, was continued till 24 hours postoperatively in both groups.

The block performance time (time taken from needle insertion to threading of catheter into space), haemodynamic parameters, and any block related complications such as hypotension [decrease in mean arterial pressure (MAP) >20% from baseline], bradycardia [heart rate (HR) <40 beats/min], pneumothorax, and vascular puncture were recorded.

The success rate and level of the sensory blockade were tested with the pinprick method. Onset time was described as a decreased sensation to pinprick after injections. Patients were shifted to the operating room (OR) 30 minutes after the performance of the block. Anaesthesiologists looking after intra and post-operative patient care and data collection were unaware of the group assignment.

Anaesthesia was induced with propofol, 2 mg/kg and fentanyl 1 µg/kg. Rocuronium 1 mg/kg was given to facilitate endobronchial intubation (Bronchocath

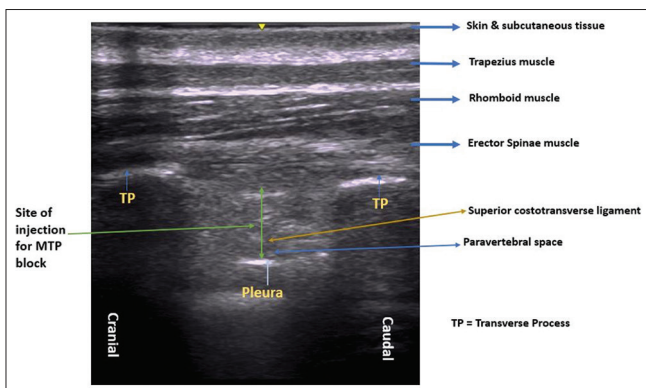
tube; Mallinckrodt Medical, Athlone, Ireland). The radial artery catheter was secured after induction of anaesthesia. Anaesthesia was maintained with an end-tidal concentration of 0.8-1.2% sevoflurane and 50% air in oxygen. The mechanical ventilation of the lung was adjusted to maintain normocapnia. HR, oxygen saturation (SpO<sub>2</sub>), systolic blood pressure (SBP), diastolic blood pressure (DBP), and MAP, were recorded at 10-minute intervals. Intraoperative MAP was maintained within 80% to 120% of baseline values. Hypotension was treated with IV mephentermine and fluid boluses. Bradycardia episodes were treated with IV atropine 0.6 mg. Fentanyl 1 µg/kg IV boluses were used in both the groups intraoperatively if HR and MAP increased by >20% from the baseline after ruling out other causes like light plane of anaesthesia, the inadequacy of muscle relaxation and fluid deficit.

Thoracoscopy was performed in the lateral position using three ports (one at the sixth intercostal space in the midaxillary line for camera insertion and two ports at the third or fourth intercostal space for the instruments for surgical manipulation. After completing the surgical procedure, a chest tube was placed at the 6<sup>th</sup> intercostal space.

Ondansetron 4 mg IV was administered as antiemetic to all patients before completion of the surgical procedure. All patients were extubated at the end of the surgery after reversal of neuromuscular blockade. The patient was then transferred to the post-anaesthesia care unit (PACU) and later to the ward. All the observations, i.e., post-operative HR, SBP, DBP, MBP, SpO<sub>2</sub>, respiratory rate (RR), and post-operative VAS score at rest and on movement (on coughing), were assessed at 1, 3, 6, 12, 18, and 24 hours.

Paracetamol (PCM) 15 mg/kg IV was administered in all patients if VAS score ≥4 was recorded at any time or on patient demand. Fentanyl 1 µg/kg IV was used as additional rescue analgesia if the VAS score continued to be >4 even after PCM administration. If the patient required Fentanyl >1 µg/kg IV twice in the initial 4 hours of the post-operative period, it was considered to be a block failure, and such patients were not used for subsequent analysis for additional opioid consumption.

Assessment of anaesthetised dermatomes (defined as an area of reduced sensitivity to cold touch or pinprick as compared with the contralateral side) was done at six hours postoperatively. Side effects like nausea,



**Figure 2:** Sonographic image of the mid-transverse process to pleura (MTP) block

vomiting, hypotension, bradycardia, respiratory depression, and pruritus were also recorded. Patient satisfaction was recorded by using a numerical satisfaction score (4 = excellent, 3 = good, 2 = fair, 1 = poor) 24 hours after surgery.

The sample size of this non-inferiority type was calculated based on a pilot study of 10 patients in each group. The primary endpoint was the mean 24 hours analgesic consumption of fentanyl. The non-inferiority limit was 5. Assuming a standard deviation of 5, a one-sided type I error rate of 5%, 90% power and true mean difference between the interventions as zero, the sample size calculated was 18 in each group.

Data collected were tabulated in a Microsoft excel spreadsheet and analysed using Statistical Package for the Social Sciences (SPSS) version 23 (International Business Machine SPSS Advanced Statistics, Chicago, IL, USA). The normality distribution of the variables was tested using the Shapiro-Wilk test. The categorical measurements were expressed in numbers or ratio, and the results of quantitative variables were presented as median (IQR) or mean (SD). Chi-square test was used for comparing qualitative data. Unpaired Student's *t*-test using Bonferroni multiple comparisons test was applied for comparing quantitative data. A *P* value <0.05 was considered significant.

## RESULTS

A total of 43 patients were assessed for eligibility. The surgical plan was changed to open thoracotomy in two patients, and one patient declined to participate in the study. The remaining 40 patients were randomised into two groups: group CP and group MP. Two patients in each group were excluded from the analysis because of catheter displacement or pleural puncture [Figure 3].

Demographic characteristics, surgery and anaesthesia duration and intraoperative haemodynamics were comparable in both groups [Table 1].

One patient in group CP required PCM once, while one patient in group MP required PCM thrice. Hence, total PCM consumption was 1 g in group CP and 4 g in group MP (*P* = 0.38). Additional analgesia (fentanyl) was needed only in one patient in each group. Fentanyl consumption was 40 µg and 50 µg in groups CP and MP, respectively. (*P* > 0.999).

We did not find any statistical difference in VAS scores at rest and on movement between the two groups at all time points except 24 hours on movement (*P* = 0.016) [Table 2]. The mean block performance time in group CP was 24.89 ± 5.71 min, and in the group MP group, it was 26.6 ± 8.74 min (*P* = 0.261). The dermatomal level of the block at 6 hours postoperatively was comparable in both groups. Patient satisfaction scores were also comparable in both groups [Table 3].

We did not observe any statistically significant difference in HR, SBP, DBP, MBP, SpO<sub>2</sub>, and RR at 1, 3, 6, 12, 18, and 24 hours postoperatively. Hypotension occurred in two patients in group CP and only one patient in group MP (*P* = 0.545). Only one patient in group MP had a bradycardia episode. Pleural puncture occurred in one patient in group CP (*P* = 0.31).

## DISCUSSION

Our study demonstrated that the analgesic requirement in the first 24 hours postoperatively was under the non-inferiority margin; hence analgesic effects of continuous MTP block were comparable with that of the conventional approach of PVB in

**Table 1: Distribution of Demographic Variables, Duration of Surgery and Duration of Anaesthesia in Two Groups**

Variables	Group CP (n=18)	Group MP (n=18)	<i>P</i>
Age in years (Mean±SD)	31.22±12.21	36.56±11.16	0.587
Gender [Number (%)]			
Female	8 (44.4)	5 (27.8)	0.298
Male	10 (55.6)	13 (72.2)	
Height in cm (Mean±SD)	162.50±11.37	161.33±10.85	0.739
Weight in kg (Mean±SD)	56.94±9.50	56.28±7.91	0.574
BMI* (kg/m <sup>2</sup> ) (Mean±SD)	21.46±1.97	21.64±3.19	0.270
ASA <sup>†</sup> grade			
I	15 (83.3)	12 (66.7)	0.248
II	3 (16.7)	6 (33.3)	
Duration of surgery (minutes) (Mean±SD)	137.76±6.20	136.06±6.57	0.316
Duration of anaesthesia (minutes) (Mean±SD)	184.28±8.82	182.89±8.60	0.247

\*BMI: Body mass index, <sup>†</sup>ASA: American Society of Anesthesiologists, SD: Standard deviation. Student's *t*-test and Chi-square test applied. *P*<0.05 is significant



patients undergoing VATS. The VAS scores at rest and on movement, block performance time, dermatomal level of block, and patient satisfaction scores were comparable between the two approaches.

**Table 2: Comparison of VAS at Rest and Movement Between Two Groups**

	VAS* at rest (Mean±SD)			VAS* at movement (Mean±SD)		
	Group CP (n=18)	Group MTP (n=18)	P	Group CP (n=18)	Group MTP (n=18)	P
1 h	1.39±1.09	1.28±1.52	0.14	1.89±1.23	1.89±1.15	0.502
3 h	1.17±0.98	1.50±1.46	0.56	1.44±0.85	1.89±1.13	0.389
6 h	1.17±1.09	1.28±1.36	0.39	1.28±0.95	1.50±1.15	0.418
12 h	0.44±0.61	1.17±0.98	0.06	1.11±1.02	1.50±1.15	0.776
18 h	0.56±0.61	0.94±1.30	0.22	0.87±1.02	1.28±1.36	0.384
24 h	0.39±0.69	0.61±1.24	0.67	0.56±0.94	0.89±0.90	0.016

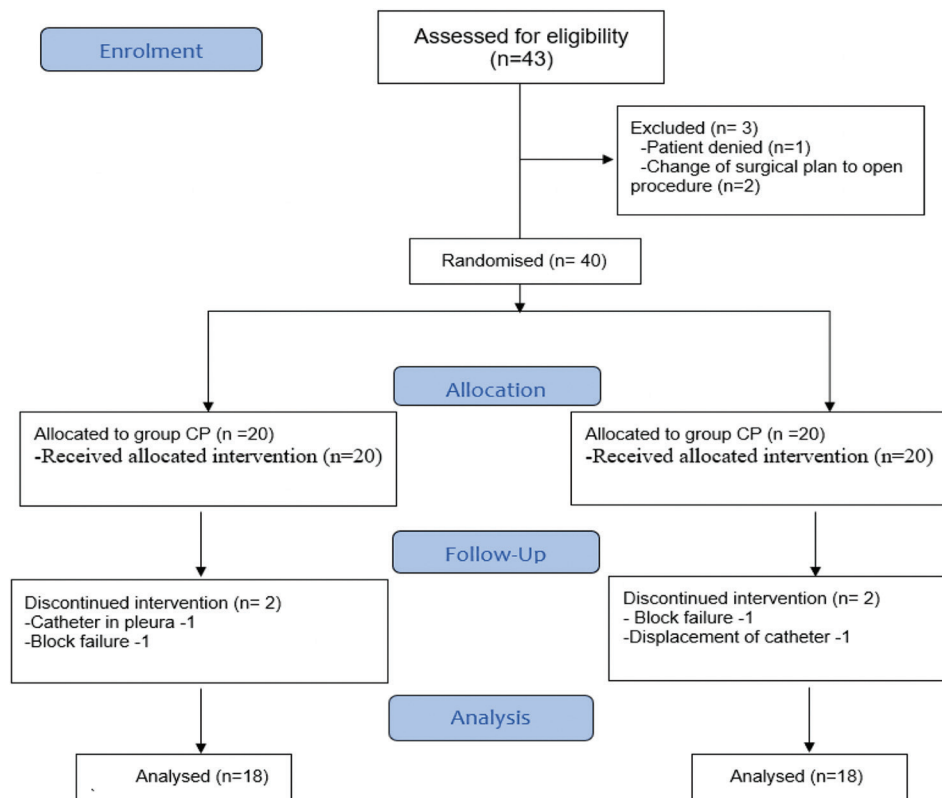
VAS: Visual analogue scale, values represent statistical significance. Student's t-test was applied. P<0.05 is significant

**Table 3: Comparison of Patient Satisfaction Scores Between the Groups**

Satisfaction score	Group CP (numbers)	Group MTP (numbers)	P score
1 (Excellent)	5	5	0.446
2 (Good)	9	9	
3 (Fair)	4	2	
4 (Poor)	0	2	
	n=18	n=18	

The PVB provides analgesia to the operative side only and is safer than thoracic epidural analgesia.<sup>[9]</sup> The paravertebral space is a wedge-shaped space on either side of the vertebral column, bounded by the parietal pleura anterolaterally, by the SCTL posteriorly, and by the vertebrae and intervertebral foramina medially. Rich blood supply, proximity to the epidural or intrathecal space, and parietal pleura make it prone to inadvertent vascular puncture, hypotension, bradycardia, and pneumothorax, respectively.<sup>[10]</sup> Thoracic paravertebral space contains fatty tissue, intercostal spinal nerve, dorsal rami, intercostal vessels, rami communicants, and the sympathetic chain. The analgesic effect of PVB is attributed to the deposition of LA near dorsal ramus and subsequent spread to ventral ramus and sympathetic chain. Multiple techniques and approaches have been suggested for thoracic PVB.<sup>[11]</sup>

Eason and Wyatt first described the classical landmark technique of the PVB.<sup>[12]</sup> The use of USG in regional anaesthesia has revolutionised the PVB technique to the extent that Krediet *et al.*,<sup>[7]</sup> in a review article, had described nine different ultrasound-guided approaches. Costache I *et al.*<sup>[8]</sup> in 2017 described a new approach of thoracic PVB viz. the MTP approach.



**Figure 3: CONSORT flow diagram**

As the needle tip in the MTP block is away from the pleura and neurovascular structures, the incidences of pleural puncture and injury to the nerve and vessels are reportedly less than the conventional approach. Thus, MTP is a proxy block to facilitate PVB without placing the needle tip in the paravertebral space. The drug deposited in the MTP block also reaches the intercostal space through the internal intercostal membrane.<sup>[13]</sup> The suggested mechanism of action of the MTP approach is supported by cadaveric studies, which showed the fenestrations in the SCTL.<sup>[14]</sup> Moreover, visualisation of SCTL is not necessary for MTP block, which may be difficult in obese patients.<sup>[15]</sup> Various case reports and cadaveric studies have ascertained the analgesic efficacy of MTP block.<sup>[16-19]</sup> To the best of our knowledge, no study is available that compares the conventional and MTP approach of the PVB.

The equal efficacy of MTP and the conventional approach of PVB may be attributed to the proximity of endpoints compared to other paraspinous or truncal blocks. In our study, mean block performance time in both groups was comparable, although threading of catheter in group MP was difficult compared to group CP. There was no statistically significant difference in patient satisfaction scores between the two groups. Watton *et al.*,<sup>[19]</sup> have reported high satisfaction scores with MTP block in three patients undergoing VATS.

In our study, the dermatomes anaesthetised in both groups were comparable. Dermatomal spread was in concordance with similar studies/reports on PVB and MTP blocks.<sup>[20-22]</sup> Scimia *et al.*,<sup>[23]</sup> achieved a sensory block in T3-T7 dermatomes on the operative side and good quality analgesia following VATS in a patient for adenocarcinoma of the right lower lobe and concluded that the MTP block might be a possible alternative to the conventional regional techniques, especially when these blocks are contraindicated or in high-risk patients.

Our study demonstrated similar block performance time, VAS scores, rescue analgesic consumption, and dermatomal spread with fewer complications like pleura puncture in the MTP block group, making it a safe substitute to the conventional PVB technique. The MTP block has also been found to be an effective and safe analgesic modality for modified radical mastectomy and medical thoracoscopy.<sup>[15,24]</sup> We, too, have reported the efficacy of the MTP block in a

patient with multiple rib fractures and for intercostal drain placement and rib resection procedure.<sup>[17,18]</sup>

Limitations of our study were the omission of data collection on the effect of the block on intraoperative analgesia, time to first rescue analgesia and long-term complications like the development of post-operative pulmonary complications and chronic pain. Since very few patients required any rescue analgesia, comparison of both the approaches of PVB with a large sample size and in patients undergoing thoracotomies is warranted.

## CONCLUSION

The MTP approach to the PVB is non-inferior to the conventional thoracic paravertebral approach for providing analgesia in patients undergoing VATS; hence it may be considered a safe alternative approach to the PVB.

## Financial support and sponsorship

Nil.

## Conflicts of interest

There are no conflicts of interest.

## REFERENCES

- Grogan EL, Jones DR. VATS lobectomy is better than open thoracotomy: What is the evidence for short-term outcomes? *Thorac Surg Clin* 2008;18:249-58.
- Wildgaard K, Ravn J, Kehlet H. Chronic post-thoracotomy pain: A critical review of pathogenic mechanisms and strategies for prevention. *Eur J Cardiothorac Surg* 2009;36:170-80.
- Stammerger U, Steinacher C, Hillinger S, Schmid RA, Kinsbergen T, Weder W. Early and long-term complaints following video-assisted thoracoscopic surgery: Evaluation in 173 patients. *Eur J Cardiothorac Surg* 2000;18:7-11.
- Mehdiratta L, Bajwa SJ, Malhotra N, Joshi M. Exploring cocktails, remixes and innovations in regional nerve blocks: The clinical research journey continues. *Indian J Anaesth* 2020;64:1003-6.
- Vadhanan P, Bokka N. Scapular surgery under combined thoracic paravertebral and interscalene blocks. *Indian J Anaesth* 2020;64:1083-4.
- Landreneau RJ, Mack MJ, Hazelrigg SR, Naunheim K, Dowling RD, Ritter P, *et al.* Prevalence of chronic pain after pulmonary resection by thoracotomy or video-assisted thoracic surgery. *J Thorac Cardiovasc Surg* 1994;107:1079-85.
- Krediet AC, Moayeri N, van Geffen GJ, Bruhn J, Renes S, Bigeleisen PE, *et al.* Different approaches to ultrasound-guided thoracic paravertebral block: An illustrated review. *Anesthesiology* 2015;123:459-74.
- Costache I, de Neumann L, Ramnanan CJ, Goodwin SL, Pawa A, Abdallah FW, *et al.* The mid-point transverse process to pleura (MTP) block: A new endpoint for thoracic paravertebral block. *Anaesthesia* 2017;72:1230-6.
- Yeung JHY, Gates S, Naidu BV, Wilson MJA, Gao Smith F. Paravertebral block versus thoracic epidural for patients undergoing thoracotomy. *Cochrane Database Syst Rev*

- 2016;2:CD009121. doi: 10.1002/14651858.CD009121.pub2.
10. Batra RK, Krishnan K, Agarwal A. Paravertebral block. *J Anaesthesiol Clin Pharmacol* 2011;27:5-11.
  11. Amlong C, Guy M, Schroeder KM, Donnelly MJ. Out-of-plane ultrasound-guided paravertebral blocks improve analgesic outcomes in patients undergoing video-assisted thoracoscopic surgery. *Local Reg Anesth* 2015;8:123-8.
  12. Eason MJ, Wyatt R. Paravertebral thoracic block-A reappraisal. *Anaesthesia* 1979;34:638-42.
  13. Richardson J, Lönnqvist PA, Naja Z. Bilateral thoracic paravertebral block: Potential and practice. *Br J Anaesth* 2011;106:164-71.
  14. Ibrahim AF, Darwish HH. The costotransverse ligaments in human: A detailed anatomical study. *Clin Anat* 2005;18:340-5.
  15. Syal R, Kumar R, Chhabra S, Agha M. Is the mid-transverse process to pleura block a better technique for patients with obesity undergoing modified radical mastectomy? *Korean J Anesthesiol* 2020;73:462-4.
  16. Bhoi D, Narasimhan P, Nethaji R, Talwar P. Ultrasound-guided mid-point transverse process to pleura block in breast cancer surgery: A case report. *A A Pract* 2019;12:73-6.
  17. Sharma RS, Kumar R, Kamal M, Bhatia P. Use of the mid-transverse process to pleura block in a patient undergoing intercostal drain placement and rib resection. *Indian J Anaesth* 2019;63:245-6.
  18. Syal R, Kumar R, Kamal M, Bhatia P. Novel block and new indication: Ultrasound-guided continuous “mid-point transverse process to pleura” block in a patient with multiple rib fractures. *Saudi J Anaesth* 2019;13:365-7.
  19. Watton DE, Rose PGD, Abdallah FW, Thompson PVB, Maziak DE, Costache I. Midpoint transverse process to pleura catheter placement for post-operative analgesia following video-assisted thoracoscopic surgery. *Anaesth Rep* 2019;7:65-8.
  20. Fang B, Wang Z, Huang X. Ultrasound-guided pre-operative single-dose erector spinae plane block provides comparable analgesia to thoracic paravertebral block following thoracotomy: A single center randomised controlled double-blind study. *Ann Transl Med* 2019;7:174.
  21. Taketa Y, Irisawa Y, Fujitani T. Comparison of ultrasound-guided erector spinae plane block and thoracic paravertebral block for post-operative analgesia after video-assisted thoracic surgery: A randomized controlled non-inferiority clinical trial. *Reg Anesth Pain Med* 2020;45:10-5.
  22. Zhao H, Xin L, Feng Y. The effect of pre-operative erector spinae plane vs paravertebral blocks on patient-controlled oxycodone consumption after video-assisted thoracic surgery: A prospective randomized, blinded, non-inferiority study. *J Clin Anesth* 2020;62:109737.
  23. Scimia P, Fusco P, Droghetti A, Harizaj F, Basso Ricci E. The ultrasound-guided mid-point transverse process to pleura block for post-operative analgesia in video-assisted thoracoscopic surgery. *Minerva Anesthesiol* 2018;84:767-8.
  24. Pedoto A, Kalchiem-Dekel O, Baselice S, Husta BC, Rosenblatt MA. Ultrasound-guided midpoint transverse process to pleura nerve block for medical thoracoscopy: A case report. *A A Pract* 2020;14:e01240. doi: 10.1213/XAA.0000000000001240.

Announcement

**Old Issues of IJA**

Limited copies of old issues of IJA from 2013 are available in IJA office. Members interested can contact Immediate Past Editor In Chief (editorija@yahoo.in/ijadivatia@gmail.com / 98690 77435)