



# Role of Tofisopam in Post COVID Neuro-psychiatric Sequelae: A Case Series

Jigyansa ipsita Pattnaik<sup>1</sup> , Deepthi R. A.<sup>2</sup>, Shivani Dua<sup>2</sup>, Prasanta Padhan<sup>3</sup>, and Jayaprakash Russell Ravan<sup>2</sup> 

Although India reports the second-highest number of COVID-19 cases, the recovery rate stands at 93%.<sup>1,2</sup> Those who recover from COVID-19 report ongoing respiratory, neurological, and psychiatric symptoms. The neuropsychiatric manifestations described range from low mood, lack of confidence, fatigue, and anxiety to psychosis and catatonia, with residual fatigue, negativism, sleep disturbance, cognitive dulling, and PTSD. The post-COVID neurological symptoms are popularly known as brain fog.<sup>3,4</sup> Brain fog is not fully understood and is often described as slow thinking, difficulty in focusing, confusion, lack of concentration, or haziness in the thought processes.<sup>5</sup>

The pathophysiology of the neuropsychiatric manifestations is postulated to be immune dysregulation, cerebrovascular microangiopathy, and autoimmunity via molecular mimicry (cross-reaction of myelin, glia, and beta-2 glycoprotein with viral epitopes or by direct neuronal damage).<sup>6</sup> The respiratory symptoms are the prime focus of treatment at present. However, past outbreaks of COVID have

shown that the neuropsychiatric symptoms arising out of the viral infection can add significantly to the health burden and quality of life.<sup>7,8</sup> Thus, it becomes prudent to provide interventions for the neuropsychiatric symptoms as well.

In this case series, we describe the effect of tofisopam in combatting the neuropsychiatric manifestations in post-COVID-19 clinical scenarios. Tofisopam has an anxiolytic effect in anxiety and depression, without sedative and muscle relaxant side-effects, has anti-amnesic properties, and works for both positive and negative symptoms of psychosis. The diverse range of the post-COVID-19 neuropsychiatric manifestations and the broad action of tofisopam made us try this molecule in this novel situation. We monitored for sedation, respiratory depression, and hypotension in particular, in addition to the use of open-ended questions about any new symptoms. We also postulate how the unique pharmacokinetic and pharmacodynamic properties of tofisopam can have a therapeutic role in post-COVID neuropsychological symptoms.

## Case I

A 52-year-old businessman, with no contributory medical or neuropsychiatric comorbidities, was hospitalized for COVID-19 pneumonia. He received conservative management as per COVID-19 treatment guidelines and was discharged after a week. Within a week of the discharge, he reported being withdrawn, having decreased interaction with family members, remaining mute for hours together, hypersomnolence, and sometimes would not swallow the chewed food. He was brought to the psychiatric outpatient department for evaluation. On Mini Mental State Examination, he scored 24 out of 27. In the Bush Francis Catatonia Rating Scale, the score was 24, with higher scores in the domains of mutism, verbal fluency, and negativism. EEG and MRI brain were normal.

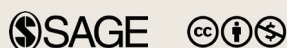In view of catatonia and recent recovery from COVID pneumonia, a benzodiazepine without respiratory suppression effect, tofisopam, was administered at a dose of 100 mg/per day, in divided doses, for two weeks. No respiratory

<sup>1</sup>Dept. of Psychiatry, St. John's Medical College, Bengaluru, Karnataka, India. <sup>2</sup>Dept. of Psychiatry, Kalinga Institute of Medical Sciences, Bhubaneswar, Odisha, India. <sup>3</sup>Dept. of Rheumatology, Kalinga Institute of Medical Sciences, Bhubaneswar, Odisha, India.

**HOW TO CITE THIS ARTICLE:** Pattnaik JI, Deepthi R. A., Dua S, Padhan P, Ravan JR. Role of Tofisopam in Post COVID Neuro-psychiatric Sequelae: A Case Series. *Indian J Psychol Med.* 2021;43(2):174–176.

**Address for correspondence:** Dr Jayaprakash Russell Ravan, F-29, Staff Quarters, KIMS, Campus 5, KIIT University, Patia, Bhubaneswar-24, Odisha, India. E-mail: jpr\_219@yahoo.co.in

**Submitted:** 6 Dec. 2020  
**Accepted:** 24 Jan. 2021  
**Published Online:** 26 Feb. 2021



Copyright © The Author(s) 2021

Creative Commons Non Commercial CC BY-NC: This article is distributed under the terms of the Creative Commons Attribution- NonCommercial 4.0 License (<http://www.creativecommons.org/licenses/by-nc/4.0/>) which permits non-Commercial use, reproduction and distribution of the work without further permission provided the original work is attributed as specified on the SAGE and Open Access pages (<https://us.sagepub.com/en-us/nam/open-access-at-sage>).

**ACCESS THIS ARTICLE ONLINE**  
Website: [journals.sagepub.com/home/szj](http://journals.sagepub.com/home/szj)  
DOI: 10.1177/0253717621994285

depression or hypotension was observed. The catatonic symptoms improved within 72 hours. Sustained improvement in psychomotor functioning was noted at four weeks follow-up.

## Case II

A 45-year-old male, teaching faculty of a graduation college, was detected to be COVID-19 RTPCR positive after he developed fever for one day with conjunctival congestion and severe body pain. He was advised home-based treatment with doxycycline and ivermectin. He recovered and resumed work after two weeks. Post-recovery, he had difficulties in planning academic activities and organizing ability, which he was able to do before developing COVID-19. He described feeling dull and lethargic, in the absence of a pervasive low mood state, with normal sleep and appetite. No memory deficit was noted during clinical assessment, with an MMSE score of 27 out of 30. His lobar functions assessment revealed deficits in the frontal lobe, and cognitive retraining was suggested, which was not available during the pandemic. He was started on tofisopam 50 mg/day as monotherapy after breakfast, with an improvement of visuospatial and executive functioning as per Montreal Cognitive Assessment within 10 days of initiation of the medication. No side effects of tofisopam were reported by the patient.<sup>9</sup>

## Case III

A 52-year-old post-menopausal homemaker, with a past history of recurrent depressive disorder, who was maintaining well with desvenlafaxine 100 mg and clonazepam 0.5 mg, developed COVID-19 and was admitted for respiratory distress and hypoxia. She received conservative management and was given low molecular weight heparin and dexamethasone and gradually improved over 10 days. She was continued on desvenlafaxine 100 mg per day during COVID treatment. Following discharge, she developed anxiety symptoms, with subjective breathing difficulties, weakness, and fatigability, with a Hamilton Anxiety Rating Scale score of 15. On examination, she was afebrile, maintaining saturation in room air, and the x-ray chest was normal. Tofisopam 50 mg twice daily was added to

desvenlafaxine, with clinical improvement noted at two weeks' follow-up.

## Discussion

Encephalitis lethargica, also known as Von Economo's encephalitis, demonstrated the association of viral infections and brain, during the Spanish flu pandemic of 1917. It was characterized by hypersomnolence, behavioral disturbances, catatonic states, and movement disorders.<sup>10,11</sup> COVID-19 can have multi-systemic effects, including on the central nervous system, and thus may precipitate a spectrum of neuropsychiatric manifestations.<sup>12,13</sup> Here, we described the diverse range of such manifestations in the post-COVID recovery state. In the first case, there was the emergence of catatonic symptoms in the absence of any abnormality in neuro-imaging or EEG. The second case presented with cognitive and executive functioning deficit post-COVID recovery, which improved with tofisopam. The third case developed a re-emergence of anxiety and depressive symptoms despite being on maintenance antidepressant. All the above is postulated to be due to immune dysregulation and/or cerebrovascular microangiopathy.<sup>6</sup>

Tofisopam, a 2,3-benzodiazepine (2,3-BDZs) with a common chemical backbone to "classical" 1,4-benzodiazepines, does not interact with the classical benzodiazepine binding site of the GABA receptor.<sup>14</sup> Its non-sedative, non-hypotensive property, without any respiratory suppression, could have provided the added advantage in the post-COVID-19 state.<sup>15</sup> The mixed dopamine agonist-antagonist property of tofisopam probably modulates the hypo-dopaminergic state in catatonia. Tofisopam does not impair intellectual performance as other benzodiazepines do. In contrast, it has a cognitive stimulatory activity.<sup>16</sup> The anti-amnesic effects of tofisopam, with concomitant improvements in hippocampal synaptogenesis, neurogenesis, and glial plasticity, have been found in animal studies.<sup>17</sup> Besides, tofisopam has been reported to have an antidepressant property, possibly by sharing a mechanism similar to Serotonin Norepinephrine Reuptake Inhibitors via phosphodiesterase 4 inhibition.<sup>18</sup> This inhibitory action of tofisopam on PDE has potential therapeutic benefits of

cognitive enhancement, improving anxiety, and psycho-energetic effect, without attention impairment.<sup>19</sup>

This article highlights the possible role of tofisopam in post-COVID neuro-psychiatric sequelae, which needs to be further substantiated by randomized controlled trials.


## Declaration of Conflicting Interests

The authors declared no potential conflicts of interest with respect to the research, authorship, and/or publication of this article.

## Funding

The authors received no financial support for the research, authorship, and/or publication of this article.

## ORCID iDs

Jayaprakash Russell Ravan  <https://orcid.org/0000-0002-8315-2573>  
Jigyansa Ipsita Pattnaik  <https://orcid.org/0000-0001-8563-7200>

## References

1. worldometer. COVID-19 coronavirus pandemic. [https://www.worldometers.info/coronavirus/?utm\\_campaign=homeAdvegas](https://www.worldometers.info/coronavirus/?utm_campaign=homeAdvegas). Accessed February 7, 2021.
2. World Health Organization. *Coronavirus disease (COVID-19)*. <https://www.who.int/emergencies/diseases/novel-coronavirus-2019>. Accessed January 17, 2021.
3. Morley JE. COVID-19—the long road to recovery. *J Nutr Health Aging* 2020. Epub ahead of print 2020. DOI: 10.1007/s12603-020-1473-6.
4. Yelin D, Wirtheim E, Vetter P, et al. Long-term consequences of COVID-19: research needs. *Lancet Infect Dis* 2020; 20: 1115–1117.
5. Ocon AJ. Caught in the thickness of brain fog: exploring the cognitive symptoms of Chronic Fatigue Syndrome. *Front Physiol* 2013; 4. Epub ahead of print 2013. DOI: 10.3389/fphys.2013.00063.
6. Banerjee D and Viswanath B. Neuropsychiatric manifestations of COVID-19 and possible pathogenic mechanisms: Insights from other coronaviruses. *Asian J Psychiatr* 2020; 54: 102350.
7. Chua SE, Cheung V, Mcalonan GM, et al. Stress and psychological impact on SARS patients during the outbreak. *Can J Psychiatry* 2004; 49: 385–390.
8. Kroker K. Mark Honigsbaum: A history of the great influenza pandemics: death, panic and hysteria, 1830–1920 (London & New York: I. B. Tauris, 2014), pp. x313, £62.00/\$95.00, ISBN: 9781780764788. *Med Hist* 2016; 60: 422–424.

9. Rundfeldt C, Socala K, and Wlaz P. The atypical anxiolytic drug, tofisopam, selectively blocks phosphodiesterase isoenzymes and is active in the mouse model of negative symptoms of psychosis. *J Neural Transm (Vienna)* 2010; 117: 1319–1325.
10. Economo on encephalitis lethargica. *Lancet* 1931; 218: 362–363.
11. Kępińska AP, Iyegbe CO, Vernon AC, et al. Schizophrenia and influenza at the centenary of the 1918–1919 Spanish influenza pandemic: Mechanisms of psychosis risk. *Front Psychiatry* 2020; 11. Epub ahead of print 2020. DOI: 10.3389/fpsy.2020.00072.
12. Medvedev VE and Dogotar OA. COVID-19 and mental health: challenges and first conclusions. *Neurol Neuropsychiatry Psychosom* 2020; 12: 4–10.
13. Caan MP, Lim CT, and Howard M. A case of catatonia in a man with COVID-19. *Psychosomatics* 2020; 61: 556–560.
14. Kalashnikov SV, Kalashnikova EA, and Kokarovtseva SN. Immunomodulating effects of tofizopam (Grandaxin®) and diazepam in vitro. *Mediat Inflamm* 2002; 11: 53–59.
15. Ravan JR, Pattnaik JL, Padhy SK, et al. Tofisopam as an alternative intervention in organic catatonia: an open label study. *Indian J Psychiatry* <https://www.ncbi.nlm.nih.gov/pmc/articles/PMC6366275/>. Accessed February 7, 2021.
16. Mangot A and Murthy V. Psychiatric aspects of phosphodiesterases: an overview. *Indian J Pharmacol* 2015; 47: 594.
17. Üçel UI, Can ÖD, Özkay ÜD, et al. Antiamnesic effects of tofisopam against scopolamine-induced cognitive impairments in rats. *Pharmacol Biochem Behav* 2020; 190: 172858.
18. Cashman JR, Voelker T, Zhang H-T, et al. Dual inhibitors of phosphodiesterase-4 and serotonin reuptake. *J Med Chem* 2009; 52: 1530–1539.
19. Srivastava S, Bhatia MS, Gupta K, and Rajdev K. Current update on evidence-based literature of tofisopam. *Delhi Psychiatry J* 2014; 17: 154–159.