

Observational Study

Arthroscopic removal as an effective treatment option for intra-articular osteoid osteoma of the knee

Mihovil Plečko, Alan Mahnik, Damjan Dimnjaković, Ivan Bojanić

ORCID number: Mihovil Plečko 0000-0001-6569-9287; Alan Mahnik 0000-0003-2254-6007; Damjan Dimnjaković 0000-0002-5726-4301; Ivan Bojanić 0000-0002-4236-9637.

Author contributions: Bojanić I designed the study; Plečko M and Mahnik A participated in the acquisition of data; Plečko M, Dimnjaković D and Bojanić I analyzed the data, and drafted the initial manuscript; Mahnik A revised the article critically for important intellectual content; Plečko M, Mahnik A, Dimnjaković D and Bojanić I approved the final version of the article to be submitted.

Institutional review board statement: The study was approved by the Institutional Ethics Committee (8.1-20/187-2 No. 02/21 AG).

Informed consent statement: All participants agreed to be enrolled in the study.

Conflict-of-interest statement: The authors declare that there is no conflict of interest.

Data sharing statement: No additional data are available.

STROBE statement: The authors have read the STROBE Statement-

Mihovil Plečko, Alan Mahnik, Damjan Dimnjaković, Ivan Bojanić, Department of Orthopedic Surgery, University Hospital Centre Zagreb, Zagreb 10000, Croatia

Ivan Bojanić, Department of Orthopedic Surgery, School of Medicine, University of Zagreb, Zagreb 10000, Croatia

Corresponding author: Mihovil Plečko, MD, Doctor, Department of Orthopedic Surgery, University Hospital Centre Zagreb, Šalata 7, Zagreb 10000, Croatia. mplecko@kbc-zagreb.hr

Abstract

BACKGROUND

Intra-articular osteoid osteoma (iaOO) can be found in 5.2% up to 10% of cases. They may cause non-specific symptoms, mimicking degenerative or traumatic pathologies. If iaOO is left untreated, it may lead to severe muscle atrophy, tenderness, swelling, and limited range of motion. Therefore, surgical treatment is recommended. The main goal of surgical treatment is complete removal or destruction of iaOO.

AIM

To evaluate the efficiency of arthroscopic removal of iaOO of the knee in our cases and cases available in the literature.

METHODS

Analysis of available hospital records of four patients with iaOO of the knee treated by arthroscopic removal from August 2005 to December 2015 at our Department was performed. All patients had a diagnosis of iaOO confirmed by histopathologic analysis. Additional literature review of cases of iaOO of the knee available on PubMed and Google Scholar was made. All cases of iaOO of the knee treated by arthroscopic or arthroscopically assisted removal were reviewed in order to further evaluate the efficiency of the method.

RESULTS

The average age of patients included in our study was 23.2 (range 16-37) years. The average duration of the symptoms prior to surgery was 14.2 (range 6-24) months. All of the patients had persistent knee pain. Three patients reported worsening of pain during the night, while two reported worsening of pain during activity. Three patients reported alleviation of pain on non-steroidal anti-inflammatory drugs (NSAIDs), while one patient reported partial alleviation of pain on

checklist of items, and the manuscript was prepared and revised according to the STROBE Statement-checklist of items.

Open-Access: This article is an open-access article that was selected by an in-house editor and fully peer-reviewed by external reviewers. It is distributed in accordance with the Creative Commons Attribution NonCommercial (CC BY-NC 4.0) license, which permits others to distribute, remix, adapt, build upon this work non-commercially, and license their derivative works on different terms, provided the original work is properly cited and the use is non-commercial. See: <http://creativecommons.org/licenses/by-nc/4.0/>

Manuscript source: Invited manuscript

Specialty type: Orthopedics

Country/Territory of origin: Croatia

Peer-review report's scientific quality classification

Grade A (Excellent): 0
Grade B (Very good): 0
Grade C (Good): C
Grade D (Fair): 0
Grade E (Poor): 0

Received: February 27, 2021

Peer-review started: February 27, 2021

First decision: March 31, 2021

Revised: April 7, 2021

Accepted: July 12, 2021

Article in press: July 12, 2021

Published online: July 18, 2021

P-Reviewer: Labusca L

S-Editor: Wang JL

L-Editor: A

P-Editor: Xing YX



NSAIDs. No intraoperative complications were noted, and the postoperative period was uneventful in all patients. The patients reported immediate pain relief in the postoperative period. No recurrence of the disease was noted in any of the patients during the follow-up period of at least 24 mo. The literature review revealed 14 cases with an average age of 27.6 (range 16-48) years and onset of symptoms 27.7 (range 6-108) months prior to surgery, with recurrence of the disease noted in a single case.

CONCLUSION

Arthroscopic removal is an efficient treatment method that allows excision of iaOO that is neither insufficient nor excessive, thus avoiding disease recurrence while obtaining adequate material for histopathologic analysis.

Key Words: Osteoid osteoma; Knee; Arthroscopy; Bone diseases; Surgical procedures; Operative; Pathology; Surgical

©The Author(s) 2021. Published by Baishideng Publishing Group Inc. All rights reserved.

Core Tip: Advantages of the arthroscopic or arthroscopic assisted removal of the intra-articular osteoid osteoma of the knee are the ability to obtain adequate material for histopathologic analysis and to perform neither excessive nor insufficient excision, thus avoiding disease recurrence, as well as chondral lesions and bone necrosis.

Citation: Plečko M, Mahnik A, Dimnjaković D, Bojanić I. Arthroscopic removal as an effective treatment option for intra-articular osteoid osteoma of the knee. *World J Orthop* 2021; 12(7): 505-514

URL: <https://www.wjgnet.com/2218-5836/full/v12/i7/505.htm>

DOI: <https://dx.doi.org/10.5312/wjo.v12.i7.505>

INTRODUCTION

Osteoid osteoma (OO) is a third most common benign lesion of the bone, commonly localized in the diaphysis of long bones of the lower extremity[1]. Studies report that intra-articular OO (iaOO) can be found in 5.2% up to 10% of cases, with the knee being the third most common localization, after the hip and ankle[1,2]. In 1986, Heuijers *et al*[3] reported on a first successful arthroscopic removal of iaOO. Since then, arthroscopic removal of iaOO was frequently used in various joints, with a high success rate and a low recurrence rate[4-7]. However, despite the first-ever reported arthroscopic removal of iaOO was in the knee, only case reports can be found on this topic in the literature.

The aim of this study was to present the first case series of patients treated with arthroscopic removal of iaOO of the knee and to give a literature overview of arthroscopic and arthroscopically assisted removal of such lesions.

MATERIALS AND METHODS

Case series collection

This research has been approved by the Institutional Ethics Committee of the authors' affiliated institutions. A retrospective analysis of available hospital records revealed four consecutive patients diagnosed with OO of the knee confirmed by histopathologic analysis that were treated by arthroscopic removal from August 2005 to December 2015 at our Department. All of the patients have agreed to participate in the study. Available hospital records were reviewed in December 2020 by an independent examiner who was not involved in the treatment process. Demographic information, including age and gender, as well as clinical characteristics, such as symptoms, effects of non-steroidal anti-inflammatory drugs (NSAIDs) on pain relief, duration of the symptoms until the accurate diagnosis, history of trauma, diagnostic imaging utilized

preoperatively, intraoperative findings, results of histopathological analysis, follow-up duration and recurrence of the disease were analyzed.

Surgical technique

The senior author performed arthroscopic removal of iaOO of the knee in all patients (Table 1). Patients were in a supine position, under spinal anesthesia, with the affected knee placed in a leg holder. A tourniquet was applied in all of the procedures. Knee arthroscopy was performed with a 4.0 mm arthroscope angled at 30°. Standard anteromedial and anterolateral portals were used in all of the procedures, while in some, due to OO's localization, additional portals were utilized (Figures 1 and 2)[8,9]. After a thorough examination of the knee, a cherry-red, elevated lesion was localized, consistent with the typical appearance of the nidus. An arthroscopic curette was used to remove the nidus, and an arthroscopic grasper was used to remove the tissue, obtaining a suitable specimen for histopathologic analysis. An arthroscopic burr and curette were used to remove the remaining part of the lesion and surrounding bone sclerosis until visualizing healthy trabecular bone. Afterward, lavage of the knee was performed. Insertion of a drain through the anterolateral portal and closure of the skin at the arthroscopic portals followed.

Postoperative management

All patients followed the same postoperative regimen. On the first postoperative day, the drain was removed, and the patients started active and passive range of motion exercises. Partial weight-bearing as tolerated with crutches was advised for the first two weeks, with full weight-bearing advised afterward. During the first postoperative month, they underwent a course of physiotherapy, consisting of range of motion and strengthening exercises. The patients underwent monthly follow-up examinations for the first three postoperative months. After that, the follow-up visits were scheduled at six, twelve, and 24 mo postoperatively.

Literature review

A literature review of cases with iaOO of the knee available on PubMed and Google Scholar was made. Search strategy for PubMed included two search queries: (1) Osteoma, Osteoid[MeSH] AND Knee[MeSH]; and (2) osteoid osteoma AND knee. Search strategy for Google Scholar included one search query: osteoid osteoma AND knee. The search was performed on December 29, 2020. All results available on PubMed and the first 1000 results on Google Scholar were screened. Only cases of iaOO of the knee treated by arthroscopic or arthroscopically assisted removal were included and further reviewed in order to evaluate the efficiency of the method.

Data interpretation

Statistical analyses were performed using SPSS (version 21). Continuous variables were described as average (range minimum-maximum). The normality of distribution was tested using the Shapiro-Wilks test.

RESULTS

Demographic information, clinical presentation, preoperative and postoperative features of the patients treated by arthroscopic removal of iaOO of the knee are presented in Table 1. The average patient age was 23.2 (range 16-37) years. The average duration of the symptoms prior to surgery was 14.2 (range 6-24) months. Symptoms occurred in one patient after suffering a first-time lateral patellar dislocation, which became recurrent over time. One of the patients underwent an open biopsy performed by another physician ten months before he was referred to the senior author for re-evaluation. The biopsy was performed in an incorrect location of the bone due to an extensive bone marrow edema found on magnetic resonance imaging (MRI) in the medial femoral condyle. The result of the biopsy was negative, and patient's symptoms persisted. A detailed analysis of symptoms showed the patient had worsening of pain at night and after activity, which partially alleviated on NSAIDs. As the senior author suspected of iaOO of the knee, a bone scan and a follow-up MRI were performed that confirmed the diagnosis of iaOO. Computerized tomography (CT) was performed in other patients to better localize the lesion, thus allowing efficient preoperative planning.

Table 1 Demographic information, clinical presentation, preoperative and postoperative features of the patients treated by arthroscopic removal of intra-articular osteoid osteoma of the knee

Age (yr)/gender	Side	Symptoms	Pain alleviating on NSAIDs	Duration of symptoms until the accurate diagnosis (mo)	Trauma history	Location	Diagnostic imaging	Arthroscopic portals	HPA confirmed osteoid osteoma	Follow-up (mo)	Recurrence
16/F	L	Persistent knee pain worsening at night	Yes	15	Yes	Anterolateral part of the femur above the cartilage border of the trochlea	CT, bone scan	AM, AL, SL	Yes	171	No
23/M	L	Persistent knee pain worsening in activity and at night	Partially	24	No	Anteromedial part of the femur on the cartilage border of the trochlea	MRI (2) ¹ , bone scan	AM, AL	Yes	24	No
17/F	L	Persistent knee pain worsening in activity and at night	Yes	6	No	Anterolateral part of the femur above the cartilage border of the trochlea	MRI, CT	AM, AL, SL	Yes	55	No
37/F	R	Persistent knee pain and swelling	Yes	12	No	Posterior aspect of the lateral femoral condyle	MRI, CT, bone scan	AM, AL, PM, PL	Yes	24	No

¹Patient had a first magnetic resonance imaging (MRI) performed, after which another physician performed an open biopsy at our department. As the symptoms persisted over the course of 10 mo, the patient was referred to the senior author to re-evaluate the case. After detailed analysis, the senior author suspected of intra-articular osteoid osteoma (iaOO) of the knee and issued a bone scan and a follow-up MRI, which confirmed the diagnosis of iaOO of the knee. NSAIDs: Non-steroidal anti-inflammatory drugs; HPA: Histopathologic analysis; F: Female; M: Male; CT: Computerized tomography; MRI: Magnetic resonance imaging; AM: Anteromedial; AL: Anterolateral; SL: Superolateral; PM: Posteromedial; PL: Posterolateral.

No intraoperative complications were noted, and the postoperative period was uneventful in all patients. The patients reported immediate pain relief in the postoperative period. No recurrence of the disease was noted in any of the patients during the follow-up period of at least 24 mo.

The literature review revealed 14 cases of iaOO of the knee treated by arthroscopic or arthroscopically assisted removal, which are presented in Table 2[1,3,10-20]. The average age of those patients was 27.6 (range 16-48) years, the average onset of symptoms was 27.7 (range 6-108) mo prior to surgery, and recurrence of the disease was noted in a single case.

DISCUSSION

This article reports on a successful treatment of iaOO of the knee using arthroscopy. Patients suffering from iaOO usually have non-specific and variable symptoms, different from the classic night pain relieved by NSAIDs found in extra-articular OOs [21]. Such clinical presentation may mislead the clinician to suspect other more common knee pathologies such as meniscal or chondral lesions[15]. A study of patients with OO that presented with knee pain showed that in 60% of them, OO was located adjacent to the hip or in the middle femoral shaft instead of the knee[22]. Moreover, some authors suggest that the worsening of pain during the night in iaOO is not typical as for extra-articular OOs[21,23,24]. However, in more than 80% of reviewed cases and three of our cases, patients complained of worsening pain during the night. Furthermore, Spiker *et al*[7] reviewed cases of iaOO of the hip and showed that in cases that recorded the presence of pain during the night, 83.3% reported

Table 2 Literature review of cases with intra-articular osteoid osteoma of the knee treated by arthroscopic or arthroscopically assisted removal

Ref.	Age (yr) /gender	Side	Symptoms	Pain alleviating on NSAIDs	Duration of symptoms until the accurate diagnosis (mo)	Trauma history	Location	Diagnostic imaging	Surgery	HPA confirmed osteoid osteoma	Follow-up (mo)	Recurrence
Heuijers <i>et al</i> [3], 1986	29/F	NR	Knee pain, limited ROM	NR	108	NR	Lateral tibial plateau	NR	Arthroscopic removal	Yes	18	No
Franceschi <i>et al</i> [13], 2005	28/M	NR	Light knee pain worsening at night, swelling, limited ROM	Yes	12	NR	Lateral tibial plateau	MRI, CT	Arthroscopically assisted removal – percutaneous K wire insertion to the tumor under CT, arthroscopic visualization of the knee, tumor removal by a core reamer and curettage, bone defect filled with autologous bone graft from proximal tibia	Yes	24	No
Franceschi <i>et al</i> [14], 2008	16/F	L	Light knee pain worsening at night, swelling, limited ROM	Yes	NR	NR	Central region of the patella	MRI, CT, bone scan	Arthroscopically assisted removal – percutaneous K wire insertion to the tumor under CT, arthroscopic visualization of the knee, tumor removal by a hollow drill and curettage, bone defect filled with autologous bone graft from proximal tibia	Yes	36	No
Abnoui <i>et al</i> [15], 2008	35/M	L	Diffuse dull knee pain worsening on activity, limited ROM, swelling	Partially	24	No	Medial femoral condyle	MRI, CT	Arthroscopically assisted removal – arthroscopic visualization of the tumor and <i>en-bloc</i> resection via miniature arthrotomy	Yes	22	No
Gunes <i>et al</i> [16], 2008	18/M	R	Knee pain worsening at night	Yes	6	NR	Medial femoral condyle	MRI, CT	Arthroscopic removal	Yes	15	No
Furukawa <i>et al</i> [17], 2011	23/F	L	Persistent knee painworsening at night, swelling	Partially	24	NR	Lateral femoral condyle	MRI, CT, bone scan	Arthroscopic removal	Yes	24	No
Saeed <i>et al</i> [18], 2011	38/M	L	Mild knee pain worsening at night	Yes	26	NR	Lateral tibial plateau	MRI, CT, bone scan	Arthroscopic removal	Yes	72	Yes ¹
Adachi <i>et al</i> [19], 2014	32/M	L	Severe knee pain, worsening at night, limited ROM	Partially	NR	No	Lateral tibial plateau	MRI	Arthroscopically assisted removal – arthroscopic visualization of the tumor, insertion of a K wire in the tumor under fluoroscopy and removal with core reamer, bone defect filled with artificial bone	Yes	18	No
Kang <i>et al</i> [20], 2016	20/F	R	Mild knee pain worsening at night	No	12	No	Lateral femoral condyle	MRI, CT, bone scan	Arthroscopic removal	Yes	24	No
Rolvien <i>et al</i> [1], 2016	26/M	NR	Knee pain worsening at night	Yes	24	No	Lateral tibial plateau	MRI, CT	Arthroscopic removal	Yes	3	No
Krause <i>et al</i> [10], 2016	26/M	NR	Knee pain worsening at night	Partially	19	NR	Lateral tibial plateau	MRI, CT	Arthroscopic removal	Yes	3	No
Rolvien <i>et al</i>	48/M	R	Persistent knee pain	Yes	24	NR	Lateral	MRI, CT	Arthroscopic removal	Yes	NR	NR

[11], 2019							femoral condyle						
Monroe <i>et al</i> [12], 2019	20/M	R	Knee pain worsening in activity	No	18	No	Medial femoral trochlea	MRI, CT	Arthroscopic removal – bone defect filled with allograft	Yes	84	No	
	28/M	R	Persistent knee pain	Partially	36	NR	Medial femoral condyle	MRI, CT	Arthroscopically assisted removal – arthroscopic visualization of the tumor and removal <i>via</i> small arthrotomy, bone defect filled with allograft	Yes	6	No	

¹Six years following the arthroscopic removal, the patient had similar symptoms, and the follow-up imaging revealed recurrence of the osteoid osteoma at the same location. Another arthroscopic removal could cause extensive damage of the lateral tibial plateau, and to avoid such complication, the authors decided to perform an unicondylar knee arthroplasty. HPA: histopathologic analysis, NSAIDs: Non-steroidal anti-inflammatory drugs; NR: Not reported; F: Female; M: Male; MRI: Magnetic resonance imaging; CT: Computerized tomography; K: Kirschner; ROM: Range of motion.

positive. Also, Allen *et al*[23] report that iaOOs are less responsive to NSAIDs than extra-articular OO. Spiker *et al*[7] report that in iaOO of the hip in cases which recorded the effect of NSAIDs on pain, 69.7% reported alleviation of pain on NSAIDs. From cases of iaOO of the knee that recorded the effect of NSAIDs, 84.6% reported on either partial or complete alleviation of pain on NSAIDs[1,3,10-20].

Szendroi *et al*[2] state that plain radiographs were sufficient for diagnosis of iaOO prior to surgery in 36.8%, compared to 73.3% for diagnosis of extra-articular OOs. Furthermore, Papagrigorakis *et al*[25] state that when the first symptoms occur in iaOO patients, over 80% of patients have no visible nidus or sclerosis on plain radiographs. Therefore, further diagnostic imaging is often needed. As clinicians commonly suspect other more common knee pathologies, MRI is usually issued as a diagnostic procedure after obtaining plain radiographs. MRI may be useful in obtaining a correct diagnosis. However, joint effusion, bone edema, and soft tissue edema are frequently present and may mask the nidus[17,26]. Furthermore, Allen *et al*[23] note that the nidus is either not visible or poorly visible in 50% of iaOOs on MRI. Moreover, Bhure *et al*[27] reported that MRI may lead to misdiagnosis in up to 35% of cases if used as a solitary diagnostic procedure. Therefore, MRI findings combined with non-specific symptoms may mimic conditions such as osteomyelitis or malignant bone tumors[28]. Such a case occurred in one of our patients, who underwent an open biopsy performed in the incorrect location on the bone, resulting in persistence of symptoms and delay in diagnosis.

If MRI does not confirm iaOO, further diagnostic imaging is issued. A bone scan proved to be useful in diagnosing iaOO. It lacks the usual “double-density” sign seen in extra-articular OOs, but it presents with increased focal uptake matching with the localization of the nidus[23]. When the localization is found, a CT scan may be performed. Assoun *et al*[26] report that CT scan proved to be more accurate than MRI in detection of the nidus in 63% of cases. Also, CT scans proved to be a valuable tool in preoperative planning of the surgery[29]. Therefore, we have performed a CT scan in three of our patients.

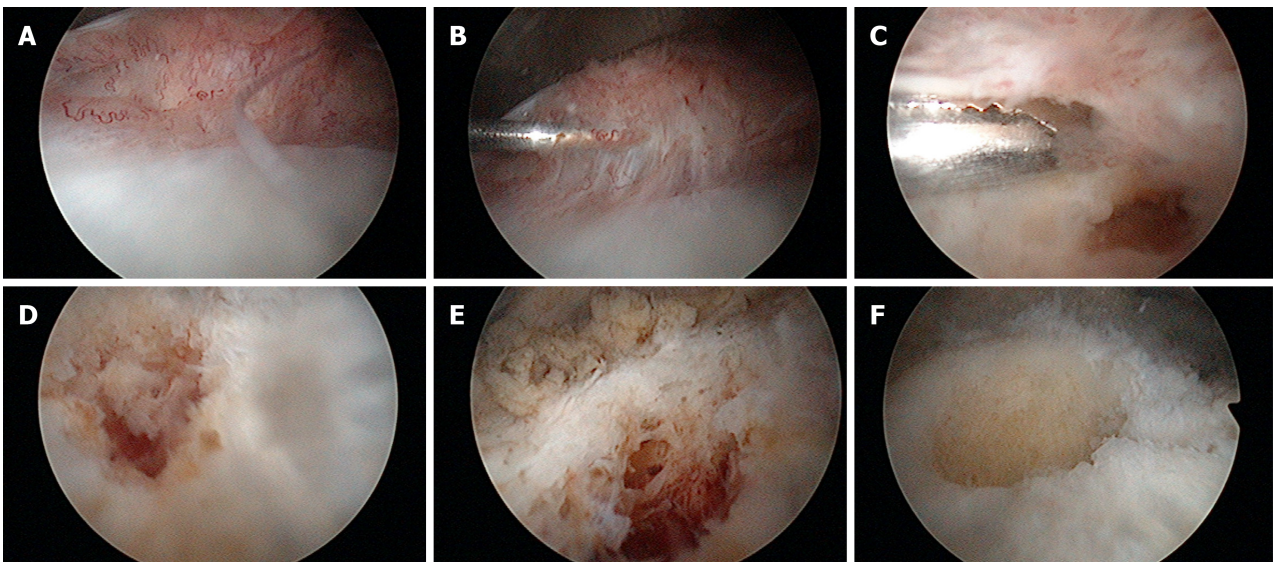


Figure 1 Sequential arthroscopic views of the anteromedial part of the femur above the cartilage with the arthroscope in the anterolateral portal. A: synovial hyperplasia; B: Palpation of the elevated synovial tissue with a probe; C: Removal of the synovial tissue reveals the altered tissue; D and E: After partial removal, the extensiveness of the altered tissue is revealed; F: The remaining crater after complete removal of the lesion.

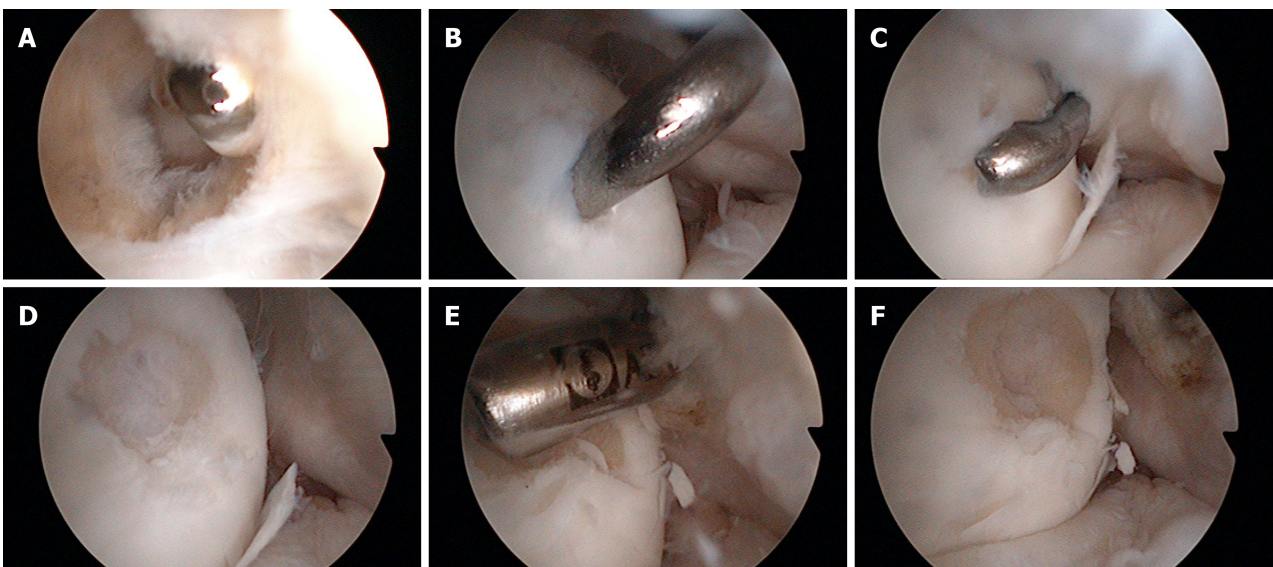


Figure 2 Sequential arthroscopic views of posterior part of lateral femoral condyle with the arthroscope positioned in the posteromedial portal. A: Trans-septal approach; B: Palpation of the altered tissue with a probe from the posterolateral portal; C: Removal of the altered tissue with a cochlea; D: Visualization of the sclerotic bone after removal of altered tissue; E: Removal of the nidus and surrounding sclerosis with a motorized instrument; F: The remaining crater after complete removal of the lesion.

Peculiarities of the clinical presentation and diagnostic imaging of iaOOs lead to a significant delay in diagnosis in comparison to extra-articular OOs. Rolvien *et al*[1] report that the mean time for a correct diagnosis of iaOO was 20.7 mo, while Szendroi *et al*[2] state that the mean time for diagnosing extra-articular OO was 8.5 mo in comparison to 26.6 mo for iaOO. When considering the duration of symptoms of iaOO of the knee, the average duration until obtaining a diagnosis in our patients was 14.2 mo (range 6-24), while of those we have analyzed from the literature was 27.7 mo (range 6-108)[1,3,10-20]. The symptoms duration in our patients is somewhat shorter than reported in the literature. However, due to the small number of cases we report, we consider that the actual delay in diagnosis is usually closer to the average expressed from the analyzed literature.

Nowadays, the treatment of choice for extra-articular OOs is the CT-guided radiofrequency ablation (RFA), with a success rate of up to 97%[10]. However, the treatment of iaOO with RFA requires certain precautions, as this method may cause a

cortical and bone marrow necrosis of up to 1.3 cm in diameter[30]. As iaOO may be located close to the cartilage and other joint tissues, this may be the limiting factor for the use of RFA. Another minimally invasive method that proved to be efficient is the CT-guided percutaneous resection[14]. However, percutaneous resection may result in cutaneous necrosis, neurapraxia, osteomyelitis, and fractures[14]. Furthermore, these methods are often unable to provide a sufficient sample for the histopathologic analysis[17].

The most significant concerns of arthroscopic removal of iaOO are the difficulty of localization of the lesion intraoperatively and the possibility of recurrence due to incomplete excision. However, with adequate preoperative planning, the advantage of great visualization allowed by 30° and 70° arthroscopes, and possible intraoperative fluoroscopic assessment, we believe no difficulties in localizing iaOO should occur. So far, for only one arthroscopically treated case of iaOO of the knee recurrence of the disease was reported, meaning the success rate of this method is 94.4%[1,3,10-20]. The success rate of arthroscopic removal of iaOO in the ankle is 96%, in the upper extremity is 93.8%, while in the hip is 100%[4-7]. Advantages of the arthroscopic removal are the ability to obtain adequate material for histopathologic analysis and to perform an excision of iaOO that would neither be insufficient nor excessive, thus avoiding both recurrence of the disease, as well as chondral lesions and bone necrosis. As Furukawa *et al*[17] note, arthroscopic removal is at least as effective as CT-guided methods for both localizing and removal of the lesion.

Localization of iaOO in our case series was on the femur exclusively, with 3 cases proximal to the superior cartilage border of the trochlea and one case in the posterior part of the lateral femoral condyle (Table 1). On the contrary, seven cases from the literature report that iaOO was localized on the femoral side, six were on the tibial side, and one was in the patella (Table 2)[1,3,10-20]. However, due to the relatively small number of cases, it is difficult to pinpoint the typical localization of the iaOO in the knee.

This study has shown the efficiency of arthroscopic removal of iaOO of the knee. However, its retrospective nature presents a limitation. Furthermore, we have not compared our results with open surgical treatment or removal of OO in other locations, as these also represent the limitations of this study. Due to a small number of cases in our study, as well as limited availability of more valued study designs in the literature, we did not find it justified to compare our results with arthroscopic treatment of iaOO in other locations, which have much larger case series. This suggests that only uncommon and novel cases of iaOO of the knee have been published, and further research will additionally clarify peculiarities of this pathology. Moreover, a possible limitation to the study is that no follow-up diagnostic imaging was performed. However, it is suggested that follow-up diagnostic imaging should be performed only in patients with a thorough suspicion of a recurrence of OO. Therefore, as our patients were all symptom-free during follow-up, we believed no diagnostic imaging is needed.

CONCLUSION

Our case series, as well as the literature review, suggest that arthroscopic removal is an efficient and safe method of treatment in patients with intra-articular osteoid osteoma of the knee. It enables excision of the tumor that is neither insufficient nor excessive, thus avoiding both recurrence of the disease, as well as chondral lesions and bone necrosis, while obtaining adequate material for histopathologic analysis. Therefore, arthroscopic removal should be considered as a treatment option when dealing with this rare entity.

ARTICLE HIGHLIGHTS

Research background

Intra-articular osteoid osteoma of the knee is a rare entity that may present with non-specific symptoms and may lead to severe disability if left untreated. There are several treatment options, one of which is arthroscopic removal.

Research motivation

As there is a low number of reported cases of intra-articular osteoid osteoma of the

knee, our goal was to report our results and further elaborate on the results available in the literature.

Research objectives

To analyze whether arthroscopic removal is an effective treatment option for intra-articular osteoid osteoma of the knee.

Research methods

A first case series ever of such patients was reported, as well as the review of all available cases in the literature that report on the same pathology and treatment options.

Research results

Both the case series and cases from the literature report that arthroscopic removal of intra-articular osteoid osteoma is an effective treatment option with a low chance for recurrence of the disease.

Research conclusions

Arthroscopic removal of intra-articular osteoid osteoma enables excision that is neither insufficient nor excessive, thus avoiding both recurrence of the disease, as well as chondral lesions and bone necrosis, while obtaining adequate material for histopathologic analysis. Therefore, it should be considered as a treatment option if physicians come across such a case.

Research perspectives

Future research will additionally clarify the efficiency of arthroscopic removal of intra-articular osteoid osteoma, possibly on a larger case series than reported in this article and in the literature so far.

REFERENCES

- 1 **Rolvien T**, Zustin J, Mussawy H, Schmidt T, Pogoda P, Ueblacker P. Intra-articular osteoid osteoma as a differential diagnosis of diffuse mono-articular joint pain. *BMC Musculoskelet Disord* 2016; **17**: 455 [PMID: 27809832 DOI: 10.1186/s12891-016-1313-3]
- 2 **Szendroi M**, Köllö K, Antal I, Lakatos J, Szoke G. Intraarticular osteoid osteoma: clinical features, imaging results, and comparison with extraarticular localization. *J Rheumatol* 2004; **31**: 957-964 [PMID: 15124257]
- 3 **Heuijers W**, Dandy DJ, Harris D. Arthroscopic excision of an intra-articular osteoid osteoma at the knee. *Arthroscopy* 1986; **2**: 215-216 [PMID: 3801099 DOI: 10.1016/s0749-8063(86)80074-3]
- 4 **Ge SM**, Marwan Y, Abduljabbar FH, Morelli M, Turcotte RE. Arthroscopic management of intra- and juxta-articular osteoid osteoma of the upper extremity: a systematic review of the literature. *Eur J Orthop Surg Traumatol* 2020; **30**: 1333-1344 [PMID: 32504238 DOI: 10.1007/s00590-020-02710-6]
- 5 **Ge SM**, Marwan Y, Addar A, Algarni N, Chaytor R, Turcotte RE. Arthroscopic Management of Osteoid Osteoma of the Ankle Joint: A Systematic Review of the Literature. *J Foot Ankle Surg* 2019; **58**: 550-554 [PMID: 30910487 DOI: 10.1053/j.jfas.2018.10.001]
- 6 **Marwan YA**, Abatzoglou S, Esmacel AA, Alqahtani SM, Alsulaimani SA, Tanzer M, Turcotte RE. Hip arthroscopy for the management of osteoid osteoma of the acetabulum: a systematic review of the literature and case report. *BMC Musculoskelet Disord* 2015; **16**: 318 [PMID: 26497395 DOI: 10.1186/s12891-015-0779-8]
- 7 **Spiker AM**, Rotter BZ, Chang B, Mintz DN, Kelly BT. Clinical presentation of intra-articular osteoid osteoma of the hip and preliminary outcomes after arthroscopic resection: a case series. *J Hip Preserv Surg* 2018; **5**: 88-99 [PMID: 29423256 DOI: 10.1093/jhps/hnx042]
- 8 **Schreiber SN**. Arthroscopy update #9. Posterior compartment observation and instrumentation in the knee using anteromedial and anterolateral portals and an interchangeable cannula system. *Orthop Rev* 1991; **20**: 67-68, 73, 76 [PMID: 1997957]
- 9 **Ahn JH**, Ha CW. Posterior trans-septal portal for arthroscopic surgery of the knee joint. *Arthroscopy* 2000; **16**: 774-779 [PMID: 11027767 DOI: 10.1053/jars.2000.7681]
- 10 **Krause M**, Oheim R, Meenen NM, Frosch KH, Amling M. Intra-articular osteoid osteoma in the proximal tibia and its imaging characteristics. *Knee* 2016; **23**: 915-919 [PMID: 27288066 DOI: 10.1016/j.knee.2016.05.005]
- 11 **Rolvien T**, Krause M, Zustin J, Yastrebov O, Oheim R, Barvencik F, Frosch KH, Amling M. Intra-articular osteoid osteoma accompanied by extensive bone marrow edema. A clinical and micro-morphological analysis. *J Bone Oncol* 2019; **18**: 100256 [PMID: 31497501 DOI: 10.1016/j.jbo.2019.100256]
- 12 **Monroe EJ**, Chambers CC, Davoodian A, Cho SJ, Motamedi D, Allen CR. Intra-articular Osteoid

- Osteoma of the Distal Femur Treated with Osteochondral Grafting: A Report of 2 Cases. *JBJS Case Connect* 2019; **9**: e0211 [PMID: 31211746 DOI: 10.2106/JBJS.CC.18.00211]
- 13 **Franceschi F**, Marinozzi A, Rizzello G, Papalia R, Rojas M, Denaro V. Computed tomography-guided and arthroscopically controlled en bloc retrograde resection of a juxta-articular osteoid osteoma of the tibial plateau. *Arthroscopy* 2005; **21**: 351-359 [PMID: 15756191 DOI: 10.1016/j.arthro.2004.10.004]
 - 14 **Franceschi F**, Longo UG, Ruzzini L, Marinozzi A, Rizzello G, Papalia R, Denaro V. En-bloc retrograde resection of an osteoid osteoma of the patella using computed tomography under arthroscopic control. *J Knee Surg* 2008; **21**: 136-140 [PMID: 18500065 DOI: 10.1055/s-0030-1247808]
 - 15 **Abnousi F**, Saliman JD, Fanton GS. Arthroscopic visualization and assisted excision of osteoid osteoma at the knee: a case report and review. *Am J Sports Med* 2008; **36**: 375-378 [PMID: 17878430 DOI: 10.1177/0363546507307865]
 - 16 **Gunes T**, Erdem M, Bostan B, Sen C, Sahin SA. Arthroscopic excision of the osteoid osteoma at the distal femur. *Knee Surg Sports Traumatol Arthrosc* 2008; **16**: 90-93 [PMID: 17609930 DOI: 10.1007/s00167-007-0380-2]
 - 17 **Furukawa M**, Anazawa U, Horiuchi K, Yabe H, Morioka H, Mukai M, Toyoda T, Chiba K, Morii T, Shiraishi T, Toyama Y. Arthroscopic removal of intra-articular osteoid osteoma in the knee: case report and review of the literature. *J Orthop Sci* 2011; **16**: 321-325 [PMID: 21431904 DOI: 10.1007/s00776-011-0060-4]
 - 18 **Saeed MZ**, Saragaglia D. Unicondylar knee replacement for intra-articular osteoid osteoma of the tibial plateau. *Eur Orthop Traumatol* 2011; **2**: 157-160 [DOI: 10.1007/s12570-011-0082-6]
 - 19 **Adachi N**, Shimose S, Nakamae A, Okuhara A, Kamei G, Ochi M. Intra-articular osteoid osteoma of the lateral tibial plateau treated with arthroscopically assisted removal and retrograde osteochondral grafting. *Knee* 2014; **21**: 343-348 [PMID: 24012309 DOI: 10.1016/j.knee.2013.08.005]
 - 20 **Kang S**, Kim YS, Lee HM, Lee MY, Kim JP. Arthroscopic Excision of an Intraarticular Osteoid Osteoma in the Distal Femur. *Clin Orthop Surg* 2016; **8**: 475-480 [PMID: 27904732 DOI: 10.4055/cios.2016.8.4.475]
 - 21 **García-Germán D**, Sánchez-Gutiérrez S, Bueno A, Carballo F, López-González D, Canillas F, Martel J. Intra-articular osteoid osteoma simulating a painful fabella syndrome. *Knee* 2010; **17**: 310-312 [PMID: 20346681 DOI: 10.1016/j.knee.2010.02.008]
 - 22 **Georgoulis AD**, Papageorgiou CD, Moebius UG, Rossis J, Papadonikolakis A, Soucacos PN. The diagnostic dilemma created by osteoid osteoma that presents as knee pain. *Arthroscopy* 2002; **18**: 32-37 [PMID: 11774139 DOI: 10.1053/jars.2002.30010]
 - 23 **Allen SD**, Saifuddin A. Imaging of intra-articular osteoid osteoma. *Clin Radiol* 2003; **58**: 845-852 [PMID: 14581007 DOI: 10.1016/s0009-9260(03)00213-7]
 - 24 **Eggel Y**, Theumann N, Lüthi F. Intra-articular osteoid osteoma of the knee: clinical and therapeutical particularities. *Joint Bone Spine* 2007; **74**: 379-381 [PMID: 17574894 DOI: 10.1016/j.jbspin.2006.10.007]
 - 25 **Papagrigorakis E**, Benetos IS, Bakalakos M, Rozis M, Pneumaticos S. A Rare Cause of Anterior Knee Pain in a Young Athlete and a Delayed Diagnosis: Osteoid Osteoma of the Patella. *Cureus* 2019; **11**: e6420 [PMID: 31988821 DOI: 10.7759/cureus.6420]
 - 26 **Assoun J**, Richardi G, Railhac JJ, Baunin C, Fajadet P, Giron J, Maquin P, Haddad J, Bonneville P. Osteoid osteoma: MR imaging versus CT. *Radiology* 1994; **191**: 217-223 [PMID: 8134575 DOI: 10.1148/radiology.191.1.8134575]
 - 27 **Bhure U**, Roos JE, Strobel K. Osteoid osteoma: multimodality imaging with focus on hybrid imaging. *Eur J Nucl Med Mol Imaging* 2019; **46**: 1019-1036 [PMID: 30341641 DOI: 10.1007/s00259-018-4181-2]
 - 28 **Chai JW**, Hong SH, Choi JY, Koh YH, Lee JW, Choi JA, Kang HS. Radiologic diagnosis of osteoid osteoma: from simple to challenging findings. *Radiographics* 2010; **30**: 737-749 [PMID: 20462991 DOI: 10.1148/rg.303095120]
 - 29 **Sagtas E**, Gokkus K, Aydin AT. Intra-Articular Osteoid Osteoma as a Cause of Anteromedial Knee Pain. *Case Rep Orthop* 2017; **2017**: 5846368 [PMID: 28540096 DOI: 10.1155/2017/5846368]
 - 30 **Tillotson CL**, Rosenberg AE, Rosenthal DI. Controlled thermal injury of bone. Report of a percutaneous technique using radiofrequency electrode and generator. *Invest Radiol* 1989; **24**: 888-892 [PMID: 2807804 DOI: 10.1097/00004424-198911000-00009]



Published by **Baishideng Publishing Group Inc**
7041 Koll Center Parkway, Suite 160, Pleasanton, CA 94566, USA

Telephone: +1-925-3991568

E-mail: bpgoffice@wjgnet.com

Help Desk: <https://www.f6publishing.com/helpdesk>

<https://www.wjgnet.com>

