



Since January 2020 Elsevier has created a COVID-19 resource centre with free information in English and Mandarin on the novel coronavirus COVID-19. The COVID-19 resource centre is hosted on Elsevier Connect, the company's public news and information website.

Elsevier hereby grants permission to make all its COVID-19-related research that is available on the COVID-19 resource centre - including this research content - immediately available in PubMed Central and other publicly funded repositories, such as the WHO COVID database with rights for unrestricted research re-use and analyses in any form or by any means with acknowledgement of the original source. These permissions are granted for free by Elsevier for as long as the COVID-19 resource centre remains active.



Correspondence

Pneumothorax and barotrauma in invasively ventilated patients with COVID-19



ARTICLE INFO

Keywords

Coronavirus disease 2019
Macklin effect
Acute respiratory distress syndrome
Mechanical ventilation
Pneumothorax
Pneumomediastinum
Barotrauma

Dear Editor,

We read with great interest the article by Chopra et al. recently published on *Respiratory Medicine* [1].

In their multicenter study, the Authors present incidence, clinical characteristics and outcome of pneumothorax in critically ill patients with coronavirus disease 2019 (COVID-19). They found that pneumothorax rate among invasively ventilated COVID-19 patients is 80/594 (13%), and mortality rate for patients who developed pneumothorax is 50/80 (62%). On the contrary, among 160 randomly selected invasively ventilated COVID-19 patients without pneumothorax, mortality was 78/160 (49%).

We recently published a systematic review on rate of barotrauma among invasively ventilated COVID-19 patients [2]. Our pooled analysis included data from 13 studies and 1814 patients [3–15] and we found that pooled estimate of pneumothorax rate was 10.7% (95% confidence interval [CI] = 6.7%–14.7%), while overall rate of barotrauma event was 16.1% (95% CI = 11.8%–20.4%). In addition, we found an overall mortality rate for COVID-19 patients who developed barotrauma of 61.6% (95% CI = 50.2%–73.0%), as compared with a mortality of 49.5% (95% CI = 41.1%–58.0%) for COVID-19 patients who did not develop barotrauma.

We are pleased to read that our findings are further reinforced by another study, that confirms that pneumothorax rate among mechanically ventilated COVID-19 patients is between 10 and 15%. Indeed, after including the study by Chopra et al. in an updated meta-analysis, the pooled pneumothorax rate is 11.1% (95% CI = 7.4%–14.8%) (Fig. 1), while the overall barotrauma rate is 15.4% (95% CI = 11.7%–19%) (Fig. 2). Furthermore, the study by Chopra et al. also confirms a mortality rate above 60% for COVID-19 patients with barotrauma

(updated pooled estimate = 61.4%; 95% CI = 52.1%–70.7%) (Fig. 3), as compared with a mortality lower than 50% for patients who did not develop barotrauma (updated pooled estimate = 49.5%; 95% CI = 42.8%–52.3%) (Fig. 4).

Collectively, these data confirm that barotrauma occur frequently in COVID-19 patients requiring mechanical ventilation, and is associated with a worse outcome and a very high mortality risk. Interestingly, the study by Chopra et al. is one of the few studies that identified worse lung mechanics at start of mechanical ventilation as a risk factor for development of barotrauma [2]. Most of previously published studies reported no significant differences among mechanical ventilation settings/parameters between patients who developed barotrauma and those who did not. They also found a trend towards lower age and higher use of steroids in pneumothorax patients, which were also suggested by other Authors [2,16].

Interestingly, in a recent study by our group, we identified Macklin-like radiological sign [17,18] detected on chest computed tomography (CT) scan as potential predictor of subsequent development of barotrauma about 12 days in advance [3].

Considering the high mortality rate associated with development of barotrauma in COVID-19 patients, and the ongoing debate on optimal timing of intubation in these patients [19–21], we believe that it might be justified to avoid intubation in patients with Macklin-like radiological sign on chest CT, and prefer early support with alternative techniques including awake prone positioning and extracorporeal membrane oxygenation [22–25].

Funding

None.

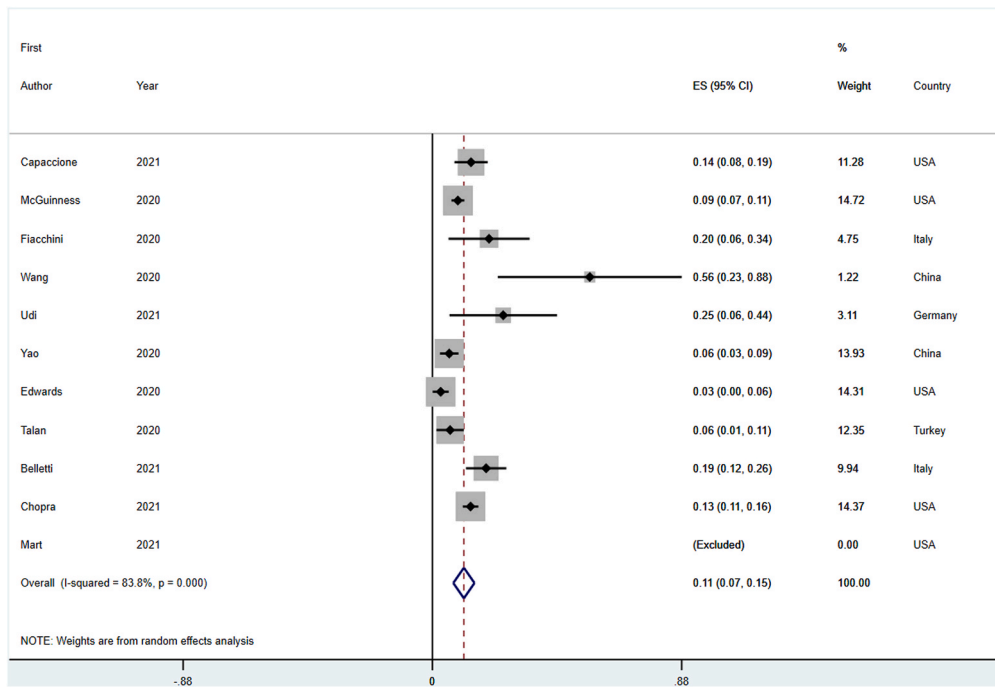


Fig. 1. Forest plot for pneumothorax development in invasively ventilated COVID-19 patients.

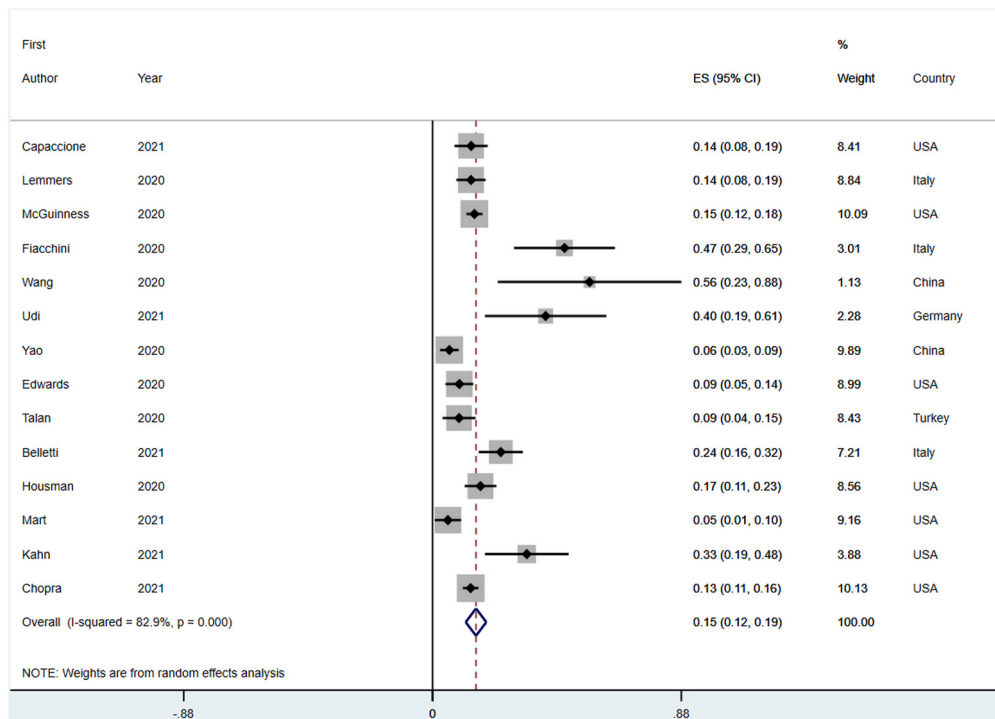


Fig. 2. Forest plot for barotrauma development in invasively ventilated COVID-19 patients.

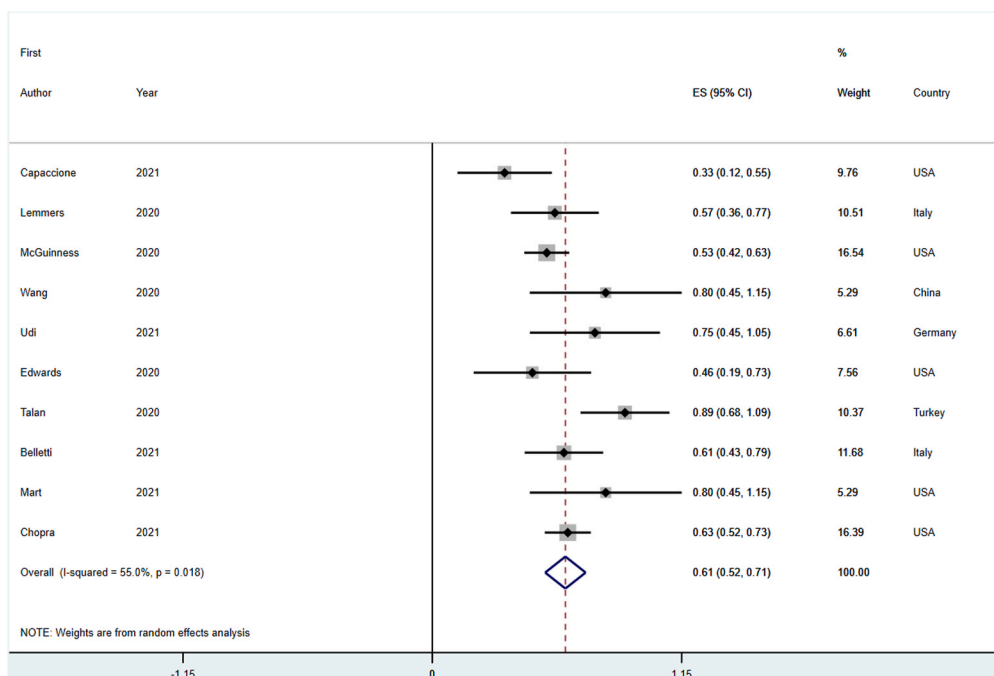


Fig. 3. Forest plot for longest follow-up mortality in invasively ventilated COVID-19 patients who developed barotrauma.

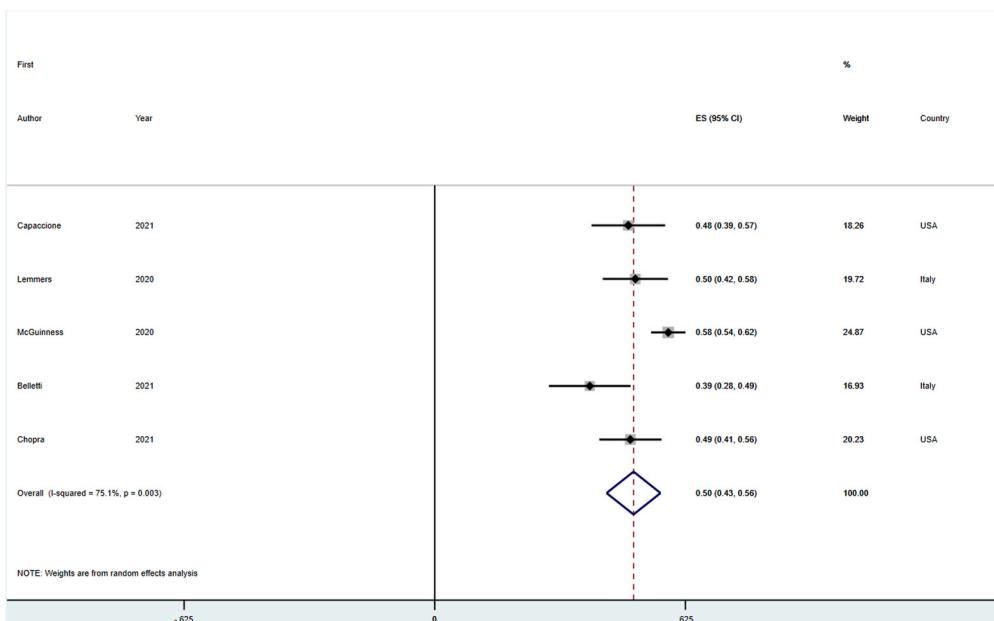


Fig. 4. Forest plot for longest follow-up mortality in invasively ventilated COVID-19 patients who did not develop barotrauma.

Declaration of competing interest

None.

Acknowledgements

None.

References

[1] A. Chopra, A.H. Al-Tarbsheh, N.J. Shah, et al., Pneumothorax in critically ill patients with COVID-19 infection: incidence, clinical characteristics and outcomes in a case control multicenter study, *Respir Med* 184 (2021), 106464, <https://doi.org/10.1016/j.rmed.2021.106464>.

[2] A. Belletti, G. Todaro, G. Valsecchi, et al., Barotrauma in COVID-19 patients undergoing invasive mechanical ventilation: a systematic literature review, *Crit Care Med* (2021), <https://doi.org/10.1097/CCM.00000000000005283>. In press.

[3] A. Belletti, D. Palumbo, A. Zangrillo, et al., Predictors of pneumothorax/pneumomediastinum in mechanically ventilated COVID-19 patients, *J Cardiothorac Vasc Anesth* (2021), <https://doi.org/10.1053/j.jvca.2021.02.008>. In press.

[4] K.M. Capaccione, B. D'souza, J. Leb, et al., Pneumothorax rate in intubated patients with COVID-19, *Acute Crit Care* 36 (1) (2021) 81–84, <https://doi.org/10.4266/acc.2020.00689>.

[5] D.H.L. Lemmers, M. Abu Hilal, C. Bnà, et al., Pneumomediastinum and subcutaneous emphysema in COVID-19: barotrauma or lung frailty? *ERJ Open Res* 6 (4) (2020) <https://doi.org/10.1183/23120541.00385-2020>, 00385-02020.

[6] G. Fiacchini, D. Tricò, A. Ribecchini, et al., Evaluation of the incidence and potential mechanisms of tracheal complications in patients with COVID-19, *JAMA Otolaryngol Neck Surg* 147 (1) (2021) 70–76, <https://doi.org/10.1001/jamaoto.2020.4148>.

- [7] L. Talan, F.G. Şaşal Solmaz, U. Ercan, et al., COVID-19 pneumonia and pneumothorax: case series, *Tuberk Toraks* 68 (4) (2020) 437–443, <https://doi.org/10.5578/tt.70355>.
- [8] J. Udi, C.N. Lang, V. Zotzmann, et al., Incidence of barotrauma in patients with COVID-19 pneumonia during prolonged invasive mechanical ventilation – a case-control study, *J Intensive Care Med* 36 (4) (2021) 477–483, <https://doi.org/10.1177/0885066620954364>.
- [9] W. Yao, T. Wang, B. Jiang, et al., Emergency tracheal intubation in 202 patients with COVID-19 in Wuhan, China: lessons learnt and international expert recommendations, *Br J Anaesth* 125 (1) (2020) e28–e37, <https://doi.org/10.1016/j.bja.2020.03.026>.
- [10] X. Wang, J. Duan, X. Han, et al., High incidence and mortality of pneumothorax in critically ill patients with COVID-19, *Heart Lung* 50 (1) (2021) 37–43, <https://doi.org/10.1016/j.hrtlng.2020.10.002>.
- [11] B. Housman, A. Jacobi, A. Carollo, et al., COVID-19 ventilator barotrauma management: less is more, *Ann Transl Med* 8 (23) (2020), 1575, <https://doi.org/10.21037/atm-20-3907>.
- [12] G. McGuinness, C. Zhan, N. Rosenberg, et al., Increased incidence of barotrauma in patients with COVID-19 on invasive mechanical ventilation, *Radiology* 297 (2) (2020) E252–E262, <https://doi.org/10.1148/RADIOLOGY.2020202352>.
- [13] M.F. Mart, S.G. Norfolk, L.N. Flemmons, et al., Pneumomediastinum in acute respiratory distress syndrome from COVID-19, *Am J Respir Crit Care Med* 203 (2) (2021) 237–238, <https://doi.org/10.1164/rccm.202008-3376IM>.
- [14] M.R. Kahn, R.L. Watson, J.T. Thetford, J.I. Wong, N. Kamangar, High incidence of barotrauma in patients with severe coronavirus disease 2019, *J Intensive Care Med* 36 (6) (2021) 646–654, <https://doi.org/10.1177/0885066621989959>.
- [15] J.A. Edwards, I. Breitman, J. Bienstock, et al., Pulmonary barotrauma in mechanically ventilated coronavirus disease 2019 patients: a case series, *Ann Med Surg* 61 (2021) 24–29, <https://doi.org/10.1016/j.amsu.2020.11.054>.
- [16] D. Palumbo, C. Campochiaro, A. Belletti, et al., Pneumothorax/pneumomediastinum in non-intubated COVID-19 patients: differences between first and second Italian pandemic wave, *Eur J Intern Med* 88 (2021) 144–146, <https://doi.org/10.1016/j.ejim.2021.03.018>.
- [17] C.C. Macklin, Transport of air along sheaths of pulmonic blood vessels from alveoli to mediastinum: clinical implications, *Arch Intern Med* 64 (5) (1939) 913–926, <https://doi.org/10.1001/archinte.1939.00190050019003>.
- [18] S. Murayama, S. Gibo, Spontaneous pneumomediastinum and Macklin effect: overview and appearance on computed tomography, *World J Radiol* 6 (11) (2014) 850–854, <https://doi.org/10.4329/wjr.v6.i11.850>.
- [19] Siempos, E. Xourgia, T.K. Ntaidou, et al., Effect of early vs. Delayed or No intubation on clinical outcomes of patients with COVID-19: an observational study, *Front Med* 7 (2020), 614152, <https://doi.org/10.3389/fmed.2020.614152>.
- [20] L. Cabrini, L. Ghislanzoni, P. Severgnini, et al., Early versus late tracheal intubation in COVID-19 patients: a pro-con debate also considering heart-lung interactions, *Minerva Cardioangiol* (2020), <https://doi.org/10.23736/S0026-4725.20.05356-6>. In press.
- [21] Y.H. Lee, K.-J. Choi, S.H. Choi, et al., Clinical significance of timing of intubation in critically ill patients with COVID-19: a multi-center retrospective study, *J Clin Med* 9 (9) (2020), 2847, <https://doi.org/10.3390/jcm9092847>.
- [22] C. Sartini, M. Tresoldi, P. Scarpellini, et al., Respiratory parameters in patients with COVID-19 after using noninvasive ventilation in the prone position outside the intensive care unit, *JAMA* 323 (22) (2020) 2338–2340, <https://doi.org/10.1001/jama.2020.7861>.
- [23] M. Schmidt, M. Pineton de Chambrun, G. Lebreton, et al., Extracorporeal membrane oxygenation instead of invasive mechanical ventilation in a patient with severe COVID-19-associated acute respiratory distress syndrome, *Am J Respir Crit Care Med* (April 2021), <https://doi.org/10.1164/rccm.202102-02591e>. In press.
- [24] P. Loyalka, F.H. Cheema, H. Rao, J.E. Rame, K. Rajagopal, Early usage of extracorporeal membrane oxygenation in the absence of invasive mechanical ventilation to treat COVID-19-related hypoxemic respiratory failure, *ASAIO J* 67 (4) (2021) 392–394, <https://doi.org/10.1097/MAT.0000000000001393>.
- [25] J. Tang, W. Li, F. Jiang, T. Wang, Successfully treatment of application awake extracorporeal membrane oxygenation in critical COVID-19 patient: a case report, *J Cardiothorac. Surg.* 15 (1) (2020), 335, <https://doi.org/10.1186/s13019-020-01376-9>.

Alessandro Belletti^a, Giovanni Landoni^{a,b,*}, Alberto Zangrillo^{a,b}

^a Department of Anesthesia and Intensive Care, IRCCS San Raffaele Scientific Institute, Milan, Italy

^b School of Medicine, Vita-Salute San Raffaele University, Milan, Italy

* Corresponding author. Department of Anesthesia and Intensive Care, IRCCS San Raffaele Scientific Institute, Via Olgettina 60, 20132 Milan, Italy.

E-mail address: landoni.giovanni@hsr.it (G. Landoni).