



Since January 2020 Elsevier has created a COVID-19 resource centre with free information in English and Mandarin on the novel coronavirus COVID-19. The COVID-19 resource centre is hosted on Elsevier Connect, the company's public news and information website.

Elsevier hereby grants permission to make all its COVID-19-related research that is available on the COVID-19 resource centre - including this research content - immediately available in PubMed Central and other publicly funded repositories, such as the WHO COVID database with rights for unrestricted research re-use and analyses in any form or by any means with acknowledgement of the original source. These permissions are granted for free by Elsevier for as long as the COVID-19 resource centre remains active.

Bamlanivimab + etesevimab therapy induces SARS-CoV-2 immune escape mutations and secondary clinical deterioration in COVID-19 patients with B-cell malignancies



Bamlanivimab and etesevimab are IgG1 monoclonal antibodies (mAbs) that bind to SARS-CoV-2 spike receptor-binding domain. Treatment with bamlanivimab 2800 mg and etesevimab 2800 mg has been shown to significantly reduce SARS-CoV-2 viral load at day 11 in mild to moderate COVID-19 patients.¹ In the phase III part of the BLAZE-1 trial, the risk of COVID-related hospitalization or death was reduced by 70% in patients treated with this combination versus placebo.²

Subsequently, a temporary use authorization for bamlanivimab 700 mg and etesevimab 1400 mg was approved in France to treat patients presenting with high risk of developing severe COVID-19 infection.

Therefore, we treated 34 cancer patients presenting with a mild to moderate form of SARS-CoV-2 infection and no need for oxygen therapy, within 5 days of their first symptoms, with bamlanivimab 700 mg plus etesevimab 1400 mg. Median age was 62.5 (31-83) years old. Most patients

presented with a solid tumor ($n = 24, 71\%$); 10 (29%) had hematological malignancies and 47.1% were receiving chemotherapy.

COVID-19 outcomes were mostly favorable with supplemental oxygenation required in only 29% of patients versus 41% in our historical cohort (unpublished data). Two patients died of COVID-19 pneumonia but were afterwards found out to be infected by variants with the spike E484K mutation. These favorable issues were correlated with increasing cycle threshold of nasopharyngeal PCR over time (Figure 1).

Strikingly, we noticed that patients with B-cell malignancies ($n = 5, 15\%$) displayed a worse clinical evolution, with delayed COVID-19 symptoms from day 14 to day 30 following the mAbs therapy. All of them needed to be hospitalized again after day 14. We carried out viral spike gene sequencing on pre-and post-bitheraPy nasopharyngeal swabs. Four of these five patients acquired a mutation in the receptor binding domain: three had a Q493R mutation and one had a E484D mutation. Those five patients were rescued with convalescent plasma therapy: four patients recovered and were subsequently discharged, and one died from COVID-19.

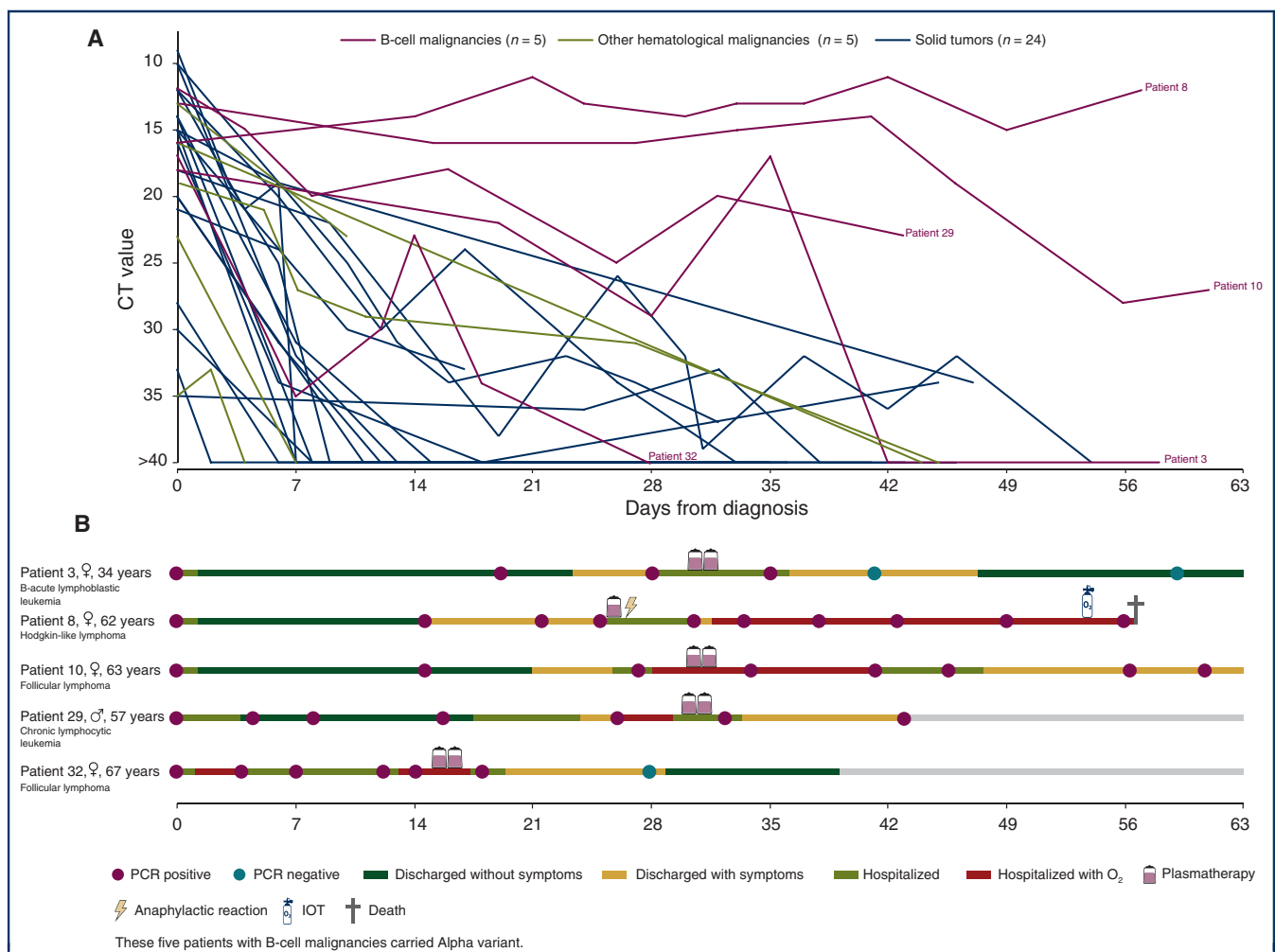


Figure 1. CT and clinical evolution in patients according to cancer type. CT, cycle threshold; IOT, orotracheal intubation.

Patients with hematological malignancies are at high risk of developing severe COVID-19, due to the inherent immune defect caused by the disease and therapy. In a meta-analysis including 3377 hematological malignancy patients, the risk of death among adult patients was 34% (95% CI, 28% to 39%; $n = 3240$).³ Also, CD8+ T cells might play a key role in COVID-19 patients with impaired humoral immunity.⁴

Lohr and colleagues reported the emergence of E484K and Q493R mutations after bamlanivimab monotherapy in an immunocompromised patient with the Alpha variant.⁵

In the Gottlieb study, putative treatment-emergent variants were detected in 1% of the patients (1/102) in the bamlanivimab and etesevimab combination group, and in 4.8% of the patients (7/145) in the placebo group.¹ Our data shows that this risk could be much higher in patients with B-cell malignancies.

Blunting viral replication might be sufficient to avoid severe complications in immunocompetent patients, as the mAbs may initiate host immune response.⁶

Patients with impaired humoral and cellular immune response may have prolonged viral replication and higher viral load.⁷ Thus, pre-existing viral strains with escaping mAb-neutralization mutation could be selected. Higher doses of IgG1 mAbs, polyclonal antibodies or a combination of several mAbs should be interesting in such B-depleted patients.

Finally, while bamlanivimab 700 mg associated with etesevimab 1400 mg is effective in patients with solid tumors, patients with B-cell malignancies present a secondary clinical deterioration associated with immune escape mutations. Our observation highlights the importance of clinical trials in this specific population, including comprehensive clinical and virological follow-up.

F. Pommeret^{1*}, J. Colomba¹, C. Bigenwald², A. Laparra³, S. Bockel⁴, A. Bayle³, J.-M. Michot³, T. Hueso², L. Albiges¹, P. Tiberghien^{5,6}, S. Marot⁷, A. Jary⁷, K. Lacombe⁸, F. Barlesi^{1,9}, F. Griscelli¹⁰ & E. Colomba¹

Departments of ¹Medical Oncology;

²Hematology;

³Therapeutic Innovation and Early Trials;

⁴Radiotherapy, Gustave Roussy, Villejuif;

⁵Etablissement Français du Sang,

La Plaine St-Denis, Saint-Denis;

⁶UMR RIGHT 1098 Inserm, Etablissement Français du Sang,

Université de Franche-Comté, Besançon;

⁷Virologie, Pitié-Salpêtrière, AP-HP,

Sorbonne Université, Paris;

⁸Inserm IPLESP, Sorbonne Université,

Hôpital St Antoine, AP-HP, Paris;

⁹Aix-Marseille University, CRCM,

INSERM, CNRS, Marseille;

¹⁰Virology, Gustave Roussy

Villejuif, France

(*E-mail: Fanny.POMMERET@gustaveroussy.fr).

Available online 2 August 2021

© 2021 European Society for Medical Oncology. Published by Elsevier Ltd. All rights reserved.

<https://doi.org/10.1016/j.annonc.2021.07.015>

FUNDING

None declared.

DISCLOSURE

AB is a Principal/sub-Investigator of Clinical Trials for Abbvie, Adaptimmune, Adlai Nortye USA Inc, Aduro Biotech, Agios Pharmaceuticals, Amgen, Argen-X Bvba, Astex Pharmaceuticals, Astra Zeneca Ab, Aveo, Basilea Pharmaceutica International Ltd, Bayer Healthcare Ag, Bbb Technologies Bv, Beigene, BicycleTx Ltd, Blueprint Medicines, Boehringer Ingelheim, Boston Pharmaceuticals, Bristol Myers Squibb, Ca, Celgene Corporation, Chugai Pharmaceutical Co, Clovis Oncology, Cullinan-Apollo, Curevac, Daiichi Sankyo, Debiopharm, Eisai, Eisai Limited, Eli Lilly, Exelixis, Faron Pharmaceuticals Ltd, Forma Therapeutics, Gamamabs, Genentech, Glaxosmithkline, H3 Biomedicine, Hoffmann La Roche Ag, Imcheck Therapeutics, Innate Pharma, Institut De Recherche Pierre Fabre, Iris Servier, Iteos Belgium SA, Janssen Cilag, Janssen Research Foundation, Kura Oncology, Kyowa Kirin Pharm. Dev, Lilly France, Loxo Oncology, Lytix Biopharma As, Medimmune, Menarini Ricerche, Merck Sharp & Dohme Chibret, Merrimack Pharmaceuticals, Merus, Millennium Pharmaceuticals, Molecular Partners Ag, Nanobiotix, Nektar Therapeutics, Novartis Pharma, Octimet Oncology Nv, Oncoethix, Oncopeptides, Orion Pharma, Ose Pharma, Pfizer, Pharma Mar, Pierre Fabre, Medicament, Roche, Sanofi Aventis, Seattle Genetics, Sotio A.S, Syros Pharmaceuticals, Taiho Pharma, Tesaro, Turning Point Therapeutics, Xencor, received Research Grants from Astrazeneca, BMS, Boehringer Ingelheim, GSK, INCA, Janssen Cilag, Merck, Novartis, Pfizer, Roche, Sanofi, and Non-financial support (drug supplied) from Astrazeneca, Bayer, BMS, Boringher Ingelheim, GSK, Medimmune, Merck, NH TherAGuiX, Pfizer, Roche. JMM LA Pfizer, Novartis, Merck, Astra Zeneca, MSD, Roche, Ipsen, Bristol Myer Squibb, Astellas, Exeliquis, Amgen, Peloton therapeutics, Corvus Pharmaceuticals, all outside the submitted work. JMM is a principal/sub-investigator of clinical trials for Abbvie, Agios, Amgen, Astex, AstraZeneca, BMS, Boeringer Ingelheim, Celgene, Debiopharm, Forma, Genentech, GSK, Incyte, Innate Pharma, Janssen, Lilly, Loxo, Medimmune, MSD, Novartis, Pfizer, Pharmamar, Roche, Sanofi and Xencor; and reports non-financial support (drugs, equipment supplied by the entity, travel paid by the entity, writing assistance, administrative support, etc.) from AstraZeneca, Roche, Novartis, Gilead, Celgene and Bristol-Myers Squibb, all outside the submitted work. LA received grants and honoraria from Pfizer, Novartis, BMS, Ipsen, Roche, AstraZeneca, Amgen, Astellas, Exelixis, Corvus Pharmaceuticals, Peloton

therapeutics, MSD, and Merck, outside the submitted work. KL received Advisory boards, travels grants, educational activities from Gilead, MSD, Abbvie, ViiV Healthcare, all outside the submitted work. PT is employed by Etablissement Français du Sang, the French transfusion public service in charge of collecting and issuing blood components in France. FB has personal financial interests in AstraZeneca, Bayer, BMS, Boehringer Ingelheim, Eli Lilly Oncology, F Hoffmann-La Roche, Novartis, Merck, MSD, Pierre Fabre, Pfizer, and Takeda; and institutional financial interests in AbbVie, ACEA, Amgen, AstraZeneca, Bayer, BMS, Boehringer Ingelheim, Eisai, Eli Lilly Oncology, F. Hoffmann-La Roche, Genentech, Ipsen, Ignyta, Innate Pharma, Loxo, Novartis, Medimmune, Merck, MSD, Pierre Fabre, Pfizer, Sanofi-Aventis, and Takeda. FB is an advisory board member for Amgen, Bayer, BMS, CheckMab, Celgene, Daiichi Sankyo, Incyte, Merck, Novartis, F. Hoffmann-La Roche, and Seattle Genetics, all outside the submitted work. EC has acted as a consultant and participated in advisory boards for Ipsen, BMS, Sanofi, and Tesaro and Clovis, all outside the submitted work. All other authors have declared no conflicts of interest.

REFERENCES

- Gottlieb RL, Nirula A, Chen P, et al. Effect of bamlanivimab as monotherapy or in combination with etesevimab on viral load in patients with mild to moderate COVID-19: a randomized clinical trial. *JAMA*. 2021;325(7):632-644.
- Dougan, M. Bamlanivimab+etesevimab for treatment of COVID-19 in high-risk ambulatory patients. Paper presented at the 28th Conference on Retroviruses and Opportunistic Infections. March 9, 2021; Virtual.
- Vijenthira A, Gong IY, Fox TA, et al. Outcomes of patients with hematologic malignancies and COVID-19: a systematic review and meta-analysis of 3377 patients. *Blood*. 2020;136(25):2881-2892.
- Bange EM, Han NA, Wileyto P, et al. CD8+ T cells contribute to survival in patients with COVID-19 and hematologic cancer. *Nat Med*. 2021;27(7):1280-1289.
- Lohr B, Niemann D, Verheyen J. Bamlanivimab treatment leads to rapid selection of immune escape variant carrying E484K mutation in a B.1.1.7 infected and immunosuppressed patient. *Clin Infect Dis*. 2021. <https://doi.org/10.1093/cid/ciab392>
- Corti D, Purcell LA, Snell G, Vesler D. Tackling COVID-19 with neutralizing monoclonal antibodies. *Cell*. 2021;184(12):3086-3108.
- Michot JM, Hueso T, Ibrahim N, et al. Severe COVID-19 in patients with hematological cancers presenting with viremia. *Ann Oncol*. 2021. <https://doi.org/10.1016/j.annonc.2021.07.002>

Significant response of medullary thyroid cancer choroidal metastases to highly selective *RET* inhibitor selpercatinib: a case report



A 53-year-old man was affected by a sporadic metastatic medullary thyroid cancer (MTC), widespread to cervical and mediastinal lymph nodes, lungs, liver, and cerebellum. Over the 10 years from the initial diagnosis, the patient was treated with two tyrosine kinase inhibitors (TKIs) (i.e. vandetanib and lenvatinib off-label). After 1 year from surgery

(total thyroidectomy with lymph node dissection of central and left latero-cervical compartment), the patient experienced progression of disease according to RECIST 1.1¹; therefore, treatment with vandetanib (300 mg/daily, orally) was started in 2012. The patient showed a partial response of the disease, with manageable adverse events, primarily grade 1 and 2 according to Common Terminology Criteria for Adverse Events (CTCAE v. 4.0),² and no reduction of dose over time. After 5 years of treatment, progression according to RECIST criteria was shown and treatment with lenvatinib off-label at an initial dose of 24 mg/daily orally was started. Disease remained stable for about 2 years until cerebellar metastases appeared.

Whole brain radiotherapy was carried out with stabilization of the cerebellar metastases and absence of neurological symptoms. However, after 3 years from the beginning of lenvatinib, progression of the disease in lymph nodes and liver metastases was observed, associated with worsening of symptoms (grade 3 fatigue, grade 2 diarrhea, and grade 3 weight loss, according to CTCAE). Moreover, he experienced sudden and complete loss of vision in his left eye. Optical coherence tomography (OCT) and fluorescein angiography showed bilateral choroidal metastases with exudate in the left macular field, responsible for the visual loss (Figure 1A₁ and B₁).

MTC is a neuroendocrine tumor arising from thyroid C cells. About 10% of cases have distant metastases at diagnosis, and about 15% develop distant metastatic disease during follow-up. The metastatic sites are predominately in the liver, lung, bone, and brain, but they can infrequently occur in other sites such as adrenal glands, ovary, pancreas, eyes, and breast. The presence of distant metastases severely worsens MTC prognosis, which drops to a 5-year survival rate of 25% from diagnosis.³

To our knowledge, choroidal metastases are extremely rare and have been described in the literature in only nine MTC patients^{4,5} (five sporadic and four hereditary cases). The choroid is the vascular membrane of the eye and is the most frequent site of metastases among the ocular structures. The presence of fenestrated endothelium in the highly vascularized choriocapillaris leads to high permeability and may allow both the process of metastasization and the rapid entry of drugs from the blood. At variance with the retina, the metastatic cells do not have to cross the blood–retinal barrier, part of the blood–brain barrier, to reach the choroid. For this reason, the agent does not need to be a central nervous system (CNS) penetrant drug to be effective on the choroidal metastases.

Choroidal metastases have a severe impact on quality of life since they can progress to vision loss. To date, no effective therapies have been reported, and their presence has been associated with a rapid poor prognosis, with <9 months' survival in described cases.⁴

In cases of progressive metastatic MTC, systemic treatments with TKIs are largely employed.^{6,7} However, several clinical experiences demonstrated that a mechanism of resistance to the drug develops, and patients on TKI treatment have disease progression.