



Since January 2020 Elsevier has created a COVID-19 resource centre with free information in English and Mandarin on the novel coronavirus COVID-19. The COVID-19 resource centre is hosted on Elsevier Connect, the company's public news and information website.

Elsevier hereby grants permission to make all its COVID-19-related research that is available on the COVID-19 resource centre - including this research content - immediately available in PubMed Central and other publicly funded repositories, such as the WHO COVID database with rights for unrestricted research re-use and analyses in any form or by any means with acknowledgement of the original source. These permissions are granted for free by Elsevier for as long as the COVID-19 resource centre remains active.



Review Article

Vaccine-induced immune thrombotic thrombocytopenia and cerebral venous sinus thrombosis post COVID-19 vaccination; a systematic review

Maryam Sharifian-Dorche^{a,b}, Mohammad Bahmanyar^c, Amirhossein Sharifian-Dorche^b, Pegah Mohammadi^d, Masood Nomovi^e, Ashkan Mowla^{f,*}

^a Department of Neurology and Neurosurgery, Montreal Neurological Institute, McGill University, Montreal, Quebec, Canada

^b Clinical Neurology Research Center, Shiraz University of Medical Sciences, Shiraz, Iran

^c Department of Pathology and Laboratory Medicine, St Paul's Hospital, University of British Columbia (UBC), Vancouver, British Columbia, Canada

^d Department of Medicine, Eisenhower Medical Center, Rancho Mirage, CA, USA

^e Department of Internal Medicine, Shiraz University of Medical Sciences, Shiraz, Iran

^f Department of Neurological Surgery, Keck School of Medicine, University of Southern California (USC), Los Angeles, CA, USA



ARTICLE INFO

Keywords:

ChAdOx1 nCoV-19 vaccine
Ad26.COV2 vaccine
Vaccine-induced immune thrombotic thrombocytopenia
Cerebral venous sinus thrombosis

ABSTRACT

Introduction: The common reported adverse effects of COVID-19 vaccination consist of the injection site's local reaction followed by several non-specific flu-like symptoms. However, rare cases of vaccine-induced immune thrombotic thrombocytopenia (VITT) and cerebral venous sinus thrombosis (CVST) after viral vector vaccines (ChAdOx1 nCoV-19 vaccine, Ad26.COV2 vaccine) have been reported. Herein we systemically reviewed the reported cases of CVST and VITT following the COVID-19 vaccination.

Methods: This systematic review was performed according to the Preferred Reporting Items for Systematic Reviews and Meta-Analyses (PRISMA) statement. We searched PubMed until May 19, 2021, and the following Keywords were used: COVID Vaccine & Neurology, AstraZeneca COVID vaccine, ChAdOx1 nCoV-19 COVID vaccine, AZD1222 COVID vaccine, Janssen COVID vaccine, Johnson & Johnson COVID vaccine, Ad26.COV2 COVID vaccine. The authors evaluated the abstracts and titles of each article for screening and inclusion. English reports about post-vaccine CVST and VITT in humans were collected.

Results: Until May 19, we found 877 articles with the searched terms. We found 12 articles, which overall present clinical features of 36 patients with CVST and VITT after the ChAdOx1 nCoV-19 vaccine. Moreover, two articles were noted, which present 13 patients with CVST and VITT after Ad26.COV2 vaccine. The majority of the patients were females. Symptom onset occurred within one week after the first dose of vaccination (Range 4–19 days). Headache was the most common presenting symptom. Intracerebral hemorrhage (ICH) and/or Subarachnoid hemorrhage (SAH) were reported in 49% of the patients. The platelet count of the patients was between 5 and 127 cells $\times 10^9/L$, PF4 IgG Assay and d-Dimer were positive in the majority of the reported cases. Among 49 patients with CVST, at least 19 patients died (39%) due to complications of CVST and VITT.

Conclusion: Health care providers should be familiar with the clinical presentations, pathophysiology, diagnostic criteria, and management consideration of this rare but severe and potentially fatal complication of the COVID-19 vaccination. Early diagnosis and quick initiation of the treatment may help to provide patients with a more favorable neurological outcome.

1. Introduction

The COVID-19 (coronavirus disease) pandemic had a devastating impact on public health, social life, and economy worldwide [1–4]. The development of vaccines has been shown to be the only effective tool to

combat the situation. Vaccines prevent severe illness from SARS-COV-2 infection [5,6]. Thus far, two types of COVID-19 vaccines are developed. Messenger RNA (mRNA) vaccines such as Pfizer/BioNTech's (BNT162b2) and Moderna's (mRNA-1273) and viral vector vaccine such as Oxford-AstraZeneca vaccine (AZD1222 (ChAdOx1)) and Johnson &

* Corresponding author at: Division of Endovascular Neurosurgery, Department of Neurological Surgery, Keck School of Medicine, University of Southern California (USC), 1200 North State St., Suite 3300, Los Angeles, CA 90033, USA.

E-mail address: mowla@usc.edu (A. Mowla).

<https://doi.org/10.1016/j.jns.2021.117607>

Received 20 May 2021; Received in revised form 5 July 2021; Accepted 1 August 2021

Available online 3 August 2021

0022-510X/© 2021 Elsevier B.V. All rights reserved.

Johnson COVID-19 vaccine (JNJ-78436735 (Ad26.COV2-S)) [7].

Safety concerns have been raised regarding the vaccines since they have been used. The common adverse effects post COVID-19 vaccination consist of the injection site’s local reaction followed by non-specific systemic symptoms such as headache, fatigue, myalgia, and fever. These symptoms may occur soon after vaccination and resolve in a short period [6]. However, some rare cases of vaccine-induced immune thrombotic thrombocytopenia (VITT) have been reported, mainly with viral vector vaccines [6]. Among these reports, there are patients with VITT and cerebral venous sinus thrombosis (CVST), a severe and rare neurological condition [8,9].

In this study, we systematically reviewed the CVST cases reported post-COVID-19 vaccination so far. We described their clinical and laboratory features and also discussed the diagnostic and management implications.

2. Methods

This systematic review was performed according to the Preferred Reporting Items for Systematic Reviews and Meta-Analyses (PRISMA) (Fig. 1) statement [10]. We searched PubMed until May 19, 2021, and the following keywords were used: COVID Vaccine & Neurology, AstraZeneca COVID vaccine, ChAdOx1 nCoV-19 COVID vaccine, AZD1222 COVID vaccine, Janssen COVID vaccine, Johnson & Johnson COVID vaccine, Ad26.COV2 COVID vaccine. The authors evaluated the abstracts and titles of each article for screening and inclusion. English reports on post-vaccine CVST and VITT in humans (original articles, case

series, case reports, letters, correspondence, or short communications presenting at least 1 case of CVST after the COVID-19 vaccine) were collected. Included articles were reviewed in full text. Relevant references in each article were also checked. Duplicated results were removed. Data from each article was extracted into the Microsoft Excel software.

3. Results and discussion

Until May 19, 2021, we found 877 articles with the searched words. COVID Vaccine & Neurology(175 articles), AstraZeneca COVID vaccine (226 articles), ChAdOx1 nCoV-19 COVID vaccine(86 articles), AZD1222 COVID vaccine(69 articles), Janssen COVID vaccine(160 articles), Johnson & Johnson COVID vaccine(140articles), Ad26.COV2 COVID vaccine(21 articles). Among these articles, we selected the relevant reports.

3.1. AstraZeneca COVID-19 vaccine(ChAdOx1)

The Oxford–AstraZeneca COVID-19 vaccine (AZD1222, ChAdOx1, and Vaxzevria) is a viral vector vaccine to prevent COVID-19. Overall this vaccine efficacy more than 14 days after the second dose was about 66.7% [11].

Common side effects including injection-site reaction and pain, headache, malaise, and nausea, all generally resolving within a few days [6]. However, there are few reports of VITT after vaccination [9].

According to the “European Medicine Agency’s Pharmacovigilance

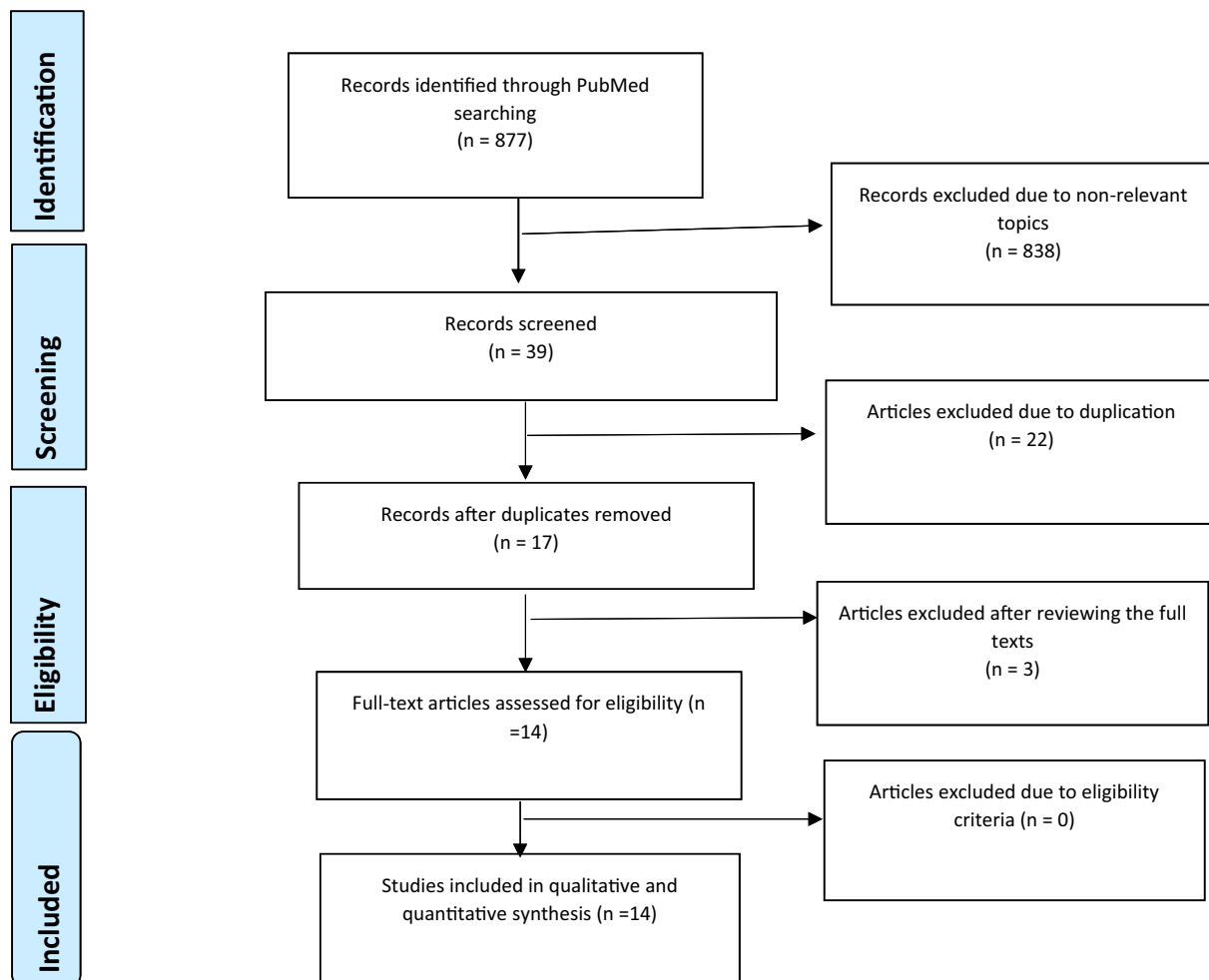


Fig. 1. PRISMA chart of this study.

Risk Assessment Committee,” from the 34 million people that received the AstraZeneca COVID-19 vaccine in the European Economic Area and the United Kingdom as of April 4, 2021, 169 cases of CVST and 53 cases of splanchnic vein thrombosis were reported. Most of these cases occurring within the first two weeks of vaccination and in women <60 years [6].

Table 1 summarizes the articles that report CVST, associated venous infarct and hemorrhagic stroke, arterial infarct and ICH (intracerebral hemorrhage), and VITT after the AstraZeneca COVID-19 vaccine. In this group, we found 12 articles, which present the clinical features of 41 (36 CVST, 4 infarctions, 1 ICH) patients. Among 36 patients with CVST, 16 patients had an ICH and/or Subarachnoid Hemorrhage (SAH) (44%). From all reported cases (41 patients), 18 patients (44%) died.

3.2. Johnson & Johnson COVID-19 vaccine (Ad26.COV2)

Johnson & Johnson COVID-19 vaccine is a viral vector vaccine based on a human adenovirus. It has been modified to contain the gene for making the spike protein of the SARS-CoV-2 that causes COVID-19 [24].

The vaccine's efficacy is about 66.1% against symptomatic moderate and severe SARS-CoV-2 infection and about 85.4% against hospitalization or death [25].

Common side effects after vaccination include injection site reactions, fever, chills, and malaise, but there are rare reports of venous thrombosis after vaccination [26].

Table 2 summarizes the articles which report CVST and associated venous infarct and hemorrhagic stroke and VITT after Johnson & Johnson COVID-19 vaccine. In this group, we found 2 articles that present 13 patients. All of these patients were females. Among 13 reported patients with CVST, 8 patients had ICH/SAH (61%).

3.3. CVST

In general, CVST affects young adults, especially young women. In most cases, the patients have an identifiable risk factor for thrombosis, such as pregnancy, puerperium, autoimmune diseases, oral contraceptives, etc. [28–31]. Diagnosis might be challenging at times. The symptoms of CVST may mimic other neurological disorders and might reflect the location of the involved vein or sinus [30]. However, headache is a frequent symptom and present in the majority of the patients [28]. With the progression of the disease, patients may develop focal neurological deficits due to venous infarction and seizure, which is more common in CVST compared to the other subtypes of stroke. With timely diagnosis and treatment, full recovery might happen [32].

Infection with SARS-Cov-2 has also been shown to contribute to the development of CVST in multiple studies [8,32].

3.4. History and clinical characteristics of reported cases of CVST associated with VITT

Thrombotic thrombocytopenia after vaccination is not a new event in the history of vaccination [33]. One of the first reports was from Brown et al. in 1973, who reported thrombotic thrombocytopenia after influenza vaccination [34]. There are also other reports of similar events after H1N1, Rabies, and pneumococcal vaccination [35–38]. In these reports, corticosteroids, plasmapheresis, and rituximab were suggested as treatment options. However, CVST was not reported in these patients [34,37].

SARS-CoV-2 VITT is a newly described phenomenon post-viral vector COVID-19 vaccines. In contrast to the previous reports of thrombotic thrombocytopenia after vaccination, in these patients, cases of CVST have been reported post-COVID-19 vaccines.

In this study, all reported cases of VITT and CVST are announced after AstraZeneca (ChAdOx1) and Johnson & Johnson (Ad26.COV2) vaccination. The majority of reported patients with CVST associated with VITT were females, 54 cases reported in total (49 cases of CVST, 4

cases of infarction, and 1 case of ICH), 36 females, 9 males, and 9 unknown sex. Oral contraceptives (2 cases), Contraceptive vaginal ring (1 case), Hormone-replacement therapy (1 case), and Obesity (6 patients) were the most relevant predisposing conditions in the patients.

Symptom onset occurred within one week after the first dose of vaccination (Range: 4–19 days). Headache was the most frequent presenting symptom in the patients with CVST. In addition, other symptoms such as malaise, vomiting, lethargy, loss of consciousness, blurred vision, hemiparesis, abdominal pain, and back pain were reported in some patients. Abdominal pain and back pain were reported in the patient with concurrent portal vein thrombosis.

Subarachnoid hemorrhage (SAH) and intracerebral hemorrhage (ICH) were seen as consequences of CVST in a large group of patients (24 patients, 49% of the patients with CVST). Middle cerebral artery (MCA) infarct was reported in 4 patients after the ChAdOx1 nCoV-19 vaccine (AstraZeneca) (Tables 1 and 2).

Pulmonary embolism, splanchnic vein thrombosis, lower extremity deep venous thrombosis, bilateral adrenal hemorrhage, portal vein thrombosis, iliofemoral vein thrombosis, internal jugular vein thrombosis, and Ischemic bowel infarct are other sites of thrombosis in the reported patients (Tables 1 and 2).

Platelet count was between 5 and 127 cells $\times 10^9/l$, and PF4 IgG Assay and d-Dimer were positive in most reported cases. Among 54 patients evaluated in this study, at least 21 (38.8%) patients died (19 cases of CVST (39%), one case of infarction (25%), and one case of ICH) (Tables 1 and 2). Such a high mortality rate among CVST patients indicates the importance of early diagnosis and treatment of CVST and VITT post-COVID-19 vaccination [12].

3.5. Pathophysiology

VITT clinically resembles spontaneous autoimmune heparin-induced thrombocytopenia (HIT). HIT is caused by platelet-activating immunoglobulin G (IgG) antibodies against platelet factor 4 (PF4) complexed with heparin. This complex then binds to the platelet Fc γ IIA receptors and causes platelet activation and formation of platelet microparticles [39]. These microparticles initiate the formation of blood clots and inducing a prothrombotic cascade, which consequently decreases platelet count and causes thrombocytopenia. Moreover, the reticuloendothelial system, particularly the spleen, removes the antibody-coated platelets and aggravates thrombocytopenia [6,20,39,40].

It has also been demonstrated that some patients present with clinical symptoms and laboratory features of HIT despite not having previously received heparin and recognized as spontaneous autoimmune HIT. Sera from these patients contain antibodies that activate platelets strongly even in the absence of heparin. Most reported spontaneous HIT patients had preceding orthopedic surgery (release of knee cartilage glycosaminoglycans or RNA, owing to tourniquet-related cell damage) or infection (exposure to microorganism) [41].

AstraZeneca COVID vaccine (ChAdOx1) and Johnson & Johnson (Ad26.COV2) vaccines contain replication-incompetent adenoviral vectors; chimpanzee ChAdOx1 and human Ad26.COV2-S respectively. These two factors encode the spike glycoprotein on SARS-CoV-2 [32].

Interactions between the vaccine and platelets or PF4 could play a role in the pathogenesis of VITT. The possible explanation for this phenomenon is that the free DNA in the vaccines could bind to PF4 and trigger these PF4-reactive autoantibodies in the VITT setting [19] (Fig. 2).

An important observation in VITT post-COVID-19 vaccination is the preponderance of thrombosis in the cerebral venous sinuses. Although HIT is a prothrombotic condition, it has not been reported to preferentially present in association with CVST. Moreover, brain imaging of the patients with post-COVID-19 vaccination associated with VITT and CVST detected a high rate (49% in this study) of ICH and SAH [20].

Table 1

Clinical and laboratory findings of the patients with thromboembolic events after vaccination with The Oxford–AstraZeneca COVID-19 vaccine. F: Female, M: Male, N/A: not applicable, CVST: cerebral venous sinus thrombosis, MCA: Middle cerebral artery, ICH: Intracerebral Hemorrhage, SAH: Subarachnoid hemorrhage, PF4: Platelet Factor 4.

No	Authors	Total no./sex/age	Preexisting conditions / medications	Time from vaccination (days)	Clinical presentations	Imaging findings	Lab findings	Outcome
1	Scully et al. [12]	11 F Mean age: 39.3 (Range:26–55) 5 M Mean age: 32 (Range:21–48)	N/A	11.7 (Range:6–19) days	N/A	13 CVST (In 2 cases with ICH and 1 with SAH) 2 MCA infarct 1 ICH(with PVT and AAT) Additional findings in addition to CVST: ICH SAH PVT(portal vein thrombosis), PE(pulmonary embolism), Ischemic bowel infarct, AAT(acute aortic thrombosis), IJVT(internal jugular vein thrombosis), Thrombosis in the lung	<i>Platelet count:</i> Mean: 48 (Range:7–113) cells×10 ⁹ /l <i>PF4 IgG Assay:</i> Done in 10 cases, 9 Positive and 1 Negative <i>d-Dimer:</i> Positive in 13 cases and 3 cases not done.	Alive:11 patients Died: 5 Patients (4 CVST, 1 ICH)
2	Schultz et al. [13]	4 F Mean age: 43 Range:37–54)	Hypertension oral contraceptive pill (OCP), Contraceptive vaginal ring, Hormone-replacement Therapy, Antihypertensive agents	8.7 (Range:7–10) days	Headache (in all cases), visual disturbances, drowsiness, abdominal pain, Hemiparesis	CVST in: Cortical veins, transverse sinus, sigmoid sinus, inferior sagittal sinus, vein of Galen and straight sinus all with ICH	<i>Platelet count:</i> Mean: 31.2 (Range:19–70) cells×10 ⁹ /l <i>PF4 IgG Assay:</i> Positive in all cases <i>d-Dimer:</i> Positive in all cases	Alive:3 patients Died: 1 Patient
3	Bayas et al. [14]	55 y/o F	–	10 days	conjunctival congestion, retro-orbital pain, and diplopia	Bilateral superior ophthalmic vein thrombosis Ischemic stroke in the left parietal lobe, MCA territory Right MCA infarct	<i>Platelet count:</i> 30 cells×10 ⁹ /l <i>PF4 IgG Assay:</i> Negative	Alive
4	Blauenfeldt et al. [15]	60 y/o F	Hashimoto's thyroiditis and Hypertension	9 days	left-sided weakness, eye deviation to the right		<i>Platelet count:</i> drops to 5 cells×10 ⁹ /l <i>PF4 IgG Assay:</i> Positive <i>d-Dimer:</i> Positive	Died
5	Castelli et al. [16]	50 y/o M	–	11 days	Headache Deviation of the right buccal rim loss of strength in the right lower limb Slight visual impairment.	CVST In left transverse and sigmoid sinuses And ICH	<i>Platelet count:</i> 20 cells×10 ⁹ /l <i>d-Dimer:</i> Positive	Died
6	D'Agostino et al. [17]	54 y/o F	Meniere's disease	12 days	left side weakness	CVST multiple subacute intra-axial hemorrhages in atypical locations SAH acute basilar thrombosis superior sagittal sinus thrombosis non-occlusive thrombosis of the vein of Galen myocardial infarction thrombus within the aortic arch and left portal branch and right	Thrombocytopenia <i>d-Dimer:</i> Positive	Died

(continued on next page)

Table 1 (continued)

No	Authors	Total no./sex/age	Preexisting conditions / medications	Time from vaccination (days)	Clinical presentations	Imaging findings	Lab findings	Outcome
7	Franchini et al. [18]	50 y/o M	-	7 days	Headache	suprahepatic vein and Bilaterally, adrenal hemorrhage CVST in left transverse and sigmoid sinuses intra-parenchymal hemorrhage in the left cerebral hemisphere	Platelet count: 15 cells×10 ⁹ /l PF4 IgG Assay: Positive d-Dimer: Positive	Died
8	Greinacher et al. [19]	9 Patients	1 case with chronic neurological disorder 1 case with type 1 von Willebrand disease and positive anticardiolipin antibodies	9.3 (Range:5–16) days	-	9 CVST Pulmonary embolism splanchnic -vein thrombosis Aortoiliac thrombosis intra- ventricular, iliofemoral vein, Multiple organ thromboses	Platelet count: 27.3 cells×10 ⁹ /l (Range 8–75) PF4 IgG Assay: 7 Positive 2 unknown d-Dimer: Positive in all cases	5 Died 1 Unknown 3 Alive
9	Mehta et al. [20]	2 M Mean Age: 28.5 y/o (Range: 25–32)	Primary sclerosing cholangitis	7.5 days (6–9)	Headache	CVST in Superior sagittal sinus, cortical veins, and Superior sagittal sinus With ICH and SAH	Platelet count: 24.5 cells×10 ⁹ /l (Range 19–30) PF4 IgG Assay: 1 Positive 1 unknown d-Dimer: 1 Positive 1 unknown	2 Died
10	Wolf et al. [21]	3F 34.6 y/o(Range: 22–46)		6.3 days (4–8)	Headache in all cases , epileptic seizure , aphasia and hemianopia	CVST In ascending cerebral veins, superior sagittal sinus, transverse sinus, and also sigmoid sinus with ICH and SAH	Platelet count: 75.5 cells×10 ⁹ /l (Range 60–92) PF4 IgG Assay: Positive d-Dimer: Positive	All Alive
11	Bjørnstad-Tuveng TH et al. [22]	30s y/o F	Mild preeclampsia in a previous pregnancy	7 days	Headache	CVST in Transverse sinus, frontal lobe, and pulmonary artery. With ICH And SAH	Platelet count: 37 cells×10 ⁹ /l PF4 IgG Assay: Positive d-Dimer: Positive	Died
12	Tobaiqy et al. [23]	Age between:18–64 1F	N/A	N/A	N/A	CVST, With ICH And pulmonary embolism peripheral artery thrombosis	N/A	Not Resolved (Unknown)
Total		41 In 32 patients, sex was reported (23 F, 9 M)		7 days Range (4–19)	Headaches most frequent	CVST:36 MCA infarct: 4 ICH:1 (CVST+ICH/SAH: 16)	Platelet count: 39 cells×10 ⁹ /l (5–113) PF4 IgG Assay: Positive: 27 Negative: 2 Unknown:11 d-Dimer: Positive: 35 Unknown:5	Alive:21 Died:18(16 CVST, 1 ICH, 1 Infarct) Unknown:2

3.6. Diagnosis

Despite the high mortality associated with VITT and CVST post-COVID-19 vaccination, prompt recognition and early management will likely lead to better neurological outcomes. Key diagnostic criteria of VITT include the following items (must meet all four criteria):

1- The patient has received the AstraZeneca COVID (ChAdOx1) or Johnson & Johnson (Ad26.CO2) vaccines within the last 30 days (between 4 and 30 days).

- 2- Presence of moderate to severe thrombocytopenia. However, in some cases, this thrombocytopenia may be mild, particularly in the beginning stages of VITT.
- 3- The presence of thrombosis often in the forms of CVST (Patients may present with headache) or splanchnic veins thrombosis(patients may present with abdominal or back pain (or both) and nausea and vomiting). Arterial thrombosis occurs less commonly.
- 4- Positive PF4 “HIT” (heparin-induced thrombocytopenia) ELISA [42].

Despite transient headaches being a common adverse effect of vaccination, if a patient has a continuing headache, blurred vision, petechiae, easy bruising, or bleeding after AstraZeneca COVID

Table 2

Reports of CVST post-Johnson & Johnson COVID-19 vaccination. F: Female, M: Male, N/A: not applicable, CVST: cerebral venous sinus thrombosis, ICH: Intracerebral Hemorrhage, PF4: Platelet Factor4.

No	Authors	Total no. sex/age	Preexisting conditions / Medications	Time from vaccination (days)	Clinical presentations	Imaging findings	Lab findings	Outcome
1	See et al. [9]	12 F 8 (18–39) 4(>40)	Obesity in 6 patients combined oral contraceptives (OCP) in 1 patient	8.8 days (Range: 6–13)	Headache 11 patients Other symptoms: Back pain, Abdominal pain, lethargy, myalgia, nausea, vomiting, fever, dyspnea, chills, photophobia, cognitive impairment, blurred vision, Right side weakness	12 CVST in: Transverse sinus, sigmoid sinus, straight sinus, superior sagittal sinus, internal jugular vein with 7 patients ICH and 8 patients with non-CVST including thromboses including: portal vein thrombosis lower extremity deep vein thrombosis	Platelet count: Mean: 45.7 (Range:9–127) cells×10 ⁹ /l PF4 IgG Assay: Done in 11 cases, all Positive d-Dimer: Positive in all patients	4 patients were discharged to home. 3 patients died. Other: intensive care unit (ICU) care: 3 non-ICU hospitalization: 2
2	Muir KL et al. [27]	48 y/o F		14 days	Malaise and abdominal pain and then Headache	CVST in the right transverse And straight sinuses. And ICH And splanchnic -vein thrombosis	Platelet count: Mean: 13 cells×10 ⁹ /l PF4 IgG Assay: Positive d-Dimer: Positive	Critically ill
Total		13 F	6 Patients with Obesity One on OCP	9.2(Range: 6–14)	Headache most frequent presenting complain	13 CVST (CVST + ICH/SAH: 8)	Platelet count: Mean: 43 cells×10 ⁹ /l (Range:9–127) PF4 IgG Assay: Positive in 12 cases Unknown in 2 cases d-Dimer: Positive in all cases	Discharged: 4 Died: 3 Critically ill: 4 non-ICU hospitalization: 2

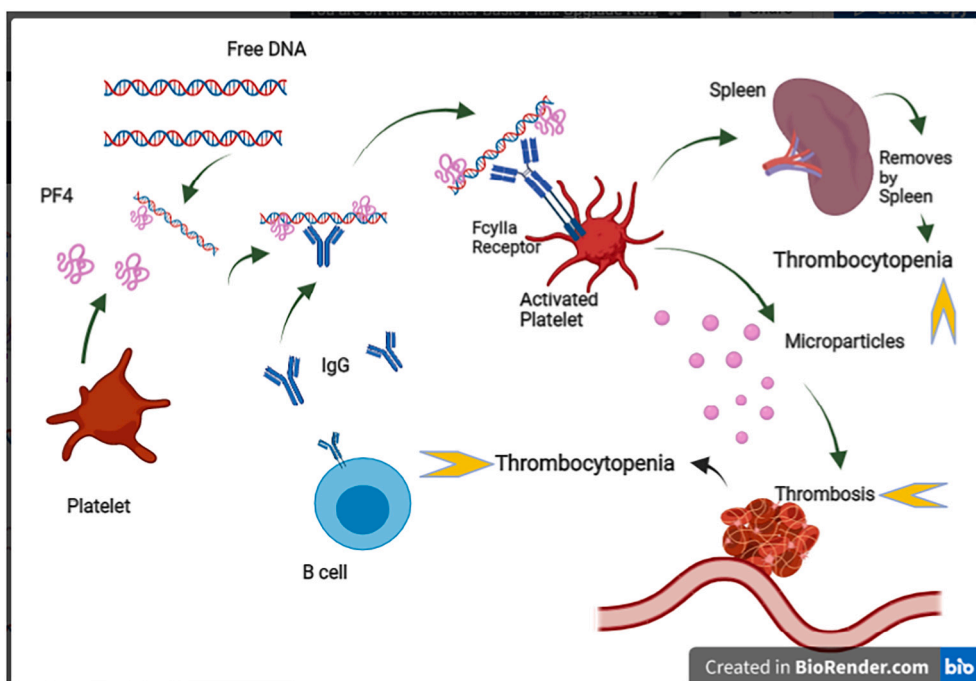


Fig. 2. Possible mechanism of VITT after Viral Vector Vaccines. The free DNA in the vaccine could bind to PF4 and trigger platelet-activating immunoglobulin G (IgG) antibodies. This complex then binds to the platelet FcγIIa receptors and causes platelet activation and formation of platelet microparticles. These microparticles initiate the formation of blood clots and inducing a prothrombotic cascade, which consequently decreases platelet count and causes thrombocytopenia. Moreover, the reticuloendothelial system, particularly the spleen, removes the antibody-coated platelets and aggravates thrombocytopenia. PF4: Platelet Factor 4, IgG: immunoglobulin G. Created in BioRender.com by MN.

(ChAdOx1) or Johnson & Johnson (Ad26.CO2), CVST after VITT should be considered [42].

3.7. Recommended evaluations and laboratory workups

In patients with suspected CVST, computed tomography venogram (CTV) or magnetic resonance imaging venogram(MRV) are diagnostic tools with high accuracy rates [30]. For detecting the thrombosis in the other sites, appropriate imaging based on signs/symptoms should be obtained [42].

Laboratory workups should include; complete blood count (CBC) and

peripheral blood smear, Fibrinogen and D-dimer levels, a prothrombin time(PT), partial thromboplastin time(PTT), and PF4-ELISA (HIT assay) [32].

If a patient presents with thrombosis and a normal platelet count post-AstraZeneca COVID (ChAdOx1) or Johnson & Johnson (Ad26.CO2) vaccination, early stages of VITT should be considered [42].

3.8. Treatment strategies

In suspected patients, the use of heparin should be avoided until VITT has been ruled out [42]. Close collaboration among vascular

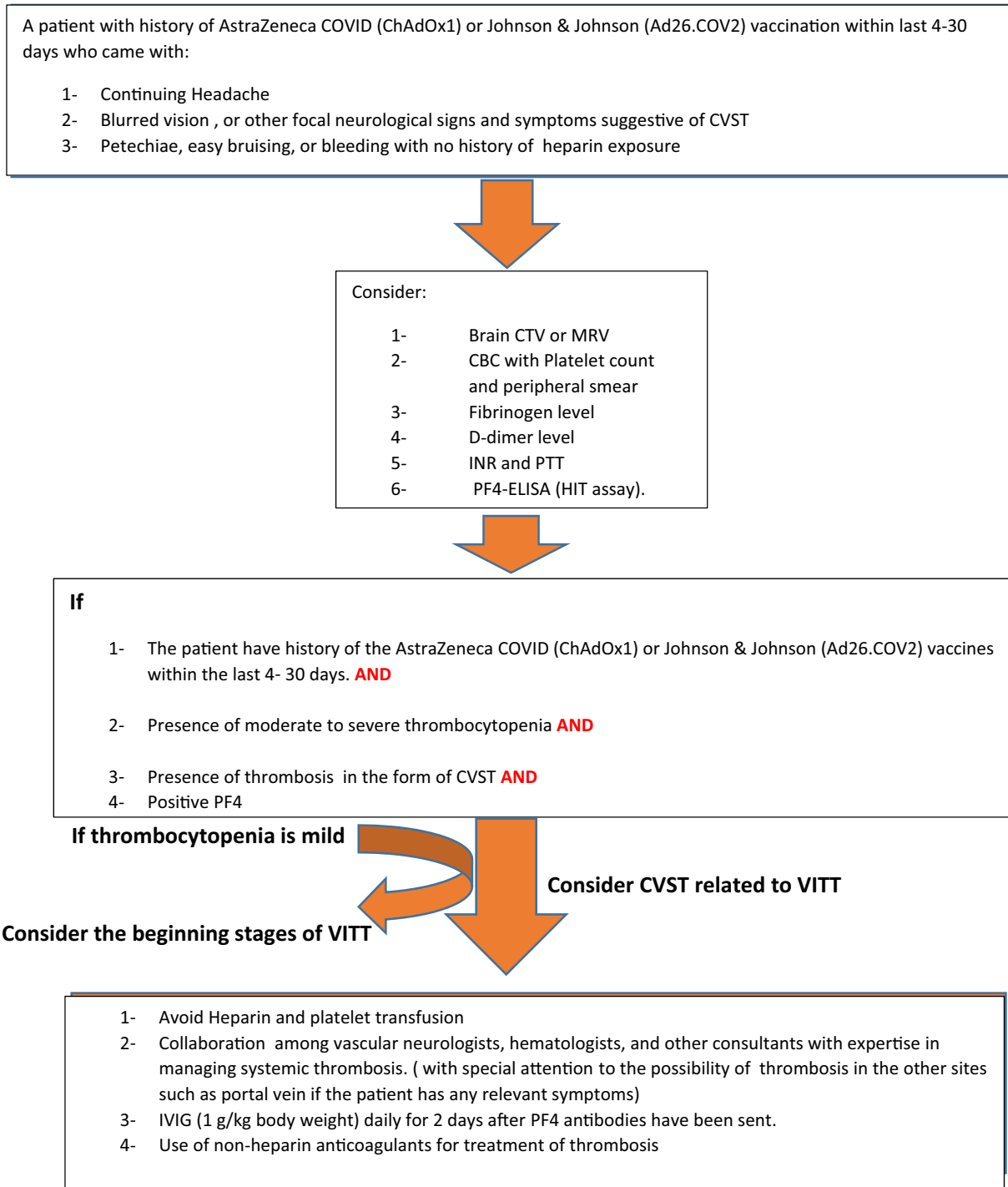


Fig. 3. Approach to the patients with CVST and VITT. CTV: computed tomography venography, MRV: Magnetic Resonance Venography, CBC: Complete Blood Count, INR: international normalized ratio, PTT: Partial Thromboplastin Time, PF4: Platelet Factor4, HIT: Heparin-induced thrombocytopenia.

neurologists, hematologists, and other consultants with relevant expertise is the cornerstone of managing VITT-associated systemic thrombosis and CVST [32]. Despite very limited data on treatment strategies, administration of intravenous immunoglobulin (IVIg) (1 g/kg body weight) daily for two days has been recommended after PF4 antibodies have been sent [32]. IVIg impedes antibody-mediated platelet clearance and may also down-regulate platelet activation by blocking platelet FcγRIIA receptors [40]. Some experts recommended using high-dose glucocorticoids, which may improve the platelet count within days [40].

Plasmapheresis could potentially be another treatment option that could temporarily reduce pathologic antibodies and correct coagulopathy [12].

Platelet transfusion should be avoided due to the risk of further antibody-mediated platelet activation and coagulopathy [12].

Use of non-heparin anticoagulants, including direct oral factor Xa inhibitors (Apixaban, Rivaroxaban), direct thrombin inhibitors (Argatroban, Bivalirudin), and Indirect (antithrombin-dependent) factor Xa inhibitors: Danaparoid, Fondaparinux, at therapeutic anticoagulant dosage might be considered [19]. In severe thrombocytopenia (i.e., <20,000 per mm³) or low fibrinogen levels, dosing strategy may require alteration [32]. In critically ill patients, parenteral agents with a short half-life are preferred [19,32]. Even in the presence of secondary ICH, anticoagulation should be used in CVST to prevent progressive thrombosis [32].

Once there is full platelet count recovery, and no other contraindications, direct oral anticoagulants or vitamin K antagonists have been suggested for subacute/chronic management [32] (Fig. 3).

3.9. Risks and benefits of vaccination

There is approximately 1 to 2% risk of mortality and several potential long-term sequelae in COVID-19 patients [4,43]. In patients with chronic underlying diseases or patients on particular medications, this rate might be even higher [44]. Conversely, Vaccination has a significant effect on the prevention of severe SARS-Cov-2 infection and ensuing complications [25] with an extremely low rate of severe complications. As initially estimated, the incidence of VITT is perhaps 1 case per 100,000 vaccine exposures [40]. Consequently, COVID-19 vaccination should be strongly encouraged given benefits outweigh its potential risks [40]. However, monitoring of the vaccines' adverse effects is essential and should be performed by the health authorities.

4. Conclusion

Health care providers should be aware of clinical presentations, pathophysiology, diagnostic criteria, and management strategies of CVST associated with VITT post-COVID-19 vaccination. Despite being very rare, this phenomenon is serious and potentially fatal. Promote diagnosis and quick initiation of the appropriate treatment may help to provide patients with a better neurological outcome [22].

Declaration of Competing Interest

None.

References

- [1] F. Vahabzad, M. Sharifian Dorche, P. Mohammadi, K. Khatibi, A. Mowla, COVID-19-related acute ischemic stroke in young adults: what is the optimal antithrombotic regimen for secondary prevention? *J. Neurol. Res.* 10 (5) (2020) 203–206.
- [2] A. Mowla, Stroke care during the COVID-19 pandemic; a global challenge, *Iran J. Med. Sci.* 45 (5) (2020) 323–324.
- [3] A. Mowla, S. Sazdahkhani, M. Sharifian-Dorche, P. Selvan, B.A. Emanuel, M. S. Tenser, et al., Unusual pattern of arterial macrothrombosis causing stroke in a young adult recovered from COVID-19, *J. Stroke Cerebrovasc. Dis.* 29 (12) (2020) 105353.
- [4] M. Sharifian-Dorche, P. Huot, M. Oshero, D. Wen, A. Saveriano, P.S. Giacomini, et al., Neurological complications of coronavirus infection; a comparative review and lessons learned during the COVID-19 pandemic, *J. Neurol. Sci.* 417 (2020) 117085.
- [5] S. Shahjouei, M. Anyaehie, E. Koza, G. Tsvigoulis, S. Naderi, A. Mowla, et al., SARS-CoV-2 is a culprit for some, but not all acute ischemic strokes: a report from the multinational COVID-19 stroke study group, *J. Clin. Med.* 10 (5) (2021).
- [6] A.F. Hernandez, D. Calina, K. Poulas, A.O. Docea, A.M. Tsatsakis, Safety of COVID-19 vaccines administered in the EU: should we be concerned? *Toxicol. Rep.* 8 (2021) 871–879.
- [7] D. Calina, A.O. Docea, D. Petrakis, A.M. Egorov, A.A. Ishmukhametov, A. G. Gabibov, et al., Towards effective COVID19 vaccines: updates, perspectives and challenges (review), *Int. J. Mol. Med.* 46 (1) (2020) 3–16.
- [8] V.R. Ostovan, R. Foroughi, M. Rostami, M. Almasi-Dooghaee, M. Esmaili, A. A. Bidaki, et al., Cerebral venous sinus thrombosis associated with COVID-19: a case series and literature review, *J. Neurol.* 22 (2021 Feb) 1–12.
- [9] I. See, J.R. Su, A. Lale, E.J. Woo, A.Y. Guh, T.T. Shimabukuro, et al., US case reports of cerebral venous sinus thrombosis with thrombocytopenia after Ad26.COV2.S vaccination, March 2 to April 21, 2021, *JAMA* 325 (24) (2021) 2448–2456.
- [10] B. Hutton, G. Salanti, D.M. Caldwell, A. Chaimani, C.H. Schmid, C. Cameron, et al., The PRISMA extension statement for reporting of systematic reviews incorporating network meta-analyses of health care interventions: checklist and explanations, *Ann. Intern. Med.* 162 (11) (2015) 777–784.
- [11] M. Voysey, S.A. Costa Clemens, S.A. Madhi, L.Y. Weckx, P.M. Folegatti, P.K. Aley, et al., Single-dose administration and the influence of the timing of the booster dose on immunogenicity and efficacy of ChAdOx1 nCoV-19 (AZD1222) vaccine: a pooled analysis of four randomised trials, *Lancet* 397 (10277) (2021) 881–891.
- [12] M. Scully, D. Singh, R. Lown, A. Poles, T. Solomon, M. Levi, et al., Pathologic antibodies to platelet factor 4 after ChAdOx1 nCoV-19 vaccination, *N. Engl. J. Med.* 384 (23) (2021) 2202–2211.
- [13] N.H. Schultz, I.H. Sorvoll, A.E. Michelsen, L.A. Munthe, F. Lund-Johansen, M. T. Ahlen, et al., Thrombosis and thrombocytopenia after ChAdOx1 nCoV-19 vaccination, *N. Engl. J. Med.* 384 (22) (2021) 2124–2130.
- [14] A. Bayas, M. Menacher, M. Christ, L. Behrens, A. Rank, M. Naumann, Bilateral superior ophthalmic vein thrombosis, ischaemic stroke, and immune thrombocytopenia after ChAdOx1 nCoV-19 vaccination, *Lancet* 397 (10285) (2021), e11.
- [15] R.A. Blauenfeldt, S.R. Kristensen, S.L. Ernsten, C.C.H. Kristensen, C.Z. Simonsen, A.M. Hvas, Thrombocytopenia with acute ischemic stroke and bleeding in a patient newly vaccinated with an adenoviral vector-based COVID-19 vaccine, *J. Thromb. Haemost.* 19 (7) (2021) 1771–1775.
- [16] G.P. Castelli, C. Pognani, C. Sozzi, M. Franchini, L. Vivona, Cerebral venous sinus thrombosis associated with thrombocytopenia post-vaccination for COVID-19, *Crit. Care* 25 (1) (2021) 137.
- [17] V. D'Agostino, F. Caranci, A. Negro, V. Piscitelli, B. Tuccillo, F. Fasano, et al., A rare case of cerebral venous thrombosis and disseminated intravascular coagulation temporally associated to the COVID-19 vaccine administration, *J. Pers. Med.* 11 (4) (2021).
- [18] M. Franchini, S. Testa, M. Pezzo, C. Glingani, B. Caruso, I. Terenziani, et al., Cerebral venous thrombosis and thrombocytopenia post-COVID-19 vaccination, *Thromb. Res.* 202 (2021) 182–183.
- [19] A. Greinacher, T. Thiele, T.E. Warkentin, K. Weisser, P.A. Kyrle, S. Eichinger, Thrombotic thrombocytopenia after ChAdOx1 nCov-19 vaccination, *N. Engl. J. Med.* 384 (22) (2021) 2092–2101.
- [20] P.R. Mehta, S. Apap Mangion, M. Bengler, B.R. Stanton, J. Czuprynska, R. Arya, et al., Cerebral venous sinus thrombosis and thrombocytopenia after COVID-19 vaccination - a report of two UK cases, *Brain Behav. Immun.* 95 (2021) 514–517.
- [21] M.E. Wolf, B. Luz, L. Niehaus, P. Bhogal, H. Bazner, H. Henkes, Thrombocytopenia and intracranial venous sinus thrombosis after "COVID-19 vaccine AstraZeneca" exposure, *J. Clin. Med.* 10 (8) (2021).
- [22] T.H. Bjornstad-Tuveng, A. Rudjord, P. Anker, Fatal cerebral haemorrhage after COVID-19 vaccine, *Tidsskr. Nor. Laegeforen.* 141 (2021).
- [23] M. Tobaigy, H. Elkout, K. MacLure, Analysis of thrombotic adverse reactions of COVID-19 AstraZeneca vaccine reported to eudravigilance database, *Vaccines (Basel)* 9 (4) (2021).
- [24] N.B. Mercado, R. Zahn, F. Wegmann, C. Loos, A. Chandrashekar, J. Yu, et al., Single-shot Ad26 vaccine protects against SARS-CoV-2 in rhesus macaques, *Nature* 586 (7830) (2020) 583–588.
- [25] FDA authorizes Johnson & Johnson COVID-19 vaccine, *Med. Lett. Drugs Ther.* 63 (1620) (2021) 41–42.
- [26] J.R. MacNeil, J.R. Su, K.R. Broder, A.Y. Guh, J.W. Gargano, M. Wallace, et al., Updated recommendations from the advisory committee on immunization practices for use of the Janssen (Johnson & Johnson) COVID-19 vaccine after reports of thrombosis with thrombocytopenia syndrome among vaccine recipients - United States, April 2021, *MMWR Morb. Mortal. Wkly Rep.* 70 (17) (2021) 651–656.
- [27] K.L. Muir, A. Kallam, S.A. Koepsell, K. Gundabolu, Thrombotic thrombocytopenia after Ad26.COV2.S vaccination, *N. Engl. J. Med.* 384 (20) (2021) 1964–1965.
- [28] B. Shakibajahromi, A. Borhani-Haghighi, S. Haseli, A. Mowla, Cerebral venous sinus thrombosis might be under-diagnosed in the COVID-19 era, *eNeurologicalSci* 20 (2020) 100256.
- [29] B. Shakibajahromi, A. Borhani-Haghighi, M. Ghaedian, F. Feiz, H. Molavi Vardanjani, A. Safari, et al., Early, delayed, and expanded intracranial hemorrhage in cerebral venous thrombosis, *Acta Neurol. Scand.* 140 (6) (2019) 435–442.
- [30] B. Shakibajahromi, A.B. Haghighi, A. Salehi, H.M. Vardanjani, M. Ghaedian, A. Safari, et al., Clinical and radiological characteristics and predictors of outcome

- of cerebral venous sinus thrombosis, a hospital-based study, *Acta Neurol. Belg.* 120 (4) (2020) 845–852.
- [31] A. Mowla, B. Shakibajahromi, S. Shahjouei, A. Borhani-Haghighi, N. Rahimian, H. Baharvahdat, et al., Cerebral venous sinus thrombosis associated with SARS-CoV-2; a multinational case series, *J. Neurol. Sci.* 419 (2020) 117183.
- [32] American Heart Association/American Stroke Association Stroke Council L, Diagnosis and management of cerebral venous sinus thrombosis with vaccine-induced thrombotic thrombocytopenia, *Stroke* 52 (7) (2021) 2478–2482.
- [33] I. Yavasoglu, Vaccination and thrombotic thrombocytopenic Purpura, *Turk. J. Haematol.* 37 (3) (2020) 218–219.
- [34] R.C. Brown, T.E. Blecher, E.A. French, P.J. Toghil, Thrombotic thrombocytopenic purpura after influenza vaccination, *Br. Med. J.* 2 (5861) (1973) 303.
- [35] Y. Kojima, H. Ohashi, T. Nakamura, H. Nakamura, H. Yamamoto, Y. Miyata, et al., Acute thrombotic thrombocytopenic purpura after pneumococcal vaccination, *Blood Coagul. Fibrinolysis* 25 (5) (2014) 512–514.
- [36] G. Kadikoylu, I. Yavasoglu, Z. Bolaman, Rabies vaccine-associated thrombotic thrombocytopenic purpura, *Transfus. Med.* 24 (6) (2014) 428–429.
- [37] R. Hermann, A. Pfeil, M. Busch, C. Kettner, D. Kretzschmar, A. Hansch, et al., Very severe thrombotic thrombocytopenic purpura (TTP) after H1N1 vaccination, *Med Klin (Munich)* 105 (9) (2010) 663–668.
- [38] N. Ramakrishnan, L.P. Parker, Thrombotic thrombocytopenic purpura following influenza vaccination—a brief case report, *Conn. Med.* 62 (10) (1998) 587–588.
- [39] C. Vayne, T.H. Nguyen, J. Rollin, N. Charuel, A. Poupon, C. Pouplard, et al., Characterization of new monoclonal PF4-specific antibodies as useful tools for studies on typical and autoimmune heparin-induced thrombocytopenia, *Thromb. Haemost.* 121 (3) (2021) 322–331.
- [40] D.B. Cines, J.B. Busse, SARS-CoV-2 vaccine-induced immune thrombotic thrombocytopenia, *N. Engl. J. Med.* 384 (23) (2021) 2254–2256.
- [41] A. Greinacher, K. Selleng, T.E. Warkentin, Autoimmune heparin-induced thrombocytopenia, *J. Thromb. Haemost.* 15 (11) (2017) 2099–2114.
- [42] K.R. McCrae, Thrombotic thrombocytopenia due to SARS-CoV-2 vaccination, *Cleve. Clin. J. Med.* (2021 May 6).
- [43] A.A. Dmytriw, K. Phan, C. Schirmer, F. Settecase, M.K.S. Heran, A. Efendizade, et al., Ischaemic stroke associated with COVID-19 and racial outcome disparity in North America, *J. Neurol. Neurosurg. Psychiatry* 91 (12) (2020) 1362–1364.
- [44] M. Sharifian-Dorche, M.A. Sahraian, G. Fadda, M. Osherov, A. Sharifian-Dorche, M. Karaminia, et al., COVID-19 and disease-modifying therapies in patients with demyelinating diseases of the central nervous system: a systematic review, *Mult. Scler. Relat. Disord.* 50 (2021) 102800.