

Intradural Herniated Cervical Disk: A Case Report and Review of the Literature

Robert A. Eisenberg,¹ Alfonso M. Bremer,² and H. Martin Northup¹

The herniation of intervertebral disk material into the dural sac is a rare occurrence; a total of 50 cases have been reported in the literature. Forty-five (90%) are reported in the lumbar spine, most at the L4–L5 interspace, three (6%) in the cervical spine [1, 2, 3], and two (4%) in the thoracic spine [4]. The lesion is reported to have a typical, irregular intradural defect on myelography [5]. We report a case, however, in which conventional myelography was not sufficiently specific, and metrizamide-enhanced CT was essential in the diagnosis.

Case Report

On May 28, a 25-year-old white male reported pain on the left neck and deltoid region that had increased over a four-day period. The pain was accompanied by weakness, which progressed to involve portions of the left upper extremity. Left-arm weakness had progressed to a grip strength of $\frac{1}{5}$, and the patient was unable to ambulate due to left-side weakness and ataxia. Physical examination revealed loss of pain and temperature sensation on the right from T3 inferiorly. Sensory examination of the left side was normal. Bilateral ankle clonus was present. Rectal and urinary sphincters were normal.

Past history revealed a recent work-related neck and back strain secondary to lifting heavy objects, and a motor vehicle accident from several years ago that was followed briefly by intermittent neck pain and stiffness.

Clinical findings suggested an incomplete Brown-Séquard lesion on the left in the lower cervical spine. Cervical radiographs were normal, and emergency Pantopaque myelography was performed. Contrast flowed to the level of the clivus without evidence of obstruction. Anteroposterior radiograph studies revealed apparent widening of the spinal cord from C6 to the C5–C6 interspace, with right-sided thinning of the subarachnoid space as well as a localized superimposed defect on the left at the C5–C6 interspace (Fig. 1). This configuration suggested the presence of an intradural lesion. But on lateral views, the suspected intradural lesion was not seen, and a metrizamide-enhanced CT scan was obtained for further diagnostic evaluation.

Metrizamide-enhanced CT revealed an extradural soft-tissue density midline and to the left, ventral to the dural sac at the C6 level. The dural sac was asymmetric and flattened anteriorly with flattening and displacement of the cervical cord to the right (Fig. 2).

An area of soft-tissue density occupied the left anterior dural sac at the C5–C6 interspace causing displacement of the spinal cord to the right and thinning of the metrizamide column on the right. Metrizamide was seen within the dural sac between the displaced cervical cord and the intradural disk fragment. There was an area of dural-sac irregularity in the midline of the ventral dural sac, with decreased

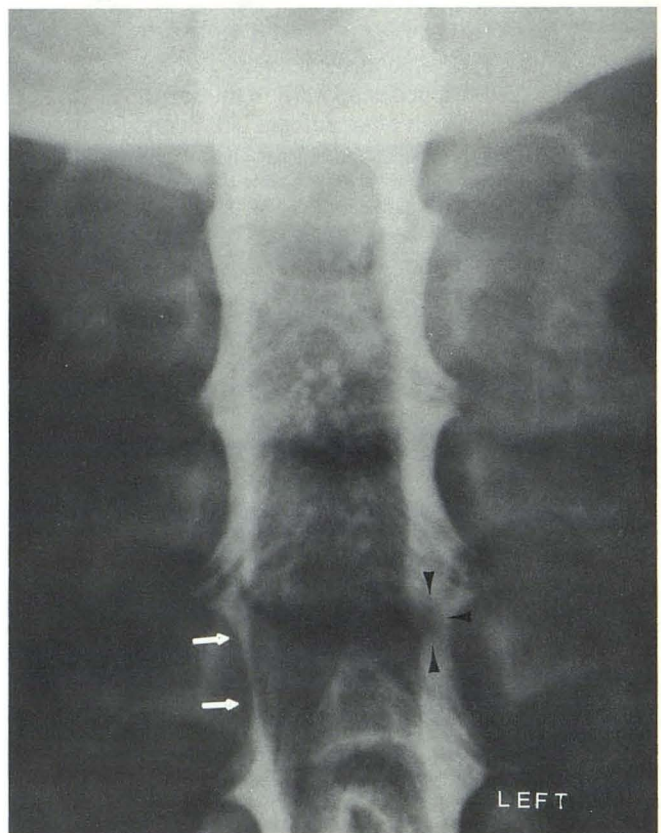


Fig. 1.—Pantopaque myelogram. Narrowed subarachnoid space on the right with apparent widening of the spinal cord (white arrows) and intradural filling defect at the C5–C6 interspace (black arrowheads).

Received October 18, 1984; accepted after revision March 14, 1985.

¹ Department of Radiology, University of Florida/Jacksonville Programs, University Hospital of Jacksonville, 655 West Eighth Street, Jacksonville, FL 32209. Address reprint requests to R. A. Eisenberg.

² Department of Neurosurgery, University of Florida/Jacksonville Programs, University Hospital of Jacksonville, 655 West Eighth Street, Jacksonville, FL 32209.

AJNR 7:492–494, May/June 1986 0195–6108/86/0703–0492 © American Society of Neuroradiology

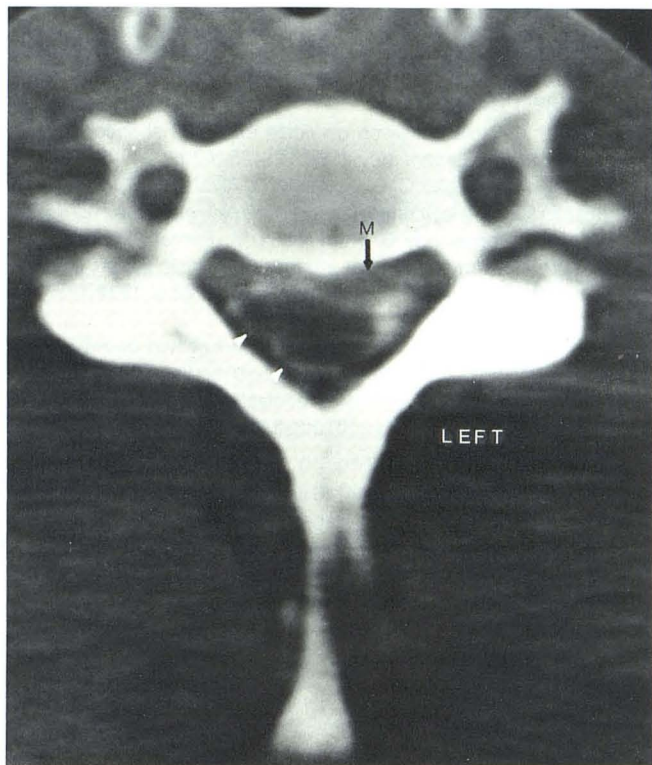


Fig. 2.—Metrizamide CT scan at C6 level shows thinning of the metrizamide column on the right (*white arrowheads*), epidural soft-tissue mass (M), and asymmetry of the dural sac with cervical cord displacement to the right.

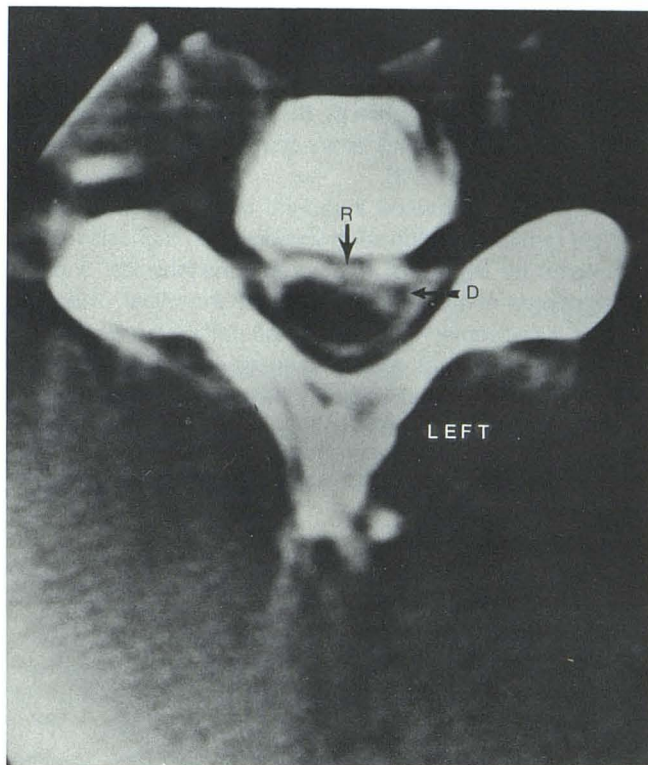


Fig. 3.—Metrizamide CT scan at C5-C6 interspace with intradural disk fragment (D). Note the irregularity of the ventral dural sac with metrizamide within the dural sac between the disk fragment (D) and the displaced spinal cord. The metrizamide apparently entered the dural sac through rupture site (R).

density in the metrizamide column: this represented the apparent site of sac rupture (Fig. 3).

Operation

On June 1, a C5-C6 laminectomy was performed with the patient in the prone position. Examination revealed no extradural lesion. The dura was then opened in the midline. The left half of the spinal cord was mildly displaced posteriorly and toward the right side; and a small disk fragment impinging on the spinal cord was noticed. After the laminectomy at C6 on the left was extended by using a variable high-speed drill, the ruptured intradural cervical disk was removed easily without retraction of the spinal cord. The patient experienced immediate and total relief of pain in the left upper extremity. There was gradual neurologic improvement after the operation. When seen again 1 month later, the patient was able to walk without assistance.

At 2 month after surgery, the patient remains pain-free and continues to slowly regain strength in his left arm. His sensation to pain, temperature, and touch on the right has improved, but deficits still remain.

Discussion

Intradural herniation of a cervical disk was first reported by Marega in 1959 [2]. Durig and Zdrojewski in 1977 [1] and

Roda, et al. in 1982 [3] described two additional cases. A history of trauma was present in all cases reported. Acute strain injury followed by symptoms of cord compression within 24 hr occurred in two cases [2, 3]. The remaining case [1] and this present case involved individuals who had prior neck injuries (both without serious sequelae) including symptoms that were exacerbated by recent strenuous activity. All patients presented with signs of cord compression; that is, acute pain, progressive weakness, and sensory deficits [1, 2, 3].

Smith [5] first described the myelographic findings of an irregular marginated filling defect involving the intradural herniation of disk material in the lumbar spine. In the cervical spine, two reported cases showed a large irregular intradural filling defect causing complete block at C5-C6 [2] and C6-C7 [3]. Myelographic study of our patient showed only a subtle abnormality; the characteristic filling defect reported by Smith [5] was not seen. In this case, metrizamide-enhanced CT was the most useful technique to establish a preoperative diagnosis.

Hodge, et al. [6] first postulated the usefulness of metrizamide in combination with CT to further delineate the intradural lesion and its relation to surrounding vertebral bodies, nerves, dural sac, and the subarachnoid space. This technique may also help in the evaluation of other intradural lesions of the cervical spine that may simulate herniated disk.

Many observers feel the pathogenesis of intradural disk herniation involves dense adhesions between the dura and the posterior longitudinal ligament preventing the more common epidural disk herniation [5, 6]. A tear in the anterior dural sac was identified during laminectomy in all cases reported previous to ours [1, 2, 3].

In summary, herniated intradural cervical disk is an extremely rare and serious complication. The diagnosis may be suspected by history of trauma and the physical findings. Conventional myelography should be the initial diagnostic test, as it frequently will delineate the pathology. However, if these findings are not definite, the use of metrizamide-CT is quite helpful in further delineating the anatomy, narrowing the differential diagnosis, and planning the surgical approach.

REFERENCES

1. Durig M, Zdrojewski B. Intradural sequestration einer cervikalen diskoshermie ein kasuistischer. *Arch Orthop Trauma Surg* **1977**;87:151-157
2. Marega T. Ernia del disco cervicale espulsa nel sacco durale. *Arch Putti Chir Organi Mov* **1959**;12:425-430
3. Roda J M, Gonzalez C, Blazquez M G, Alvarez M P, Arquello C. Intradural herniated cervical disk. *J Neurosurg* **1982**;57:278-280
4. Lesion F, Duquennoy B, Rousseaux M, Servato R, Tomin M. Intradural rupture of lumbar intervertebral disk: report of three cases and review of the literature. *Neurosurgery* **1984**;14:728-731
5. Smith R V. Intradural disk rupture: report of two cases. *J Neurosurg* **1981**;55:117-120
6. Hodge C J, Binet E F, Kieffer S A. Intradural herniation of lumbar intervertebral disks. *Spine* **1978**;3:346-350