

## Acoustic Neuromas in Children

Marta Hernanz-Schulman,<sup>1,2</sup> Kasley Welch,<sup>3</sup> Roy Strand,<sup>1</sup> and Joe I. Ordia<sup>3,4</sup>

Acoustic neuromas are rare in children. We report a girl without neurofibromatosis in whom a left cerebellopontine angle malignant schwannoma was confirmed at age 20 months.

### Case Report

A 20-month-old girl, previously well, presented with a history of several weeks of progressive left facial weakness. On physical examination, the patient was noted to have a dense hearing loss and peripheral facial palsy on the left. Examination by computed tomography (CT) showed a noncalcified, inhomogeneously enhancing 2.2-cm mass in the left cerebellopontine angle with moderate widening of the ipsilateral internal auditory canal (Fig. 1). The mass was excised surgically. Neuropathologic examination showed a moderately to highly cellular tumor with 2–3 mitoses per high-power field. The cells tended to form palisades and no areas of necrosis were identified.

Trichrome stain showed a large amount of collagen to be present in the tumor's matrix, and reticulin stain revealed an extensive reticulin network. Stain for gliofibrillary acid protein (GFAP) with the immunoperoxidase method showed a fine network of GFAP-positive material in the collagenous portion of the tumor but not within the cells. The neuropathologist suggested that this represented fibrillary astrogliosis in brain tissue trapped within the tumor. Electron microscopic study was consistent with a fairly well differentiated malignant schwannoma.

The patient remained well for 1 year, but a follow-up CT scan showed a recurrence of the cerebellopontine angle tumor. Reexploration revealed a recurrent tumor mass encasing the fifth nerve. Removal of the entire gross tumor mass was achieved, but this necessitated sacrificing the fifth nerve. The pathologic report was once again consistent with malignant schwannoma. As an adjunct, 5500 rad were given to the area over a 6-week period. As of this writing, 1 year after the recurrence, the patient has remained clinically stable and free of gross tumor on serial follow-up CT scans.

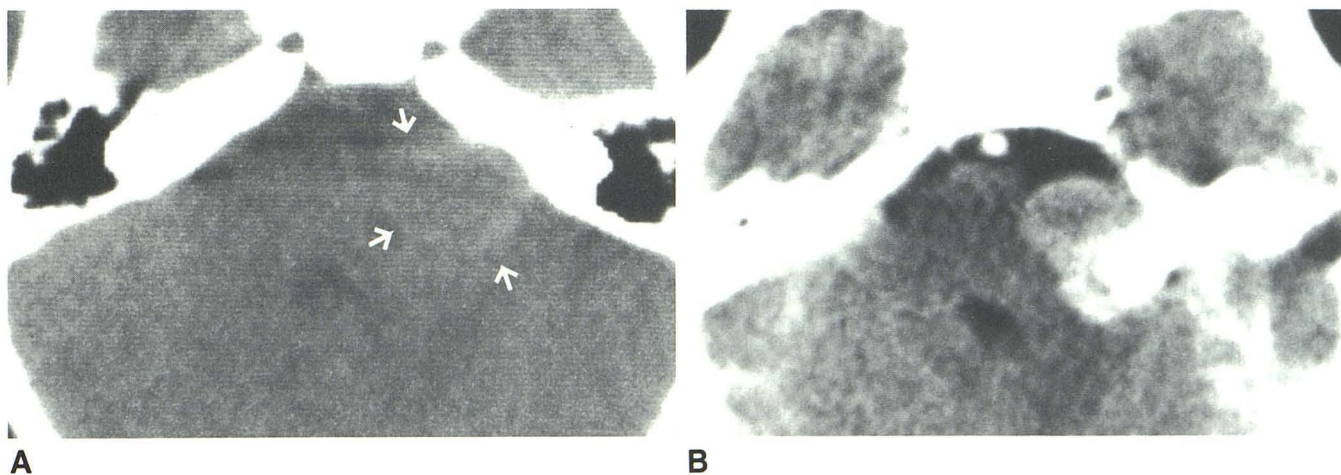


Fig. 1.—A, Unenhanced scan at level of internal auditory meati shows slightly hyperdense mass (arrows) protruding from left porus acusticus, compressing pons and fourth ventricle. No calcifications are present. Smooth concavity along posterior aspect of petrous bone was continuous with enlarge-

ment of internal acoustic canal. B, Scan at same level as above after intravenous contrast medium. Mass shows partly intense, inhomogeneous enhancement. Widening of ipsilateral prepontine cistern is evident, indicating extraaxial origin of the tumor.

Received May 23, 1985; accepted after revision October 16, 1985.

<sup>1</sup>Department of Radiology, The Children's Hospital, Boston, MA 02115. Address reprint requests to Marta Hernanz-Schulman, Department of Pediatric Radiology, Bellevue Hospital, Room 3 North 25, 27th and 1st Avenue, New York, NY 10016.

<sup>2</sup>New York University Medical Center, Department of Radiology, 550-560 First Avenue, New York, NY 10016.

<sup>3</sup>Department of Neurological Surgery, The Children's Hospital, Boston, MA 02115.

<sup>4</sup>Department of Neurological Surgery, Boston University Medical Center, Boston, MA 02118.

**TABLE 1: Reported Cases of Patients Less Than 15 Years Old with Unilateral Acoustic Neurinomas**

Reference No.	Report	Age (years)	Sex	Side	Presentation
1.	Rushworth, 1984	9	Male	Rt.	HL; imbalance; VIII; V; hydrocephalus
2.	Vassilouthis, 1984	10	Female	Rt.	HL; VIII; V; hydrocephalus
3.	Laha, 1975	10	Female	Rt.	Headache; nausea; rt. arm imbalance × 5 months; HL × 5 years
4.	Fabiani, 1975	1	Male	—	Neonatal hydrocephalus; origin not demonstrated
5.	Anderson, 1972	13	Male	Rt.	HL × 2 years; imbalance × 4 months; diplopia × 3 weeks
6.	Krause, 1971	7	Female	Rt.	HL × 1 year; sudden VII
7.	House, 1968	14	—	—	HL × 1 year; VII; imbalance
8.	Erickson, 1944	13	—	—	—
9.	Bjorkesten, 1955	10	Female	Rt.	—
10.	Craig, 1954	11	Male	Lt.	HL; tinnitus × 8 months; VII; VIII (depressed corneals); lt. arm imbalance × 1 month
11.	Craig, 1954	14	Female	Lt.	HL; tinnitus × 5 years
12.	Mark, 1952	8	Male	Lt.	Transient VII at 6 years; HL; tinnitus; VII × 1 year
13.	Hodes, 1949	14	Male	Lt.	Tinnitus × 3 years; HL; imbalance; VII × 3 weeks; VIII (depressed corneals)
14.	Bager, 1944	13	—	—	—

Note:—Dash (—) indicates not given in report. HL = hearing loss. Roman numerals in "Presentation" column represent cranial nerves. × in "Presentation" column means "for." None of these patients had neurofibromatosis.

## Discussion

In a review of the literature, we found only 14 cases of acoustic tumors in patients less than 15 years old (Table 1) [1–13]. There are earlier reports of acoustic tumors in younger patients, but the exact ages of these children are not given [10]. In any case, none of the childhood tumors reported in the literature was diagnosed as malignant schwannoma.

The youngest patient reported to date was described by Fabiani in 1975 [4]. This patient presented at birth with hydrocephalus and was found to have a massive posterior fossa mass at the age of 12 months; although the histopathology was consistent with the diagnosis of schwannoma, the side and site of origin of the tumor could not be determined. Except for this case, the youngest reported case of unilateral acoustic neuroma was a 7-year-old girl, reported by Krause in 1971 [6]. This patient had experienced symptoms referable to the tumor since the age of 6 years.

Acoustic neuromas or schwannomas usually arise from the vestibular division of the eighth cranial nerve. They are most prevalent in older age groups (fifth to sixth decades), and are common in the setting of Von Recklinghausen's disease. When bilateral, they are considered to be diagnostic of central neurofibromatosis [14]. They may present as small intracanalicular masses with hearing loss, tinnitus, and dysequilibrium, or when larger and extruding from the porus acusticus, as a

cerebellopontine angle mass in a patient with diplopia, headache, and facial paresis.

Unilateral acoustic neuromas in the setting of neurofibromatosis tend to present earlier, at about the third decade [15]. Neither our patient nor any of the other young patients who were discussed in the literature, however, had any diagnostic manifestations of neurofibromatosis.

Among the pediatric cases, unilateral acoustic neuroma has an equal gender distribution and there is no apparent predilection for either side. None of the previously reported cases was considered to be malignant at the time of report.

As previously noted [12], the clinical presentation of acoustic neuroma in children closely resembles that found in adults. Hearing loss is almost invariably the first symptom. However, in younger patients, the onset of this symptom is difficult, if not impossible, to determine. Hearing loss is thought to be a secondary symptom, caused by compression of the cochlear nerve or labyrinthine artery within the internal auditory canal as a result of the enlarging intracanalicular tumor [16].

Vestibular symptoms of dysequilibrium also occur. As the tumor enlarges and extends into the subarachnoid space in the cerebellopontine angle, symptoms occur because of compression of the fifth and seventh nerves or their vascular supply. The latter mechanism is thought to explain cases of spontaneously regressing VII nerve palsy [16], such as that reported by Craig [10]. Continued growth leads to pressure

on the fourth ventricle and midbrain with hydrocephalus, increased intracranial pressure, cerebellar and pyramidal syndromes, and palsy of the lower cranial nerves. The diagnosis is strongly suggested by CT. The characteristic features of this tumor on CT are well known [16].

Malignant schwannomas occur both in the presence and absence of neurofibromatosis. They are most commonly seen in the extremities (68%), in the trunk (16%), and in the head and neck (8%). They may occur in up to 30% of patients with Von Recklinghausen's disease and, in this setting, favor a truncal location to the extremities. In a series of 165 patients with malignant schwannomas [17], 40% had other stigmata of neurofibromatosis. The median age of occurrence was 32 years among those patients with Von Recklinghausen's disease, but it was 48 years among those patients without neurofibromatosis. Two patients were 2 years old. The clinical course tends to be one of local recurrence with distant metastases occurring late in the diseases, usually in patients with Von Recklinghausen's disease.

### Summary

Although unilateral acoustic neuromas in children are rare, they do occur. There is no gender predilection and the clinical symptoms and signs are similar to those seen in adults. They tend to occur in the absence of neurofibromatosis and are usually benign. Our patient is the youngest yet reported with documented unilateral acoustic neuroma; moreover, she is the first child in whom this tumor has been proven to be malignant both by histopathology and subsequent clinical behavior.

### REFERENCES

1. Rushworth RG, Sorby WA, Smith SF. Acoustic neuroma in a child treated with the aid of preoperative arterial embolization. *J Neurosurg* **1984**;61:396-398
2. Vassilouthis J, Richardson AE. Acoustic neurinoma in a child. *Surg Neurol* **1979**;12:37-39
3. Laha RJ, Huestis WS. Unilateral acoustic neuroma and cerebellopontine angle lesions in children. *Surg Neurol* **1975**;4:371-374
4. Fabiani A, Croveri G, Torta A. Neurinoma de la fossa posteriore in un bambino di un anno. *Acta Neurol (Napoli)* **1975**;30:218-222
5. Anderson MS, Bentinck BR. Intracranial schwannoma in a child. *Cancer* **1972**;29:231-234
6. Krause CJ, McCabe BF. Acoustic neuroma in a 7-year-old girl. *Arch Otolaryng* **1971**;94:359-363
7. House WF. Case summaries monograph II. *Arch Otolaryng* **1968**;88:586-591
8. Erickson LS, Sorenson GD, McGavran MH. A review of 140 acoustic neurinomas. *Laryngoscope* **1965**;75:601-627
9. Björkstén G. Unilateral acoustic tumors in children. *Acta Neurol et Psychiat (Scand)* **1956**;13:215-218
10. Craig WM, Dodge HW, Ross PJ. Acoustic neuromas in children: report of 2 cases. *J Neurosurg* **1954**;11:505-508
11. Mark VH, Sweet WH. An unusual case of unilateral eighth nerve tumor. *J Neurosurg* **1952**;9:395-397
12. Hodes PJ, Pendegrass EP, Young BR. Eighth nerve tumors: their roentgen manifestations. *Radiology* **1949**;53:633-665
13. Bager CC. The differential diagnosis between acoustic neuroma and meningioma of the posterior fossa of the petrous bone. *Acta Psych Neuro* **1944**;19:23-31
14. Kanter WR, Eldridge R, Fabricant R, Allen JC, Koerber T. Central neurofibromatosis with bilateral acoustic neuroma; genetic, clinical and biochemical distinctions from peripheral neurofibromatosis. *Neurology* **1980**;30:851-859
15. Revilla AG. Neurinomas of the cerebellopontine recess. *Bull Johns Hopkins Hosp* **1947**;80:254-296
16. Colnet H, Malgat R, Guibert-Tranier F, Piton J, Caille JM. Acoustic neurinomas: clinical and radiologic correlations. *J Neuroradiology* **1983**;10:301-314
17. Sordillo PP, Helson L, Hajdu SI, et al. Malignant schwannoma—clinical characteristics, survival and response to therapy. *Cancer* **1981**;47:2503-2509