

CT Evaluation of the Temporal Bone Ossicles by Using Oblique Reformations: A Technical Note

Benjamin C. P. Lee,^{1,2} Michael L. Black,¹ Robert B. Lamb,¹ Jerry P. Arnold,¹ James A. Seibert,¹ Richard A. Chole,³ and Gloria V. Bacon¹

Involvement of the ossicular chain by temporal bone disease can seldom be evaluated adequately on routine axial and coronal CT views [1–5]. Direct sagittal tomography views delineate these structures clearly [6, 7], but CT views require considerable manipulation of cooperative patients and are seldom reproducible in the exact planes in repeated examinations [8, 9]. High-resolution lateral oblique views reconstructed from axial sections appear to be the ideal method of visualizing the detailed anatomy of the ossicles.

Materials and Methods

Axial sections were obtained on Toshiba TCT-900S and TCT-600S scanners and GE 8800 scanners. Scans were 1–1.5-mm thick with 1-mm contiguous spacing. A low mAs technique (150–200 mAs) with bone algorithm and dynamic scanning was used. Total scanning time

ranged from 60 to 580 sec, and image reconstruction was processed after completion of the examinations. Coronal reformations through the ossicles were then made on independent viewing consoles with these views used as guides. Lateral and axial oblique reformations were oriented precisely parallel to the axis of the malleus, incus, and stapes (Fig. 1).

Thirty normal and 30 abnormal cases were examined. The abnormal cases included four congenital lesions, three ossicular disruptions, 20 cholesteatomas, and three tumors.

Results

Normal Anatomy (30 Cases)

The long axis of the malleus was less oblique in the coronal plane, compared with the incus. As a result, reformatted sections oriented along the long axis of each ossicle demon-

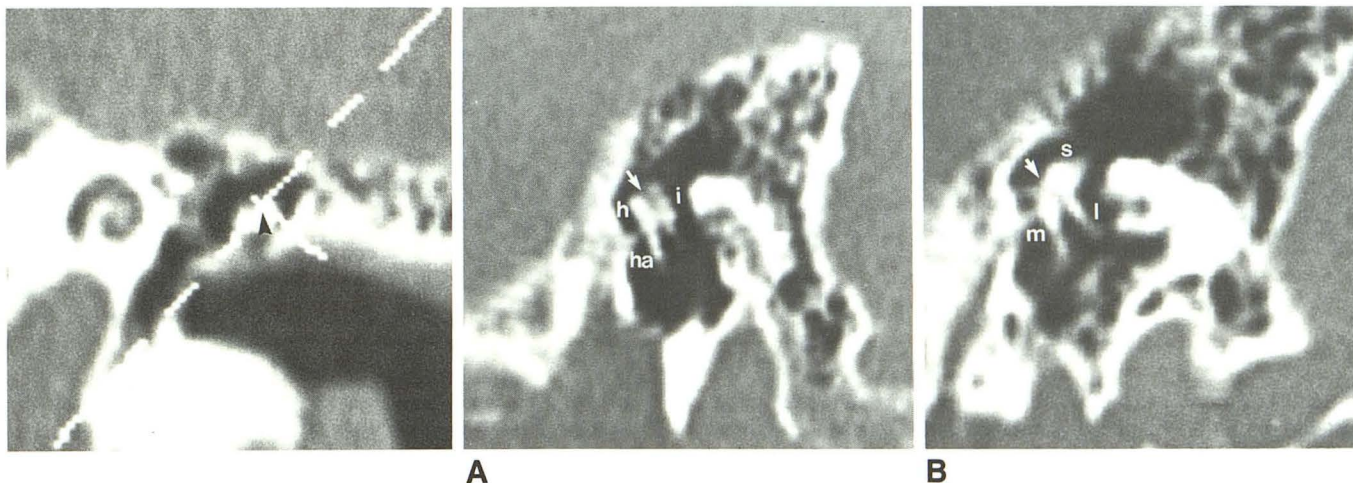


Fig. 1.—Reformatted anteroposterior view. Cursor, aligned along malleus, demonstrates orientation of lateral oblique reformatting. Angle of obliquity is altered at fulcrum of rotation (arrowhead).

Fig. 2.—Lateral oblique views.
A, Along the long axis of malleus, head (h) and handle (ha) can be seen; only a portion of the incus (i) is seen. Arrow points to malleoincudal joint.
B, Along the axis of incus, a portion of short process of incus (s) and entire long process (l) can be seen; a portion of the malleus (m) is visible. Arrow points to malleoincudal joint.

Received March 2, 1988; accepted after revision June 2, 1988.

¹ Department of Radiology, University of California, Davis Medical Center, Sacramento, CA 95817.

² Present address: Department of Radiology, University of Minnesota Hospital and Clinic, Box 292, UMHC, Harvard St. at East River Rd., Minneapolis, MN 55455. Address reprint requests to B. C. P. Lee.

³ Department of Otorhinolaryngology, University of California, Davis Medical Center, Sacramento, CA 95817.

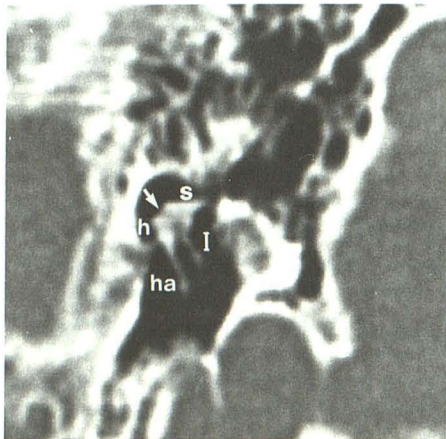
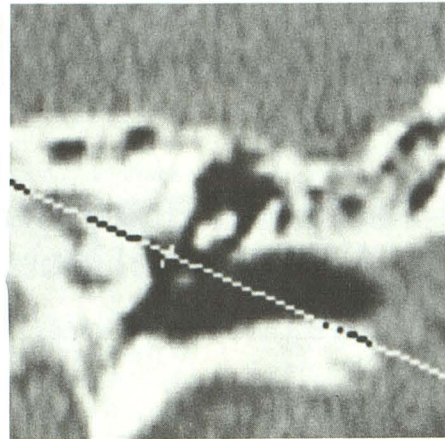
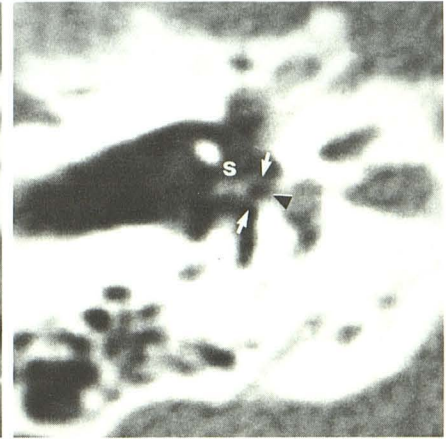


Fig. 3.—Lateral oblique view, intermediate inclination between long axis of malleus and incus, shows malleo-incudal joint (arrow), short process of incus projecting toward aditus (s), and both roots of "molar tooth." ha = malleus handle, I = incus long process, h = malleus head.

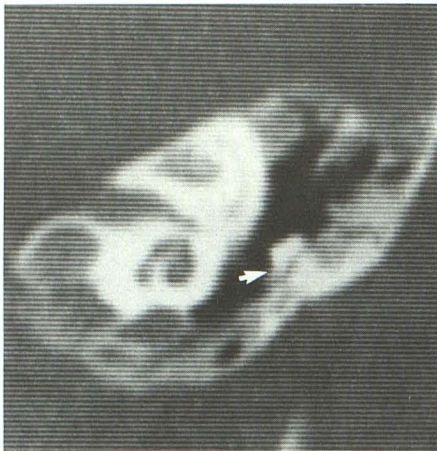


A

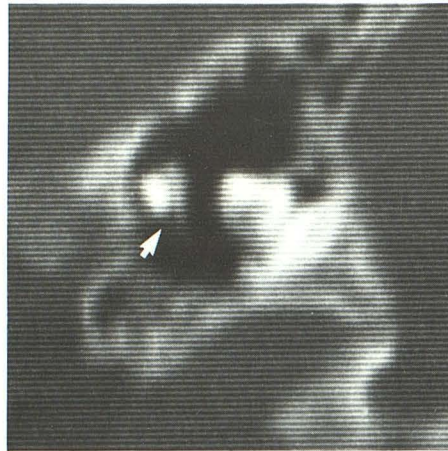


B

Fig. 4.—A, Anteroposterior views show orientation of axial oblique view along axis of stapes. B, View along this plane shows stapes (s) and footplate (arrowhead). The two crura of the stapes are visible (arrows).



A



B

Fig. 5.—Partial atresia of the external and middle ear.

A, Anteroposterior view shows ossicle adherent to atretic external ear (arrow).

B, Lateral oblique view shows atresia of handle of malleus (arrow).

strated the particular ossicle in its entirety but only a portion of the adjacent one (Fig. 2). Oblique lateral sections with intermediate angulations between the long axis of the malleus and the incus appeared to be most useful in evaluating the malleo-incudal joint and the "molar tooth" appearance of the handle of the malleus and long process of the incus. The head of the malleus and the short process of the incus were always at the same level within the epitympanum; the latter pointed directly toward the aditus (Fig. 3). In addition to demonstrating the ossicles, the lateral oblique view visualized the direct continuity between the tympanic cavity, epitympanum, aditus, and antrum. An axial oblique view along the long axis of the stapes revealed the oval window and footplate of the stapes

in all cases. In addition, it was often possible to visualize the two crura of the stapes in this view (Fig. 4).

Abnormal Anatomy (30 Cases)

Various degrees of atresia of the middle and external ears were demonstrated, including partial absence of the malleus in one case (Fig. 5). All ossicular disruptions involved downward displacement of the malleus, with additional rotation of this ossicle in one case (Fig. 6). The extent of cholesteatoma involvement varied, but partial ossicular destruction was shown in four cases (Fig. 7). Neoplastic destruction of the ossicles was shown in three cases.

Fig. 6.—Ossicular disarticulation. Lateral oblique view shows widening of malleoincudal joint (arrowhead). Short process of incus is invisible (arrow), indicating 180° rotation.

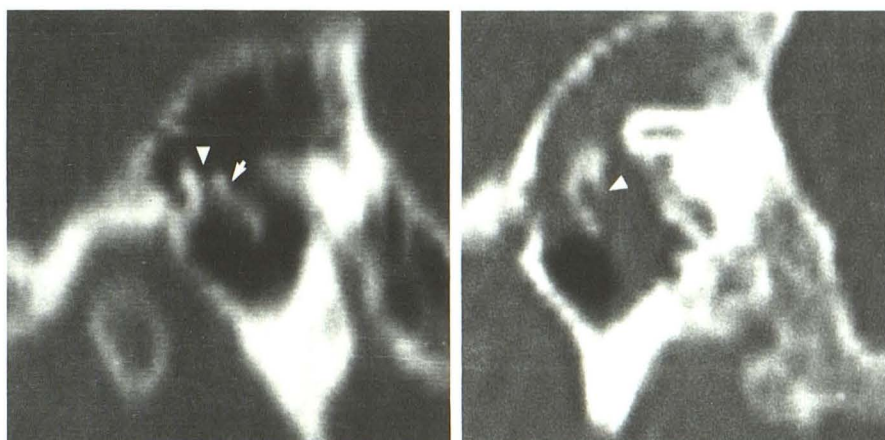


Fig. 7.—Cholesteatoma. Lateral oblique view shows slight thinning of both ossicles. Long process of incus is destroyed (arrowhead); cholesteatoma extends into aditus and antrum.

6

7

Discussion

The advantages of low mAs bone algorithm techniques for temporal bone examinations are speed and low radiation. Skin dose is approximately a quarter of that delivered when normal techniques are used [10, 11]. As the X-ray anode does not overheat with such techniques, sequential scans may be performed uninterrupted, and a complete axial examination consisting of 30–40 sections may be performed in less than 2 min. Because the subject lies in a comfortable position for only a short time, movement is usually absent except in extremely uncooperative patients. Opacities in the air cells and middle ear structures are always visible, although contrast enhancement cannot be detected without using higher mAs techniques [1, 2].

The function of the ossicular chain accounts for the configuration and orientation of the ossicles [12]. The lateral oblique view is optimal for visualizing the malleoincudal joint and the location of the adjacent portion of the ossicles within the epitympanum. Views with various inclinations may be necessary to completely evaluate different portions of the individual ossicles. The inferior tip of the handle of the malleus is attached to the tympanic membrane and is more laterally situated than the most inferior portion of the long process of the incus, which is attached medially to the stapes. In lateral oblique views the short process of the incus is routinely seen to be situated within the epitympanum, pointing posteriorly. Visualization of different portions of the stapes is, at present, limited by the spatial resolution of available CT scanners. The crura of this structure are sometimes seen in axial views obliquely angled along the long axis of this ossicle. A disad-

vantage of oblique lateral views is the inability to visualize the entire vertical portion of the facial canal, which requires views in the true lateral plane for complete evaluation.

REFERENCES

1. Virapongse C, Rothman SLG, Kier EL, Sarwar M. Computed tomographic anatomy of the temporal bone. *AJNR* 1982;3:379–389
2. Olson JE, Dorwart RH, Brant WE. Use of high resolution thin section CT scanning of the petrous bone in temporal bone anomalies. *Laryngoscope* 1982;92:1274–1278
3. Swartz JD. High resolution computed tomography of the middle ear and mastoid. Part I: normal radioanatomy including normal variations. *Radiology* 1983;148:449–454
4. Swartz JD, Goodman RS, Russell KB, Marlowe FL, Wolfson RJ. High resolution computed tomography of the middle ear and mastoid. Part II: tubotympanic disease. *Radiology* 1983;148:455–459
5. Swartz JD, Goodman RS, Russell KB, Ladenheim SE, Wolfson RJ. High resolution computed tomography of the middle ear and mastoid. Part III: surgically altered anatomy and pathology. *Radiology* 1983;148:461–464
6. Potter GD. The lateral projection in tomography of the petrous pyramid. *AJR* 1976;104:194–200
7. Schatz CJ, Vignaud J. The inclined lateral projection: a new view in temporal bone tomography. *Radiology* 1975;118:355–361
8. Manzione JV, Rumbaugh CL, Katzberg RW. Direct sagittal computed tomography of the temporal bone. *J Comput Assist Tomogr* 1985;9(2):417–419
9. Zonneveld FW. The technique of direct multiplanar high resolution CT of the temporal bone. *Neurosurg Rev* 1985;8(1):5–13
10. Treffer M, Haughton VM. Patient dose and image quality in computed tomography. *AJR* 1981;137:25–27
11. Newton TH, Potts DG. Dosimetry in computed tomography. In: Newton TH, Potts DG, eds. *Radiology of the skull and brain. Technical aspects of computed tomography*, vol 5. St. Louis: Mosby, 1981:4237
12. Gray H. *Anatomy of the human body*. Gos CM, ed. Philadelphia: Lea & Febiger, 1959