

An Epidural Cavernous Hemangioma of the Spine

Cavernous hemangiomas are uncommon vascular malformations of the CNS that may affect any part of the neuroaxis. Most of these lesions are intracranial; supratentorial sites are most common [1]. In the spine, lesions of the vertebral bodies are most common, intramedullary [2] and intradural extramedullary [3] lesions of the spinal axis are uncommon, and purely epidural lesions are rare [4, 5]. We report a case of an epidural cavernous hemangioma of the spine and present the MR findings.

Case Report

A 50-year-old man had had progressive low back pain radiating down his right leg in a typical sciatic distribution for 5–6 weeks. Neurologic examination showed a slight weakness of dorsal flexion of the right first toe with slight sensory impairment in both S1 and L5 dermatomes. A myelogram showed nearly complete blockage of water-soluble contrast material in the subarachnoid space at the L3–L4 level by a large, right-sided, dorsolateral, smooth, rounded 1- to 2-cm mass with a typical epidural configuration. Contrast-enhanced CT suggested a low-density mass producing a subtle posterolateral impression on the right side of the thecal sac at the L3–L4 level. MR showed a smooth, rounded, 1- to 2-cm, right-sided, parasagittal spinal mass located just above the L3–L4 disk space. The mass had a homogeneous, intermediate signal similar to that of CSF on the T1-weighted sagittal and axial (Fig. 1A) images. A sagittal T2-weighted image (Fig. 1C) showed a mildly heterogeneous high-signal-intensity mass, slightly less intense than CSF, surrounded by a low-density rim. An axial T1-weighted image (Fig. 1B) obtained after administration of contrast material showed peripheral enhancement of the mass.

At surgery, a firm, rubbery, ovoid, red-purple mass located between the dura and ligamentum flavum just cephalad to the L3–L4 intervertebral disk was excised en bloc along with a rim of normal-appearing dura. Pathologic examination confirmed an epidural mass $1.6 \times 1.0 \times 0.6$ cm that was firmly adherent to the right dural surface but loosely attached to the ligamentum flavum. A photomicrograph of the postoperative specimen (Fig. 1D) showed variably sized endothelium-lined sinusoids within a fibrous stroma consistent with a cavernous hemangioma [1]. A small amount of diffusely scattered hemosiderin was present within macrophages. No calcification was noted.

Discussion

Cavernous hemangiomas, also called cavernous angiomas, are congenital vascular malformations of unknown origin that frequently are considered to be hamartomas [1, 6, 7]. CNS cavernous hemangiomas may be solitary or multiple, may occur in conjunction with cavernous hemangiomas in other organ systems or in conjunction with capillary telangiectasis, and may appear as sporadic or familial cases [1]. These uncommon lesions may occur anywhere in the CNS. Of cavernous hemangiomas that involve the epidural space, lesions in the vertebral bodies with extension into the epidural space are much more common than are purely epidural lesions [4, 6]. Purely epidural spinal cavernous hemangiomas account for less than 4% of spinal epidural masses [4]. When they occur, they are most frequent in the thoracic or lumbar regions. Most of the reported purely spinal epidural cavernous hemangiomas were larger than the lesion in this case; many of them extended into neuroforamina, and a few of them extended into the parasagittal region. Recent articles have described the MR appearance of cavernous hemangioma in other locations, including the brain, orbit, liver, and spinal cord, but the MR appearance of a purely epidural cavernous hemangioma, to our knowledge, has not been reported.

Spinal epidural cavernous hemangiomas may be manifested as back pain, as a radiculopathy simulating a disk protrusion, as an insidious progressive paraparesis, or as acute paraplegia. Trauma may precipitate the patient's symptoms, often producing a radiculopathy that is confused with an acute disk herniation [4–6]. Thus, the presenting symptoms in our patients were typical but nonspecific.

In the present case, the spinal epidural cavernous hemangioma appeared as an epidural mass on a myelogram, as a subtle ill-defined mass on CT scans, and as a well-circumscribed mass on MR images. T1-weighted MR images showed a mass with intermediate signal intensity similar to that of CSF and peripheral enhancement. T2-weighted images showed a mass with mildly heterogeneous high signal intensity slightly less than that of CSF and a surrounding low-intensity rim. The cause of this low-intensity rim was not clear, as the resected specimen showed only a small amount of diffusely scattered hemosiderin and no calcification. Diagnostic considerations based on appearance and location included a spinal meningeal cyst or a metastatic lesion. Neuroma, neurofibroma, and meningioma were considered because of the location, but the MR appearance of the lesion made these unlikely. This case shows one MR appearance of a spinal

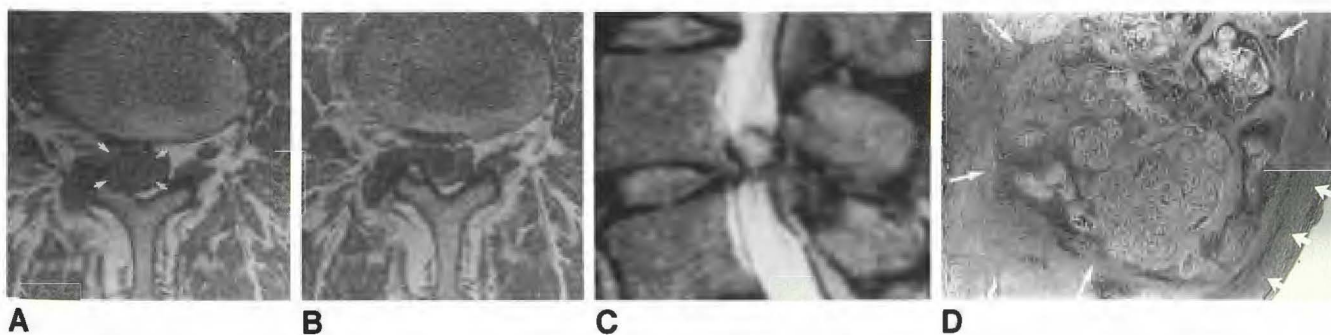


Fig. 1.—Epidural cavernous spinal hemangioma.

A–C, MR images show smooth, rounded, 1- to 2-cm, right-sided, epidural mass just above L3–L4 disk space. On axial T1-weighted image, 450/25 (A), lesion (arrows) has intermediate signal similar to that of CSF. Axial T1-weighted contrast-enhanced image, 450/25 (B), shows peripheral enhancement. On sagittal T2-weighted image, 2200/80 (C), lesion has mildly heterogeneous high signal intensity slightly less than that of CSF and is surrounded by a low-intensity rim of unknown cause.

D, Photomicrograph of postoperative specimen shows cavernous hemangioma (long arrows) firmly attached to external surface of dura (short arrows).

epidural cavernous hemangioma and reminds us that this entity should be considered in the differential diagnosis of a spinal epidural lesion that has an unusual radiologic appearance.

Henry K. Feider
David L. Yuille
St. Luke's Medical Center
Milwaukee, WI 53215

REFERENCES

1. Russell DS, Rubinstein LJ. *Pathology of the nervous system*, 4th ed. Baltimore: Williams & Wilkins, 1977:129-134
2. Cosgrove GR, Bertrand G, Fontaine S, Robitaille Y, Melanson D. Cavernous angiomas of the spinal cord. *J Neurosurg* 1988;68:31-36
3. Heimberger K, Schnaberth G, Koos W, Pendl G, Auff E. Spinal cavernous hemangiomas (intradural-extramedullary) underlying repeated subarachnoid haemorrhage. *J Neurol* 1982;226:289-293
4. Padovani R, Tognetti F, Proietti D, Pozzati E, Servadei F. Extrathecal cavernous hemangioma. *Surg Neurol* 1982;18:463-465
5. Richardson RR, Cerullo LJ. Spinal epidural cavernous hemangioma. *Surg Neurol* 1979;12:266-268
6. Guthkelch AN. Haemangiomas involving the spinal epidural space. *J Neurol Neurosurg Psychiatry* 1948;11:199-210
7. Simard JM, Garcia-Bengochea F, Ballinger WE, Mickle P, Quisling RG. Cavernous angioma: a review of 126 and 12 new clinical cases. *Neurosurgery* 1986;18:162-172