

MR Angiography of an Aberrant Internal Carotid Artery

Pulsatile tinnitus with or without a vascular-appearing retrotympanic mass has a number of possible causes [1]. Previous reports [1–4] have stressed the use of CT for evaluation when the masses are vascular appearing. In addition, Remley et al. [1] concluded that MR imaging has only a secondary role in the evaluation of pulsatile tinnitus because it cannot detect vascular variants such as an aberrant internal carotid artery and a high or dehiscent jugular bulb. We present a case of a vascular variant, an aberrant internal carotid artery, that was diagnosed on the basis of the findings on MR imaging with three-dimensional time-of-flight MR angiography.

Case Report

A 12-year-old girl had right-sided pulsatile tinnitus and a vascular-appearing retrotympanic mass. MR was performed with a 1.5-T Signa scanner (GE Medical Systems, Milwaukee, WI) and a quadrature drive head coil. Standard sagittal and axial spin-echo T1-weighted, (600/27/2 [TR/TE/number of excitations]) and dual-echo T2-weighted (2200/30, 90/1) pulse sequences were obtained by using a 20-cm field of view, slices 5 mm thick, and a 1-mm interslice gap. The standard pulse sequences were followed by an axial volume-spoiled gradient-recalled echo (SPGR) pulse sequence with TR = 45 msec, flip angle = 15°, and flow compensation. Sixty 1.5-mm partitions were obtained. The images were acquired in a 256 × 192 matrix and projected onto a 512 × 512 matrix by using a maximum image projection technique.

The standard T1- and T2-weighted images showed no abnormality in the skull base or temporal bone (Fig. 1A). The source images from the three-dimensional time-of-flight sequence showed abnormal bright signal consistent with flow in the right petrous temporal bone (Fig. 1B). The projected images showed the typical features of an aberrant right internal carotid artery (Figs. 1C and 1D).

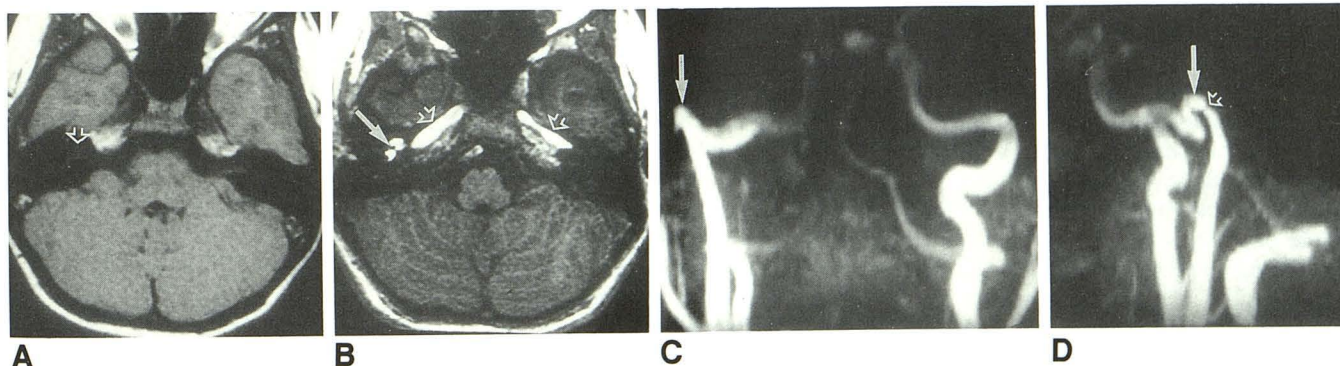


Fig. 1.—Aberrant internal carotid artery.

A, Axial T1-weighted (600/27/2) MR image at level of cochlea (arrow) shows normal signal void of petrous temporal bone. No specific abnormality was suspected.

B, Axial source image from MR angiographic study (45/4.7/15°), near same level as A, shows flow within temporal bone in an aberrant location (solid arrow). Multiple foci of high signal on this image and adjacent images were difficult to interpret as a single vessel, however. Horizontal petrous portion of internal carotid artery is symmetric bilaterally (open arrows).

C, Anteroposterior projection image from three-dimensional time-of-flight MR angiogram shows typical configuration of an aberrant right internal carotid artery. Note lateral and superior location of the genu (arrow).

D, Lateral projection image from three-dimensional time-of-flight MR angiogram shows more posterior and superior location of aberrant right internal carotid artery (solid arrow). Note typical narrowing of artery as it passes through inferior tympanic canaliculus (open arrow). Although tympanic annulus is not visualized, aberrant internal carotid artery can be diagnosed on basis of characteristic configuration of the artery.

Discussion

Aberrant internal carotid artery is a rare vascular anomaly that usually is manifested as pulsatile tinnitus with a retrotympanic vascular-appearing mass [5]. Differentiation of this lesion from a glomus tympanicum is critical in order to prevent the disastrous consequences of biopsy of this normal vascular variant [6].

Previous reports [1–4] have emphasized the importance of CT in the evaluation of pulsatile tinnitus and vascular-appearing retrotympanic masses. In the one study [1] in which use of MR in this patient group was evaluated, the authors conceded that, with a change in technology, MR might become better for diagnosis of these lesions. Our results suggest that MR angiography may acquire a greater role in evaluation of pulsatile tinnitus with or without vascular-appearing retrotympanic masses.

Wayne L. Davis
H. Ric Harnsberger
University of Utah
Salt Lake City, UT 84132

REFERENCES

1. Remley KB, Coit WE, Harnsberger HR, et al. Pulsatile tinnitus and the vascular tympanic membrane: CT, MR, and angiographic findings. *Radiology* 1990;174:383–389
2. Swartz JD, Bazarnic ML, Naidich TP, et al. Aberrant internal carotid artery lying within the middle ear: high resolution CT diagnosis and differential diagnosis. *Neuroradiology* 1985;27:322–326
3. Lo WWM, Solti-Bohman LG, McElveen JT. Aberrant carotid artery: radiologic diagnosis with emphasis on high-resolution computed tomography. *RadioGraphics* 1985;5:985–993
4. Damsma H, Mali WP, Zonneveld FW. CT diagnosis of an aberrant internal carotid artery in the middle ear. *J Comput Assist Tomogr* 1984;8:317–319
5. Sinnreich AL, Parisier SC, Cohen HL, Berreby M. Arterial malformations of the middle ear. *Otolaryngol Head Neck Surg* 1984;92:194–206
6. Anderson JM, Stevens C, Sundt TM, et al. Ectopic internal carotid artery seen initially as middle ear tumor. *JAMA* 1983;249:2228–2230

This work was supported by a grant from Mediq, MDTC.