

## Neurofibroma of the Aryepiglottic Fold

David M. Yousem<sup>1</sup> and J. Carl Oberholtzer<sup>2</sup>

Less than 25 cases of neurofibromas of the larynx associated with von Recklinghausen disease have been reported in the literature [1–10]. Most patients present with dyspnea, dysphagia, stridor, or hoarseness. We report a case of an asymptomatic 41-year-old man who had an incidentally discovered aryepiglottic fold neurofibroma. To our knowledge this is the first such case demonstrated by MR imaging.

### Case Report

A 41-year-old man with a history of neurofibromatosis since birth manifested by multiple cutaneous nodules and a low-grade optic chiasm glioma injured his neck while at work. Plain films of the neck, obtained because of persistent neck pain but no radiation or neurologic symptoms, demonstrated a mass inferior to the epiglottis and coursing posterolaterally on the right side (Fig. 1A). The patient had no symptoms of dyspnea, dysphagia, hoarseness, or change in voice quality over recent months. He smoked half a pack of cigarettes and drank one beer a day. His physical examination was remarkable for multiple café au lait spots and subcutaneous nodules. An indirect laryngoscopic examination demonstrated a pink submucosal mass involving the right aryepiglottic fold and lateral pharyngeal wall.

MR examination of the larynx in coronal, axial, and sagittal planes revealed a large mass associated with the right aryepiglottic folds (Fig. 1B). The mass was isointense with muscle on T1-weighted, 600/11/1 (TR/TE/excitations), scans and hyperintense on spin-density- and T2-weighted scans (Figs. 1C and 1D). The mass showed moderate enhancement with contrast administration (Figs. 1E and 1F). Additionally, a second 1.5-cm nodule was identified in the infrahyoid neck that persisted on a repeat examination several months later.

Because of the risk of obstruction of the airway, the patient was advised to have laser excision of the aryepiglottic fold mass. This was performed uneventfully, and pathologic examination revealed a neurofibroma. A biopsy of the right infrahyoid neck mass was not done, but it was presumed to be either a second peripheral neurofibroma (possibly involving the vagus nerve) or a persistent jugular chain lymph node. The patient was discharged without complications.

### Discussion

Laryngeal involvement with neurofibromatosis is rare. A review article by Chang Lo in 1977 [6] reported 20 cases of

laryngeal involvement with neurofibromatosis. The most common presenting symptom is dyspnea, followed by hoarseness, stridor, dysphagia, and voice change. Half of the cases manifest in childhood and half in young adulthood. Laryngeal neurofibromas are associated with diffuse neurofibromatosis in 50% of cases [8].

The most common sites involved in the larynx are the arytenoids and the aryepiglottic folds [5–7, 9]. Supraglottic involvement is the rule, although subglottic tumors involving the trachea have also been reported [6, 8]. True vocal cord involvement is less common than false vocal cord neurofibromas. The tumors arise from terminal nerve plexuses in the submucosal space of the supraglottic larynx. Because of the supraglottic location, it is believed that the neurofibromas arise more commonly from the superior laryngeal branch of the glossopharyngeal nerve [4, 5].

Pathologically, most lesions of the larynx in patients with von Recklinghausen disease are neurofibromas. As opposed to schwannomas, which also occur in patients with neurofibromatosis, neurofibromas possess collagen-producing fibroblasts as well as myelin-producing Schwann cells, and are not as well encapsulated as schwannomas [4–7]. Plexiform neurofibromas are not as common as distinct neurofibromas (and are nearly impossible to remove completely owing to their infiltrative qualities), while ganglioneurofibromas or ganglioneuromas are much rarer [6, 8]. Malignant degeneration into neurofibrosarcomas and malignant schwannomas has been reported in the larynx, usually in patients with von Recklinghausen disease [6, 10].

The MR findings in this case are typical of neural tumors elsewhere. The tumors are relatively well-defined; they are of intermediate signal intensity on T1-weighted scans and of intermediate to high signal intensity on T2-weighted scans, but they are bright on proton-density-weighted studies [11–14]. Some variability in intensity on T2-weighted scans in schwannomas has been attributed to the fraction of Antoni A and B tissue in the tumor (the Antoni A fibers are densely packed palisading spindle cells and are of lower intensity on T2-weighted images than the Antoni B tissue, which is seen as loosely packed cells in a mucoid, myxoid matrix) [4, 5, 9]. Neurofibromas usually have a looser stroma than schwann-

Received December 20, 1990; revision requested March 24, 1991; revision received April 5, 1991; accepted May 1, 1991.

<sup>1</sup> Department of Radiology, Hospital of the University of Pennsylvania, 3400 Spruce St., Philadelphia, PA 19104-4283. Address reprint requests to D. M. Yousem.

<sup>2</sup> Department of Pathology and Laboratory Medicine, Hospital of the University of Pennsylvania, Philadelphia, PA 19104-4283.

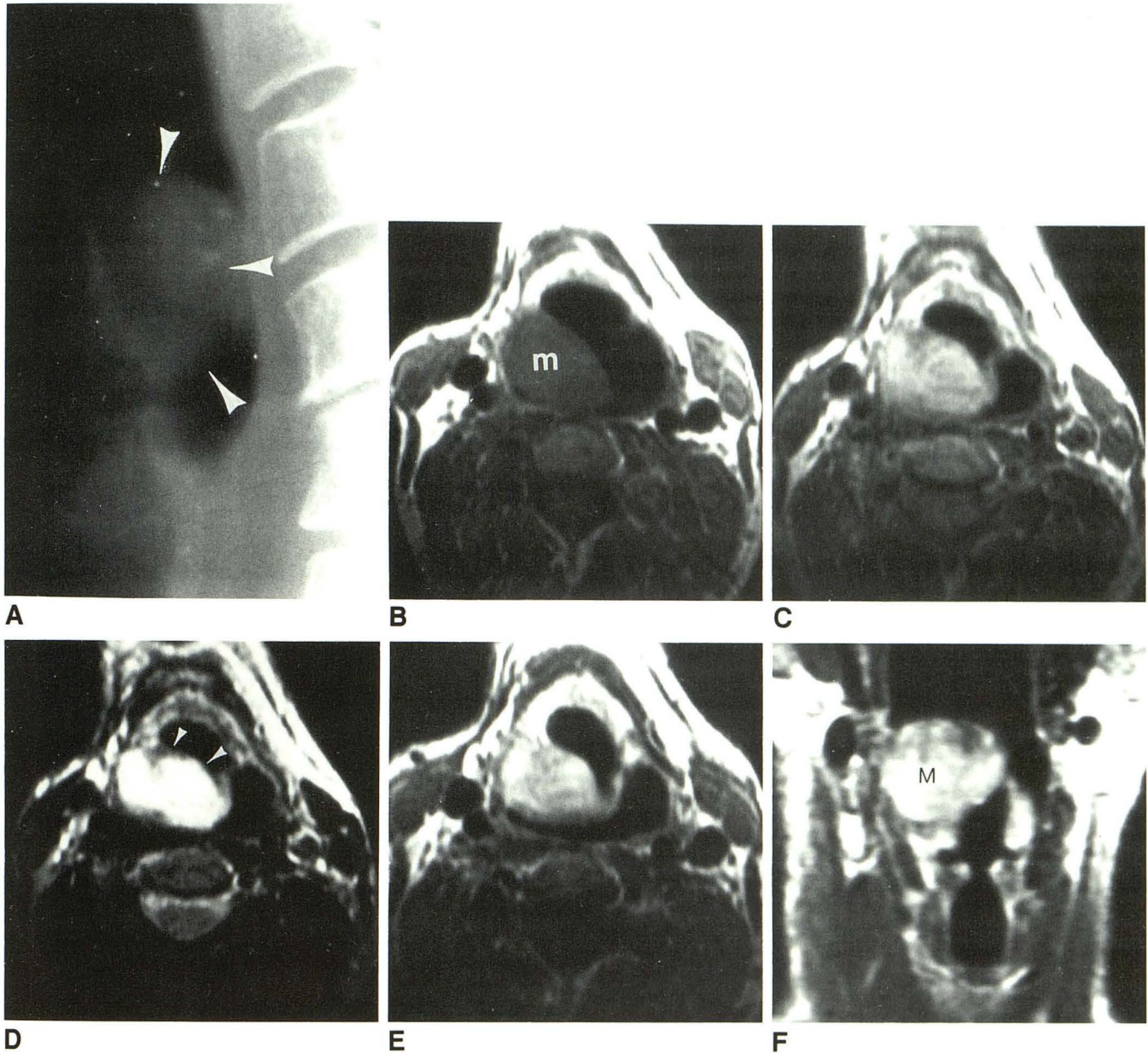


Fig. 1.—41-year-old man with aryepiglottic fold neurofibroma.

- A, Lateral cervical spine radiograph shows large soft-tissue mass (*arrowheads*) superimposed on air column in supraglottic larynx.  
 B, Axial T1-weighted (600/11) MR image shows right aryepiglottic fold mass (m) with dilatation of supraglottic airway.  
 C, Axial spin-density-weighted (2500/30) MR image shows signal intensity of mass to be between that of fat and muscle.  
 D, On T2-weighted (2500/80) MR image, mass shows homogeneously high signal intensity. Its submucosal location is suggested by the presence of low-intensity superficial tissue (*arrowheads*) along the aryepiglottic fold.  
 E, On contrast-enhanced T1-weighted (600/20) MR image, the mass enhances avidly and homogeneously.  
 F, Coronal postcontrast T1-weighted MR image shows preservation of pyriform sinus apex and laryngeal ventricle structures, with mass (M) terminating in a supraglottic location.

nomas. Schwannomas and neurofibromas tend to enhance avidly with gadopentetate dimeglumine. This factor and the T2 signal characteristics would argue against some of the other possibilities in the differential diagnosis of submucosal lesions in the larynx: fluid-filled laryngoceles and laryngeal cysts [8]. The integrity of the paralaryngeal fat would argue against internal laryngoceles. Hemangiomas and lymphosar-

comas may have similar MR appearances as the neurofibromas; however, flow voids in hemangiomas and associated lymphadenopathy in lymphomas could aid in the differential diagnosis. In the absence of flow voids, hemangiomas may simulate neurofibromas (enhancing brightly and being high in signal intensity) on T2-weighted images. A neurofibroma with a predominance of Antoni A fibers would not be as high in

signal intensity on T2-weighted scans as a hemangioma and often is less homogeneous in intensity. Amyloidosis demonstrates markedly decreased signal intensity on T2-weighted images. Minor salivary gland tumors may look similar to neurofibromas; however, they generally do not enhance as intensely and may not be as well defined.

An interesting feature of this case was the asymptomatic nature of the mass despite quite extensive narrowing of the patient's airway. This patient did not have a family history of neurofibromatosis; sporadic cases of the disease are reported in 50% of cases. The use of MR imaging in this case was helpful for delineation of the extent of the mass as well as for complete evaluation of the brain and neck.

#### REFERENCES

- Holinger PH, Cohen LL. Neurofibromatosis and involvement of the larynx: report of a case. *Laryngoscope* **1950**;60:193-196
- Figi FA, Stark DB. Neurofibroma of the larynx. Presentation of 5 cases. *Laryngoscope* **1953**;63:652-659
- Yurich EL, Beekhuis GJ. Multiple neurofibromatosis involving the larynx. *Laryngoscope* **1960**;70:46-54
- Jasper BW, Stern FA. Neurofibroma of the larynx occurring with von Recklinghausen disease: report of a case. *Arch Otolaryngol* **1973**;98:77-79
- Maisel RH, Ogura JH. Neurofibromatosis with laryngeal involvement. *Laryngoscope* **1974**;84:132-140
- Chang Lo M. Laryngeal involvement in von Recklinghausen's disease: a case report and review of the literature. *Laryngoscope* **1977**;87:435-442
- Supance JS, Queneue DJ, Crissman J. Endolaryngeal neurofibroma. *Otolaryngol Head Neck Surg* **1980**;88:74-78
- Sidman J, Wood RE, Poole M, Postma DS. Management of plexiform neurofibroma of the larynx. *Ann Otol Rhino Laryngol* **1987**;96:53-55
- Stanley RJ, Scheithauer BW, Weiland LH, Neel HB III. Neural and neuroendocrine tumors of the larynx. *Ann Otol Rhino Laryngol* **1987**;96:630-638
- Stines J, Rodde A, Carolus JM, Perrin C, Becker S. CT findings of laryngeal involvement in von Recklinghausen disease. *J Comput Assist Tomogr* **1987**;11:141-143
- Gentry LR, Jacoby CG, Turski PA, et al. Cerebellopontine angle-petromastoid mass lesions: comparative study of diagnosis with MR imaging and CT. *Radiology* **1987**;162:513-520
- Daniels DL, Pech P, Pojunas KW, et al. Trigeminal nerve: anatomic correlation with MR imaging. *Radiology* **1986**;159:577-583
- Davis PC, Hoffman JC, Ball TI, et al. Spinal abnormalities in pediatric patients: MR imaging findings compared with clinical, myelographic, and surgical findings. *Radiology* **1988**;166:679-685
- Scotti G, Scialfa G, Columbo N, Landoni L. MR imaging of intradural extramedullary tumors of the cervical spine. *J Comput Assist Tomogr* **1985**;9:1037-1041