

biochemist terms hemosiderin, which is defined operationally by its solubility and means of purification, given its yet imperfect structural and compositional definition. The stain reaction requires the presence of only two identical or similar metal ions in different oxidation states to generate the intense blue color. For example, colorless solutions of $\text{Fe}^{3+}(\text{ClO}_4)_3$ and $\text{K}_4\text{Fe}^{2+}(\text{CN})_6$ can be mixed to produce the bright blue color.

The ferritin stain uses an antibody specific for the well-characterized iron-protein complex that binds iron for storage and transport.

It is clear from our results [1] that the distribution of ferritin immunoreactivity and Perls positivity are different. Ferritin immunoreactivity has a wider distribution than Perls' positivity does. This difference in distribution cannot be explained by the differences in solubility as implied by Bizzi et al. Differences in distribution may represent differences in reaction rates for different forms of iron. Calibrating response curves for tissue sections by using polychromatic diffuse light to obtain quantitative measurements of iron concentration is complex and was well beyond the requirements of our study, as discussed elsewhere (Thulborn et al., poster presented at the annual meeting of the Society of Magnetic Resonance in Medicine, 1989). It was not intended to imply that ferritin does not react with the Perls stain but rather to show that the specific protein ferritin is present in chronic hemorrhage. None of the assumptions implied in the letter of Bizzi et al. were made or were necessary for this work.

Others [2] have suggested that a positive Perls stain should not be used to imply that ferritin only is present. The brain contains a sizable pool of iron that is not characterized biochemically and that likely reacts with this stain. Animal models of iron metabolism will be an important component of detailed biochemical analysis of all iron pools. I thank Bizzi et al. for their support for the conclusions of our paper, if not the semantics.

Keith R. Thulborn
Massachusetts General Hospital
MGH-NMR Center
Charlestown, MA 02129

REFERENCES

1. Thulborn KR, Sorenson AG, Kowall NW, et al. The role of ferritin and hemosiderin in the MR appearance of cerebral hemorrhage: a histopathologic biochemical study in rats. *AJNR* 1990;11:291-297, *AJR* 1990;154:1053-1059
2. Chen JC, Hardy PA, Clauberg M, et al. T2 values in the human brain: comparison with quantitative assays of iron and ferritin. *Radiology* 1989;173:521-526

Tuberous Sclerosis: CT and MR Findings

I read with interest the case report by Tien et al. [1] of a giant-cell astrocytoma in a 3-day-old neonate with tuberous sclerosis. It is important to consider tuberous sclerosis in neonates even when they have no family history of the syndrome.

My colleagues and I saw an otherwise healthy 6-week-old girl who had focal seizures that were difficult to control with medication. The infant had been delivered vaginally after 37 weeks gestation. The mother was a 26-year-old woman, gravida 2 para 1, who had no history of herpes. During the pregnancy, she had had an upper respiratory infection and a urinary tract infection that were treated with antibiotics. She had no family history of tuberous sclerosis or any other neurocutaneous disorder.

Physical examination showed a healthy-appearing 6-week-old girl with weight in the 75th percentile and head circumference in the 95th percentile. A capillary hemangioma on the upper right eyelid extended onto the bridge of the nose. No other abnormalities were noted. Specifically, no other skin lesions were identified (the results of an examination with ultraviolet light were normal.) The baby had repeated clinically evident seizures, and electroencephalography showed additional subclinical seizures. Plain CT (Fig. 1A) showed a subtle area of nonenhancing slightly increased attenuation in the white matter of

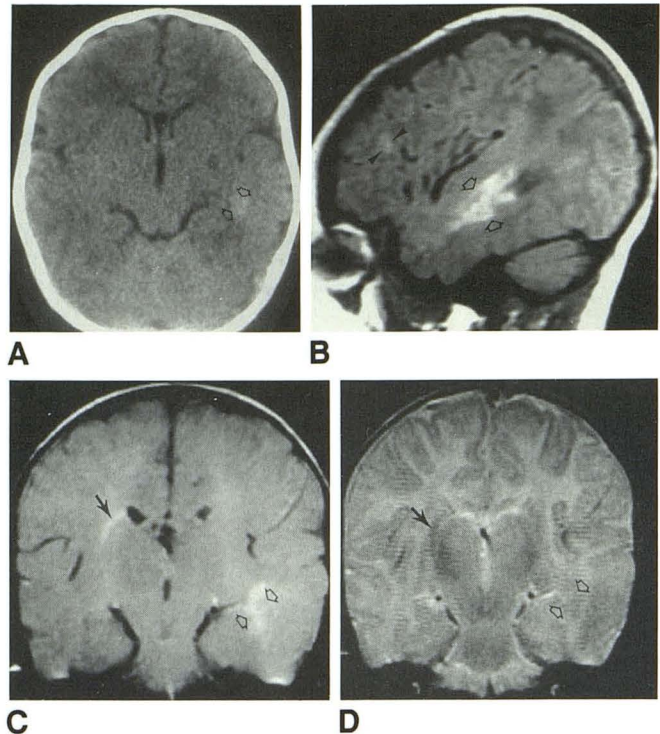


Fig. 1.—Presumed parenchymal (subcortical) hamartomas in a 6-week-old with seizures and cardiac and retinal stigmata of tuberous sclerosis.

A, CT scan without contrast material shows subtle area of increased attenuation (arrows) in white matter of left temporal lobe without mass effect or enhancement. No periventricular lesions were detected.

B, Parasagittal noncontrast T1-weighted MR image, 600/20/2, shows lesion (arrows) in left temporal lobe and a faint second lesion (arrowheads) in left frontal lobe. Several other smaller (2 mm) lesions were seen throughout supratentorial white matter bilaterally (not shown).

C, Coronal proton-density MR image, 3000/30/1, shows lesion (open arrows) in left temporal lobe and a periventricular lesion (solid arrow) on right.

D, Coronal T2-weighted MR image, 3000/90/1, shows that lesions seen in C are essentially isointense with gray matter.

the left temporal lobe. MR confirmed this lesion and showed additional smaller lesions throughout the supratentorial white matter (Figs. 1B-1D). No periventricular (particularly in the region of the foramina of Monro) abnormalities were seen. Cardiac sonography showed at least two masses, which were thought to be most consistent with rhabdomyomas. Ophthalmologic examination showed a retinal tuber on the right side (and possibly an additional lesion of the left). The findings on renal sonography were normal. The clinical diagnosis was tuberous sclerosis. The seizures eventually were controlled with phenobarbital and primidone, and the patient was discharged with plans for follow-up in appropriate clinics and for family genetic counseling.

In the case reported by Tien et al. [1], appropriate management necessitated removal of the large mass in the region of the foramen of Monro. In our case, the lesions in the white matter did not warrant craniotomy for therapeutic or diagnostic purposes. The discovery of cerebral parenchymal abnormalities possibly related to tuberous sclerosis should prompt a search for additional stigmata of this disorder (skin, renal, cardiac, retinal) in an attempt to make a diagnosis on the basis of clinical findings and thus avoid a brain biopsy.

The increased signal of the subcortical lesions (heterotopic groups of neurons and glial cells [2]) that we saw on T1-weighted and proton-density MR images has been described previously [3] and probably is due to a combination of the relatively long T1 of neonatal brain and the mineralization of the lesions [3, 4]. The mineralization probably

also explains the subtle increased attenuation on the CT scan (Fig. 1A) of our patient's largest lesion.

In a neonate with seizures, multiple areas of abnormal white matter that (1) have increased signal on T1-weighted and proton-density MR images and appear essentially isointense with white matter on more T2-weighted MR images, (2) show no mass effect or contrast enhancement, and (3) have slight increased attenuation on plain CT should suggest mineralized parenchymal hamartomas and prompt an evaluation of other organ systems before a craniotomy or brain biopsy is considered.

Douglas J. Quint
University of Michigan Hospitals
Ann Arbor, MI 48109

REFERENCES

1. Tien RD, Hesselink JR, Duberg A. Rare subependymal giant-cell astrocytoma in a neonate with tuberous sclerosis (letter). *AJNR* 1990;11:1251-1252
2. Barkovich AJ. Phakomatoses. In: Barkovich AJ, ed. *Pediatric neuroimaging*. New York: Raven, 1990:135-139
3. Christophe C, Bartholome J, Blum D, et al. Neonatal tuberous sclerosis: US, CT and MR diagnosis of brain and cardiac lesions. *Pediatr Radiol* 1989;19:446-448
4. Dell LA, Brown MS, Orrison WW, Eckel CG, Matwyoff NA. Physiologic intracranial calcification with hyperintensity on MR imaging: case report and experimental model. *AJNR* 1988;9:1145-1148

Reply

Dr. Quint has described a most interesting case, and I fully agree that a careful evaluation of other organ systems is justified in a neonate with brain lesions in order to rule out tuberous sclerosis even in the absence of a family history of the syndrome. Cardiac rhabdomyomas are the most commonly associated lesions [1]. The subcortical lesions usually are hypointense on T1-weighted MR images and hyperintense on T2-weighted images, reflecting the well-known demyelinated foci [2, 3] that accompany the clusters of atypical astrocytes. Altman et al. [4] have described two neonates who had lesions with short T1 and T2 relaxation characteristics (high signal on T1-weighted images, low signal on T2-weighted images). Increased attenuation was seen on contrast-enhanced CT. Lesions with this appearance can be confused with hemorrhagic infarct or an area of calcification, neither of which was found on the pathologic examinations by Altman et al. They postulated that the signal intensity on T1-weighted images might have been high because the parenchymal lesions were being compared with the immature brain, which contains a higher concentration of water. Thus, the hamartoma appeared brighter. The low signal intensity on T2-weighted images possibly is related to the large, bizarre nuclei and scanty cytoplasm seen microscopically. However, the increased T1 signal of the lesions in Dr. Quint's patient probably was due to mineralization of the lesions.

The hamartomas seen in tuberous sclerosis can have a variety of MR signal intensities because of their cytostructures. Prompt recognition and scrutiny of other organ systems can help in establishing an early diagnosis.

Robert D. Tien
University of California, San Diego Medical Center
San Diego, CA 92103

REFERENCES

1. Painter MJ, Pang D, Ahdab-Barmada M, et al. Connatal brain tumors in patient with tuberous sclerosis. *Neurosurgery* 1984;14:570-573
2. Garrick R, Gomez MR, Houser OW. Demyelination of the brain in tuberous sclerosis: computed tomography evidence. *Mayo Clin Proc* 1979;54:685-689
3. Inoue Y, Nakajima S, Fukuda T, et al. Magnetic resonance images of tuberous sclerosis. *Neuroradiology* 1988;30:379-384

4. Altman NR, Purser RK, Donovan-Post MJ. Tuberous sclerosis: characteristics at CT and MR imaging. *Radiology* 1988;167:527-532

Commentary

I read with interest the letters by Tien et al. [1] and by Dr. Quint. I applaud Dr. Quint's comments that the recognition of cerebral parenchymal abnormalities as possibly being related to tuberous sclerosis should prompt a search for stigmata of this disorder in other organs before a brain biopsy is performed. Sometimes the results of a physical examination or an imaging study of the parents can be of considerable help in making this diagnosis. Many parents with subclinical tuberous sclerosis have hypopigmented macules, unguinal or gingival fibromas, calcified subependymal nodules, or renal lesions [2].

The increased signal of calcified lesions on relatively T1-weighted MR images, reported by both Tien et al. and Quint is an interesting finding. My colleagues and I also have imaged a number of patients with tuberous sclerosis in whom calcified hemispheric and subependymal lesions have shown a short T1 relaxation time. The phenomenon of T1 shortening by calcification has been studied [3, 4]. It appears that calcium crystals can cause T1 and T2 shortening as well as diminished proton density. The degree of shortening of the relaxation times appears to be related to the surface area of the crystals [4]. Therefore, depending on the characteristic of the crystals of the calcium salt, T1 shortening may or may not be apparent on MR studies. In fact, T1 shortening is not apparent in most tubers.

Although I agree that it is important to be able to recognize tuberous sclerosis on imaging studies in neonates, I would expand and slightly amend Dr. Quint's final paragraph. First, it is important to realize that anomalies of neuronal migration occasionally can be calcified and show diminished T1 and T2 relaxation times. These lesions also show no mass effect or contrast enhancement and have increased attenuation on CT scans. Anomalies of neuronal migration can be considered hamartomas, but they should not be misinterpreted as representing tuberous sclerosis because the genetic counseling is quite different for the two disorders. Brain calcification also can be seen in congenital infections, congenital tumors, and as a sequela of asphyxia [5]. Second, it is unusual for cortical hamartomas of tuberous sclerosis to be calcified at birth. In fact, the proportion of these lesions that is calcified increases along with the age of the patient [2]. A more common appearance of cortical tubers in infants is slightly prolonged T1 and T2 relaxation times as compared with normal white matter, with mild expansion of the overlying gyrus. The subependymal region should be scrutinized carefully for hamartomas, which will appear iso- to slightly hyperintense compared with white matter on short TR sequences and iso- to slightly hypointense compared with white matter on long TR sequences. Any findings that suggest tuberous sclerosis should prompt an evaluation of other organ systems, as well as examination of close relatives.

Anthony J. Barkovich
University of California, San Francisco
San Francisco, CA 94143-0628

REFERENCES

1. Tien RD, Hesselink JR, Duberg A. Rare subependymal giant-cell astrocytoma in a neonate with tuberous sclerosis (letter). *AJNR* 1990;11:1251-1252
2. Gomez M. *Tuberous sclerosis*, 2nd ed. New York: Raven, 1988:269
3. Dell LA, Brown MS, Orrison WW, Eckel CG, Matwyoff N. Physiologic intracranial calcification with hyperintensity on MR imaging: case report and experimental model *AJNR* 1988;9:1145-1148
4. Henkelman M, Watts J, Kucharczyk W. High signal intensity in MR images of calcified brain tissue. *Radiology* 1991;179:199-206
5. Kendall B, Cavanagh N. Intracranial calcification in pediatric computed tomography. *Neuroradiology* 1986;28:324-330