

# Flow-Sensitive MR Imaging of Ventriculoperitoneal Shunts: In Vitro Findings, Clinical Applications, and Pitfalls

Mauricio Castillo<sup>1,2</sup>  
 Patricia A. Hudgins  
 John A. Malko  
 Bobbie K. Burrow  
 James C. Hoffman, Jr.

To determine ventriculoperitoneal shunt patency during routine MR imaging of the head, 23 patients were studied with T1-weighted fast-field-echo scans. Without knowledge of the results of previous MR/CT studies or of the patients' clinical history, we reviewed the fast-field-echo studies and divided them according to those judged to have shunt flow (18) and those judged not to have flow (five). Fast-field-echo sequences showed high signal intensity, consistent with CSF flow and shunt patency in 17 medium-pressure systems and one high-pressure system. No signal was seen in five patients with high-pressure valve shunts. Combined clinical evaluation and MR/CT studies showed that three patients had probable shunt malfunction. One patient had true shunt malfunction; and although malfunction was thought to be present in two symptomatic patients, surgical revision showed the shunts to be patent. The possibility of temporary shunt obstruction is postulated to explain the clinical and MR findings in those two cases. The remaining two cases (9% of the patients) had no clinical evidence of shunt malfunction, and the MR findings probably reflected periodic CSF flow. One patient had an intracranial segment that was not connected and showed no flow on MR. No false-positive results (apparent flow in a nonfunctioning shunt) occurred. Using a standard medium-pressure shunt system, we constructed and imaged a phantom, which confirmed our clinical observations.

T1-weighted fast-field-echo sequences may be useful in assessing patency of medium-pressure CSF shunt systems.

*AJNR* 12:667-671, July/August 1991

Flow rates as low as 0.25 ml/min have been seen as flow-void phenomenon within CSF shunt phantoms on spin-echo T2-weighted MR images [1]. In that study, flow void in a functioning shunt was seen in one patient while absence of flow void was present in a patient with shunt malfunction. Using a specially designed surface coil, Martin et al. [2] described the use of a phase method to quantitate the rate of CSF flow in shunts.

It is well known that partial flip angle imaging is extremely sensitive to flow, especially when large flip angles are used [3]. This technique has not yet been used to assess ventriculoperitoneal shunt patency. In this article we describe our experience with fast-field-echo (FFE) T1-weighted sequences in the evaluation of CSF shunt patency in 23 patients.

## Materials and Methods

Our study population consisted of 23 patients (14 males and nine females) in whom ventriculoperitoneal shunts had been placed 3 months to 10 years earlier for hydrocephalus resulting from intracranial neoplasia (17), Chiari malformation (three), neonatal meningitis (two), and idiopathic causes (one). All shunt systems (PS Medical, Goleta, CA) consisted of a ventricular catheter (inner diameter = 1.2 mm), a reservoir, a Silastic interconnector, a valve (with no antisiphon device), and a distal catheter (inner diameter = 1.2 mm) draining into the peritoneal cavity. Eighteen patients had medium-pressure valves (60-130 mm H<sub>2</sub>O) and five

Received May 16, 1990; revision requested August 15, 1990; revision received November 20, 1990; accepted November 29, 1990.

<sup>1</sup> All authors: Department of Radiology, Division of Neuroradiology, Emory University School of Medicine, Atlanta, GA 30322.

<sup>2</sup> Present address: Department of Radiology, LBJ General Hospital, 5656 Kelley St., Houston, TX 77026. Address reprint requests to M. Castillo.

0195-6108/91/1204-0667

© American Society of Neuroradiology

had high-pressure valves (120–200 mm H<sub>2</sub>O). One patient had two intracranial segments, one of which was disconnected. Without knowledge of whether shunt malfunction was a clinical consideration, we acquired FFE T1-weighted images using a single-slice technique and a 1.5-T scanner (Philips, Shelton, CT) through the proximal (intracranial) and distal (subcutaneous) components of the shunt system. An oblique coronal view, perpendicular to the long axis of the catheter, was obtained (Fig. 1). This single slice was located through the parenchymal course of the shunt and as far as possible from the valve. A single axial slice was obtained in the mid neck (Fig. 2). Imaging parameters included a 90° flip angle, 130/11/2 (TR/TE/excitations), 100% acquisition, 5-mm thickness, 220-mm field of view, and a 256 × 512 matrix. A standard transmitter/receiver head coil was employed. Time of acquisition was 70 sec/slice.

To determine the sensitivity of our FFE sequences in identifying CSF flow in the shunt, a phantom was constructed by using a medium-pressure valve (same model as used in our patients). The intracranial limb (length = 12 cm) of the system was attached via an IV tube to an IV volumetric pediatric infusion pump (Micro Flo Gard 8500, Baxter Health Care Corp., Deerfield, IL), which provided a pumping or pulsatile infusion. The shunt limbs (length = 12 cm) were then attached to a plastic board and submerged in a container filled with lukewarm tap water. A second plastic IV line was attached to the distal shunt and its tip placed at ground level inside a 10-ml graduated cylinder. Infusion rates as measured by lukewarm normal saline solution were adjusted to 1, 0.5, and 0.25 ml/min. The phantom was placed in the magnet and imaged with the same technique as used in our patients.

The patients' studies were then compared with the previous MR or CT (performed within 3 months) with special attention to the ventricular size. The current clinical histories were reviewed for symptoms suggesting shunt malfunction.

The FFE studies were divided into two groups: those in which high signal intensity was present within the proximal and distal shunts, and those in which no signal was seen. This information was correlated with that obtained from the clinical records and previous imaging studies.

## Results

Twenty patients had no clinical or MR evidence of shunt malfunction. Two patients who had FFE studies suggesting shunt malfunction were clinically symptomatic but showed no evidence of shunt malfunction at surgery. One patient had clinical, radiographic, and surgically proved shunt obstruction.

In 18 instances, high signal intensity was seen in both proximal and distal limbs of the system, indicating active CSF flow (Fig. 3). The bright signal was caused by the inflow of unsaturated spins into the image plane. The signal intensity seen in the proximal and distal segments was similar. Although the shunts were of small diameter (1.2 mm), flow-related enhancement (or lack of it) was clearly seen. Positioning the MR slice perpendicular to the long axis of the shunt catheters minimized partial volume averaging, thus contributing to the visualization of flow within the shunts. Seventeen systems had medium-pressure valves and one had a high-pressure valve. In five cases there was no signal in the lumen of both catheter limbs. Four of these systems had high-pressure valves and one had a medium-pressure valve. Two patients showed no signal within their shunts, but because they were asymptomatic and no hydrocephalus was present, they were treated conservatively. A 2-month follow-up showed no signs of increased intracranial pressure. Two patients had persistent headaches and nausea, and even though serial imaging studies showed no change in the ventricular size, no flow-related enhancement was found (Fig. 4). Owing to persistent symptoms, these two patients underwent surgical revision and the shunts were found to be patent. However, after surgery, these two patients improved clinically. This observation raises the possibility of an early, self-limiting, temporary shunt obstruction at the time the FFE study was performed. In one patient who had a working shunt and a disconnected intracranial shunt limb, the former showed flow-related enhancement and the latter did not (Fig. 5). In a patient with headaches, nausea, vomiting, and radiographic evidence of dilated ventricles, MR showed no flow within the shunt limbs (Fig. 6).

By using our phantom, we could observe bright signal intensity within the shunt at the three rates of flow employed (Figs. 7A and 7B). No signal was detected inside the phantom when no flow was present (Fig. 7C).

## Discussion

Obstruction or infection will occur in 25–60% of patients who harbor a CSF shunt [4]. Although several methods to

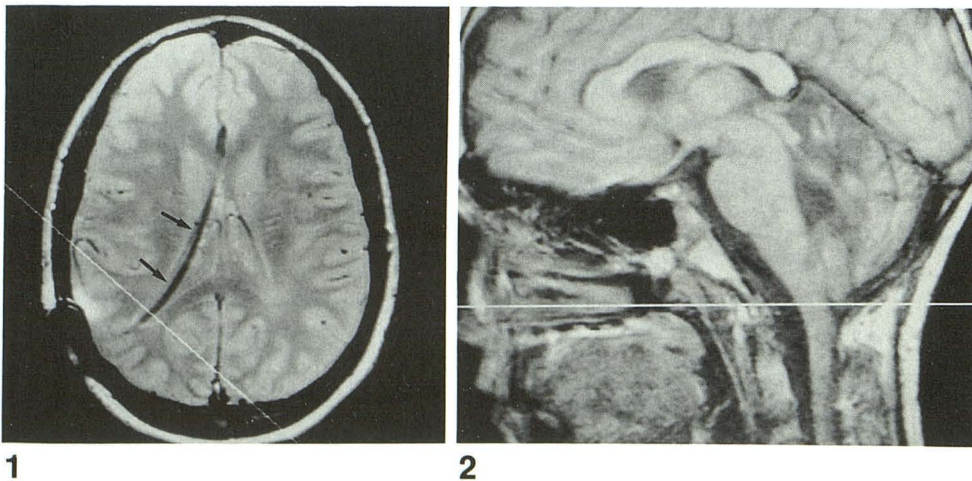


Fig. 1.—Axial proton density image at level of lateral ventricles and proximal shunt segment (arrows) shows position of oblique coronal view used to study intracranial shunt flow.

Fig. 2.—Sagittal midline T1-weighted image shows position of axial slice in the neck used to study flow in distal segment of shunt system.

Fig. 3.—A, Oblique coronal T1-weighted flow-sensitive image (130/11/2, with 90° flip angle) through intraparenchymal portion of a shunt (medium-pressure valve system). Note bright signal intensity within shunt (*arrow*), indicating active CSF flow.

B, Axial image (130/11/2, with 90° flip angle) of neck of same patient as in A shows bright signal intensity (*arrow*).

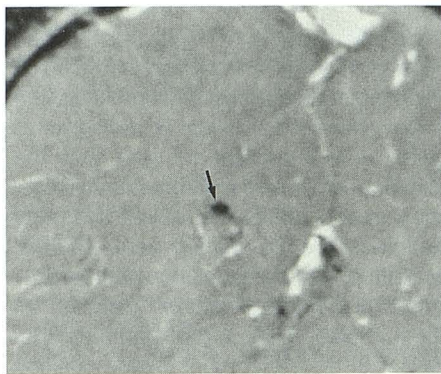
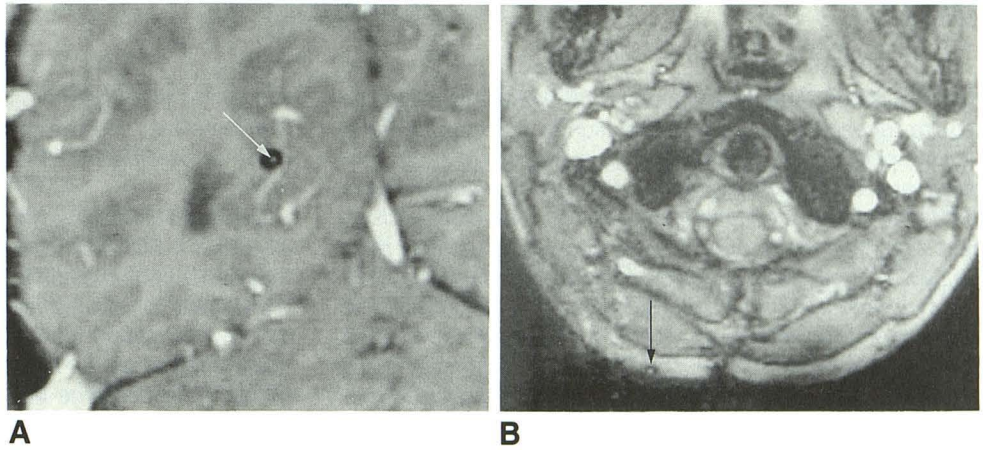


Fig. 4.—Oblique coronal image (130/11/2, with 90° flip angle) through intracranial segment (*arrow*) of a high-pressure shunt system in a patient with clinical findings suggesting shunt malfunction. Note absence of signal inside shunt, indicating active flow at the time this image was obtained. At surgery the shunt was patent. This false-positive case illustrates why MR imaging of high-pressure shunts is not reliable.

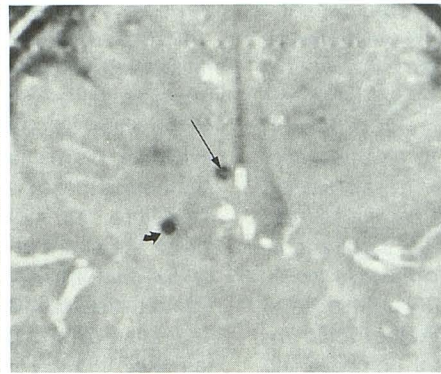


Fig. 5.—Oblique coronal section (130/11/2, with 90° flip angle) shows flow-related enhancement in functioning shunt limb (*long straight arrow*) of a patent shunt system, but no flow in shunt limb (*short curved arrow*), which is no longer connected.

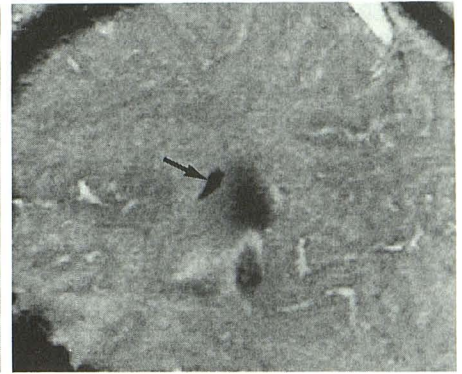
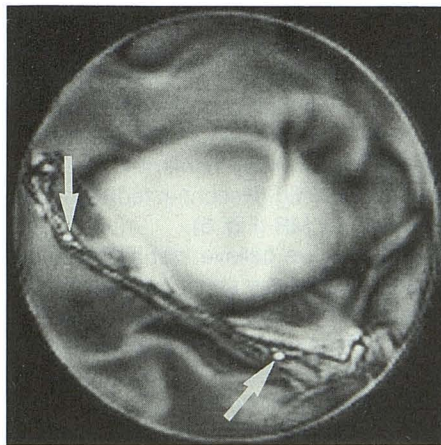
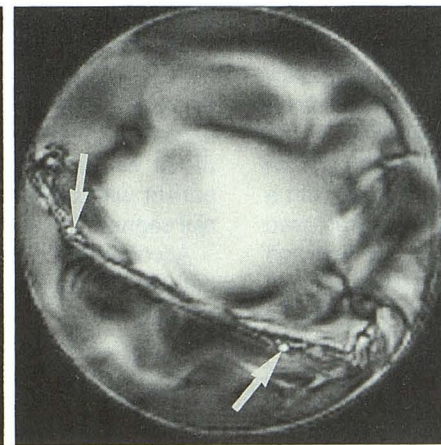


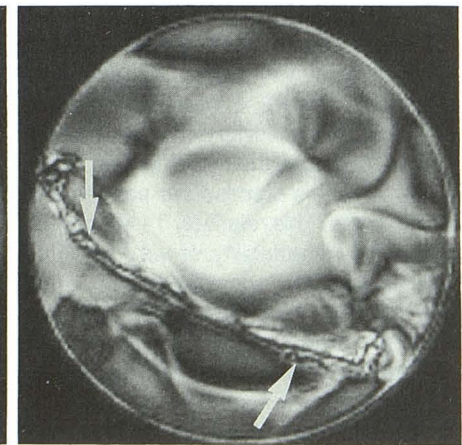
Fig. 6.—Oblique coronal image (130/11/2, with 90° flip angle) through intracranial segment of an obstructed (surgically confirmed) shunt. Note absence of flow-related enhancement in the shunt (*arrow*).



A



B



C

Fig. 7.—A, Axial image (130/11/2, with 90° flip angle) through shunt phantom at 0.5 ml/min shows flow-related enhancement (*arrows*) inside both shunt limbs.

B, Axial image (130/11/2, with 90° flip angle) through shunt phantom at 0.25 ml/min again shows flow-related enhancement in both shunt limbs (*arrows*).

C, Axial image (130/11/2, with 90° flip angle) through shunt phantom at 0 ml/min. Note absence of signal (indicating no active flow) in both shunt segments (*arrows*).

evaluate shunt patency exist, most of these are invasive and require repeated exposure to radiation in the form of either radiographic film or radionuclide administration [5–7]. Sonography and thermography represent noninvasive techniques that have not gained popularity [8–10]. Therefore, clinical assessment of shunt patency, even though not entirely reliable, remains the primary method to confirm malfunction [11].

In two series, MR was successfully employed to determine patency of CSF shunts [1, 2]. The first of these studies showed that in vitro spin-echo T2-weighted images could detect flow in a shunt phantom (seen as flow-void phenomenon) as low as 0.25 ml/min. Since that flow rate is roughly equal to the normal production of CSF in an adult (0.35 ml/min or 500 ml/day), it was suggested that flow void should be present within normally functioning shunts. The findings were supported by the examination of two patients, one with a working shunt in whom flow void was present, and a second with a proved malfunction in which no flow-void phenomenon was seen. The pressure valve settings in those patients or in the phantom were not specified. Martin et al. [2] used MR phase imaging to directly quantitate the amount of flow in CSF shunts. These researchers were able to clearly detect rates ranging from 4 to 19 ml/hr by using a flow-sensitizing sequence. Although promising, their method cannot be routinely used as it requires a specially designed surface coil. Clearly, our technique is not quantitative. In the previously mentioned study, flow rates as low as 0.06 ml/min were detected. Since we did not attempt to reproduce that extremely low rate in our phantom, we cannot compare the sensitivity of our method to theirs, but we believe that even though phase imaging is probably more sensitive, ours is a more practical approach. Different, but related observations were made by Jack and Kelly [12], who documented the presence of flow-void phenomenon within the third ventricles of patients who had undergone successful stereotaxic third ventriculostomies. In that series, one patient did not improve postoperatively and showed no flow void in the third ventricle. Their findings were confirmed by radionuclide ventriculography in all cases.

It is well known that entry-slice phenomenon is one of the main reasons why partial flip angle imaging is extremely sensitive to flow [3], a situation that our method takes advantage of. Flow sensitivity depends on the flip angle chosen: the greater the angle, the more flow sensitive it becomes [3]. On the basis of this premise our studies were performed with a 90° flip angle. This relatively T1-weighted sequence was used to improve detectability of very small amounts of flow and also avoided the possibility of confusing the bright signal intensity from nonflowing CSF within shunts that could be expected using only T2-weighted parameters. To maintain the direction of CSF flow perpendicular to the imaging plane, an oblique coronal view was obtained through the intracranial portion of the shunt and an axial view was obtained in the neck. We chose to examine the section of the shunt system that was in the neck since the head coil already in place provided enough sensitivity in that area. In our initial studies we discovered that the intraventricular segment of the shunt moves with systole and diastole and, therefore, appears

blurred on the images. Thereafter, we imaged the portion of the shunt that courses through the brain parenchyma as far away as possible from the artifact caused by the metal in the valve.

During FFE imaging, magnetic susceptibility artifacts usually occur at fluid/solid and fluid/gas interfaces [3]. It is known that longer echo times (TE) increase these artifacts; therefore, we elected to use the lowest TE obtainable in our unit, 11 msec. A repetition time (TR) of 130 msec gave good flow-related enhancement and enough signal to visualize the surrounding tissues. The images were obtained with a field of view large enough to include the entire head (or the neck), allowing comparison of the intensity of flow within the shunt with that present in the visualized vessels. In our experience, even though flow within the shunt is considerably less than that within vessels, the signal intensities inside all these structures was similar.

As stated earlier, the shunt systems in 17 cases contained medium-pressure valves and that in one patient had a high-pressure valve. Two patients exhibited no flow in either limb of the shunt systems, but neither had clinical or radiographic evidence of malfunction. It is important to note that the systems in these two patients employed high-pressure valves. Therefore, our findings probably reflect the lack of CSF flow inside the shunt at the exact time the images were obtained rather than true shunt malfunction. It is well known that flow through shunts that do not employ antisiphon devices will vary according to patient position [13]. A high-pressure system may then be closed with the patient in a supine position while it may open when the patient is erect. This observation may explain the lack of shunt flow (absence of flow-related enhancement) in our two asymptomatic patients. In two cases no flow-related enhancement was present in either shunt limb (Fig. 4). Although no significant ventricular dilation was present by MR, these patients were clinically symptomatic and surgical revision was undertaken. At surgery, these shunts were found to be functioning adequately. We postulate that at the time of the study these shunts might have been obstructed. Although uncommonly encountered, temporary shunt obstruction is a recognized entity by neurosurgeons (Hudgins R., personal communication). In one case of frank hydrocephalus, clinically and by imaging, no flow-related enhancement was documented inside the shunt catheters (Fig. 6). At surgery, shunt malfunction was confirmed. Also, a patient who harbored a nonworking (disconnected) intracranial segment showed no flow by MR (Fig. 5).

According to our experience, we believe that if no flow is detected in the extracranial limb of the shunt, performing an image through the intracranial segment can be bypassed. Therefore, one should begin by examining the cervical shunt segment and if patent, the MR evaluation of shunt flow can be terminated. In those cases in which evaluation of the cervical limb is indeterminate, an image through the intracranial segment should be done.

Bright signal intensity inside both shunt limbs of the phantom was identified with three different flow rates (1, 0.5, and 0.25 ml/min) (Figs. 7A and 7B). No signal was seen within the shunt when no flow was occurring (Fig. 7C). A potential

limitation of our phantom is the crude fashion in which it simulates the complex dynamics of CSF flow in actual shunt systems. Despite that limitation, we believe that our in vitro experiment confirmed our clinical findings.

In summary, FFE T1-weighted sequences may offer a practical and noninvasive method of determining patency of medium-pressure shunt systems in patients undergoing routine MR studies of the head. At this time we cannot recommend the use of this technique in patients who have received a high-pressure shunt system. Our future and potential areas of research with the described technique include (1) the early evaluation of patients with clinical symptoms of shunt malfunction in whom the ventricles have not yet enlarged, (2) symptomatic patients in whom the ventricles are stiff and noncompliant and retain their size even in the face of shunt malfunction, (3) patients with the rare but important "slit-ventricle syndrome" (chronic CSF overdrainage) [14], and (4) symptomatic patients with a CSF shunt in place in whom changes in ventricular size cannot be evaluated adequately owing to the absence of previous studies.

#### REFERENCES

1. Savades SJ, Savader BL, Murtagh FR, et al. MR evaluation of flow in a ventricular shunt phantom with in vivo correlation. *J Comput Assist Tomogr* **1988**;12:765-769
2. Martin AJ, Drake JM, Lemaire C, Henkelman RM. Cerebrospinal fluid shunts: flow measurements with MR imaging. *Radiology* **1989**;173:243-247
3. Enzmann DR, DeLaPaz RL, Rubin JB. *Magnetic resonance of the spine*. St. Louis: Mosby, **1990**:34-62
4. Noetzel MJ, Baker RP. Shunt fluid examination: risks and benefits in the evaluation of shunt malformation and infection. *J Neurosurg* **1984**;61:328-332
5. Savoiaro M, Solero CL, Paserini A, Migliavacca F. Determination of cerebrospinal fluid shunt function with water-soluble contrast medium. *J Neurosurg* **1978**;49:398-407
6. Brisman R, Schneider S, Carter S. Subarachnoid infusion and shunt function. Technical note. *J Neurosurg* **1973**;38:379-381
7. Harbert J, Haddad D, McCullough D. Quantitation of cerebrospinal fluid shunt flow. *Radiology* **1974**;112:379-387
8. Fletter MA, Bucheit WA, Murtagh F, et al. Ultrasound determination of cerebrospinal fluid shunt patency. Technical note. *Neurosurgery* **1975**;42:728-730
9. Widder DJ, Davis KR, Taveras JM. Assessment of ventricular shunt patency by sonography: a new noninvasive test. *AJNR* **1986**;7:439-442
10. De Laender F, Monteyne R, de Schryver L, et al. L'utilisation de la telethermographie chez les malades porteurs d'une derivation de liquide cephalo-rachidien selon la technique de Holter. *Neurochirurgie* **1976**;22:693-700
11. Osaka K, Yamasaki S, Hirayama A, et al. Correlation of the response of the flushing device to compression with the clinical picture in the evaluation of the functional status of the shunting system. *Childs Brain* **1977**;3:25-30
12. Jack CR, Kelly PJ. Stereotactic third ventriculostomy: assessment of patency with MR imaging. *AJNR* **1989**;10:515-522
13. Fox JL, Portnoy HD, Shulte RR. Cerebrospinal fluid shunts: an experimental evaluation of flow rates and pressure values in the anti-siphon valve. *Surg Neurol* **1973**;1:299-302
14. Hyde-Rowan MD, ReKate HL, Nulsen FE. Re-expansion of previously collapsed ventricles: the slit ventricle syndrome. *J Neurosurg* **1982**;56:536-539

The reader's attention is directed to the commentary on this article, which appears on pages 673-674.