

Reduced Hypothalamic Blood Flow After Radiation Treatment of Nasopharyngeal Cancer: SPECT Studies in 34 Patients

Poon-Ung Chieng^{1,2}
 Tien-Shang Huang^{1,3}
 Ching-Chung Chang³
 Pau-Nyen Chong²
 Robert D. Tien⁴
 Cheng-Tau Su²

To determine the effect of cranial irradiation on hypothalamic blood flow, we performed 44 regional cerebral blood flow studies with ^{99m}Tc hexamethyl propyleneamine oxime (HMPAO) single-photon emission CT (SPECT) on four normal volunteers and 34 patients with pathologically proved nasopharyngeal cancer. Twenty-three men and 15 women, 30–65 years old, were divided into four study groups: group 1 served as a control and consisted of four normal volunteers and six patients studied prior to cranial irradiation; group 2 patients had cranial irradiation half a year before the SPECT study ($n = 12$, one from group 1); group 3 patients were irradiated 1 year before the study ($n = 13$, three from group 1 and two from group 2); and group 4 patients were irradiated at least 5 years before SPECT imaging ($n = 9$). Six patients were studied twice. Quantification of the ^{99m}Tc-HMPAO brain SPECT studies was done separately by three radiologists to obtain the hypothalamus/occipital (H/O) and hypothalamus/parasagittal (H/P) ratios. Endocrinologic studies were performed in all cases and the hypothalamus-thyrotroph-thyroid, hypothalamus-gonadotroph-testis (ovary), hypothalamus-lactotroph, hypothalamus-somatotroph, and hypothalamus-corticotroph-adrenal axes were evaluated separately. We determined that regional hypothalamic blood flow was reduced after cranial irradiation in patients with nasopharyngeal cancer. The H/O ratio of groups 3 and 4 did not differ from that of group 2 (one-half year after cranial irradiation). The H/O ratio was significantly reduced 6 months and 1 year after cranial irradiation; mean \pm SD = 0.5801 ± 0.0829 ($p < .025$), 0.5725 ± 0.0791 ($p < .01$) versus 0.6477 ± 0.0458 before cranial irradiation, respectively. On the whole, deterioration of endocrine dysfunction could be said to be evident after cranial irradiation. There was progressive endocrine dysfunction over time.

Progressive deterioration of hypothalamic pituitary function is in contrast to the stable reduction in hypothalamic blood flow. Our study indicates that direct injury to the hypothalamic neurons, which secrete releasing hormone or somatostatin, rather than reduced cerebral blood flow is one of the major causes of progressive hypothalamic pituitary dysfunction after cranial irradiation with a fractional dose.

AJNR 12:661–665, July/August 1991

Hypopituitarism can occur after cranial irradiation [1–8]. Recently, progressive hypothalamic pituitary function impairment has been reported as early as 1 year after cranial radiation therapy [7, 8]. It is suggested that hypopituitarism after cranial irradiation may be associated with radiation damage to the hypothalamus, the hypothalamoportals circulation, or both [6]. Since nervous tissue is considered to be relatively radioresistant, its radiodamage is considered to occur indirectly through damage to vascular stroma [9, 10]. However, the brain tissue of the paraventricular and supraoptic nucleus of the hypothalamus was noted to be rather responsive to cranial irradiation. Thus, pituitary hormone deficit might be related to the cranial irradiation dose reaching the hypothalamic-pituitary axis. In order to understand the relation of regional blood flow and hypothalamus-pituitary function, we undertook a prospective study in a group of 34 nasopharyngeal carcinoma patients.

Received August 28, 1990; revision requested November 19, 1990; revision received January 7, 1991; accepted January 23, 1991.

This work was supported by National Science Council grant NSC 79-0412-B002-167, and a grant from the Institute of Biomedical Science, Academia Sinica.

¹ Drs. Chieng and Huang contributed equally to this study and each should be considered the first author of this article.

² Department of Radiology, National Taiwan University, Medical College and Hospital, 1, Chang-Te St., Taipei, Taiwan, 10016, Republic of China. Address reprint requests to P-U Chieng.

³ Department of Medicine, National Taiwan University, Medical College and Hospital, Taipei, Taiwan, 10016, Republic of China.

⁴ Department of Radiology, University of California, San Diego, CA 92103.

0195–6108/91/1204–0661
 © American Society of Neuroradiology

Technetium-99m hexamethyl propyleneamine oxime (HMPAO) is a lipophilic radiopharmaceutical that crosses the intact blood-brain barrier and is extracted by the brain tissue. Its distribution in the brain is proportional to the regional blood flow [11, 12]. Since ^{99m}Tc -HMPAO has the unique characteristics of excellent cerebral extraction and slow cerebral clearance, it has been used for cerebral blood flow imaging [11–13]. It provides an inexpensive method for assessing regional cerebral blood flow that is safe and easy to perform, yielding images of diagnostic quality. In this study, we used single-photon emission CT (SPECT) to detect ^{99m}Tc -HMPAO distribution after IV injection to evaluate the possibility of reduced blood flow to the hypothalamus and the time course of any such change after cranial irradiation.

Materials and Methods

We performed 44 cerebral blood flow studies with ^{99m}Tc -HMPAO SPECT on four normal volunteers and 34 patients with pathologically proved nasopharyngeal cancer with neither brain metastasis nor cerebral vascular disease as confirmed by cranial CT.

Subjects

Twenty three men and 15 women, 30–65 years old, were recruited for this study, with informed consent obtained in each case. This study population was divided into four groups. Group 1, the control group, had 10 people: four normal volunteers and six patients with nasopharyngeal cancer who had not yet received cranial irradiation. Group 2 consisted of 12 patients with nasopharyngeal cancer who had had cranial irradiation 6 months earlier (one patient was from group 1). Group 3 consisted of 13 patients with nasopharyngeal cancer who had had cranial irradiation 1 year earlier (three patients were from group 1 and two from group 2). Group 4 consisted of nine patients with nasopharyngeal cancer who had had cranial irradiation more than 5 years earlier. Six of the 38 subjects were imaged twice. No patient was on medication, except a few subjects in group 4 who took thyroid, adrenocortical, and/or sexual hormone for replacement therapy.

^{99m}Tc -HMPAO Brain SPECT

Freshly prepared ^{99m}Tc -HMPAO (Ceretek; Amersham, International; United Kingdom) was administered intravenously into the antecubital vein in a dose of 15 mCi (550 MBq). Five to ten minutes after IV injection, brain SPECT was performed on a dual-head system (Picker International) with a PCS-512 computer unit for data acquisition and reconstruction. The data was acquired in a 64×64 pixel matrix through a 180° rotation at an angular interval of 6° (30 angles) in 15-sec intervals each. Reconstruction was performed by a standard back projection using a Ramp filter for a 64×64 pixel matrix image. The whole procedure required 10 to 15 min.

Quantification of the ^{99m}Tc -HMPAO brain SPECT from the multiplanar sections was performed independently by three radiologists (Fig. 1, top). The anatomic position of the hypothalamus on brain SPECT was reviewed and agreed upon by all three. A 6×6 pixel region of interest was defined over the right and left hypothalamic region and the right and left occipital regions on the same transverse tomogram of the brain SPECT (Fig. 1, bottom left). The hypothala-

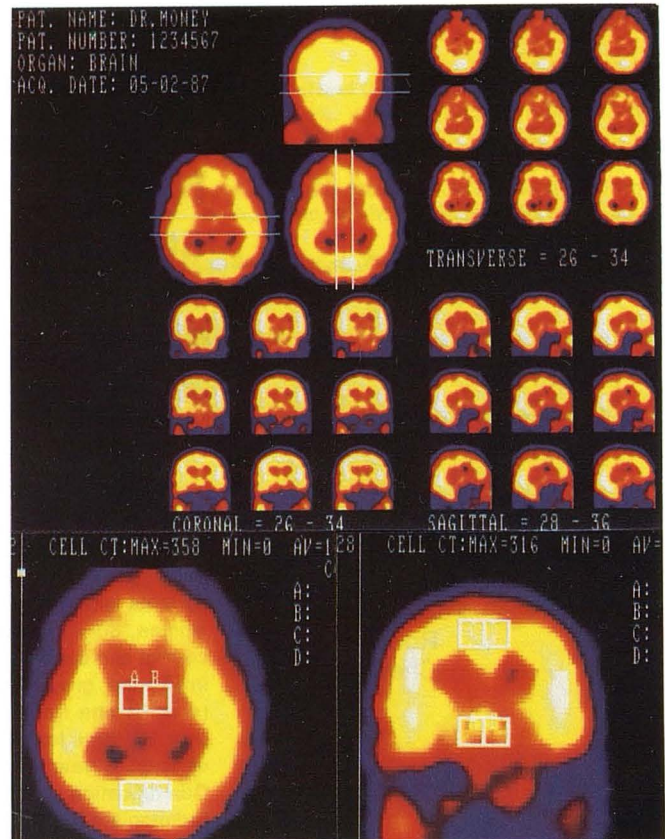


Fig. 1.—Quantification of cerebral blood flow of hypothalamus by ^{99m}Tc -HMPAO brain perfusion SPECT in multiplanar sections (top). Square regions of interest of 6×6 pixels were defined over right and left hypothalamus, right and left occipital regions on same transverse tomogram (bottom left), and on parasagittal cortex of coronal tomogram (bottom right) of the brain SPECT.

mus/occipital (H/O) ratio was obtained, and the average ratio of the three observers was used as final data.

$$\text{H/O ratio} = \frac{\text{total counts of both hypothalamus regions}}{\text{total counts of both occipital regions}}$$

Quantification was also performed on the coronal sections; however, the region of interest was located on the same tomogram at the hypothalamic and parasagittal cortex instead of the occipital region. Consequently, a hypothalamus/parasagittal (H/P) ratio was obtained (Fig. 1, bottom right).

Mode of Irradiation

All cases of nasopharyngeal cancer were randomly allocated for treatment either by a tele- ^{60}Co unit or a linear accelerator using 10 MV photons, for 35–40 fractions at a rate of five treatments per week, with a break of about 10 days midway through the course [14]. The total dose to the primary lesion was 7000 cGy in 8 weeks, plus 5000–6000 cGy to bilateral cervical chains. The estimated total dose delivered over an 8-week period was 4600–5600 cGy for the hypothalamic-pituitary area. No reduction of portal size was allowed during the course of treatment. For an irregular and unusual primary site lesion, portals were arranged individually, and a booster dose of

another 1000 cGy to the target might be given in case of residue at the end of treatment.

Endocrinologic Studies

All patients were studied from 8–9 A.M. after an overnight fast. Two basal blood samples were taken 15 min apart for serum follicle-stimulating hormone (FSH), luteinizing hormone (LH), thyrotropin (TSH), prolactin (PRL), growth hormone (GH), cortisol, adrenocorticotropic hormone (ACTH), and estradiol or testosterone. Then, hypophysiotrophic hormone was given as an IV bolus (ovine corticotrophin-releasing hormone [oCRH 1-41, 1 μ g/kg body weight], luteinizing hormone-releasing hormone [LHRH, 100 μ g], human growth hormone-releasing hormone [hGRH 1-4, 1 μ g/kg body weight], and thyrotropin-releasing hormone [TRH, 400 μ g]). Blood was sampled for pituitary hormones and cortisol at 15-min intervals for 60 min, then at 30-min intervals for an additional 60 min, and thereafter at 60-min intervals for up to 240 min after injection. Next morning, all patients received an insulin tolerance test (ITT, 0.125 U/kg body weight) at 8:00 A.M. after an overnight fast, and blood was sampled for blood sugar, cortisol, and GH. All blood sugar levels declined more than 50% from the baseline. Hormonal response to hypothalamic-releasing hormone and insulin hypoglycemia among patients in groups 2 and 3 were compared with those obtained before cranial irradiation in each individual. Hormonal responses of patients in group 4 were compared with those obtained from age- and sex-matched controls [6].

Hypothalamus-thyrotroph-thyroid, hypothalamus-gonadotroph-testis (ovary), hypothalamus-lactotroph, hypothalamus-somatotroph, and hypothalamus-corticotroph-adrenal axes were evaluated separately.

Ethical Considerations

This study was performed in compliance with the recommendation of the Declaration of Helsinki [12]. It was approved by the Human Subjects Committee of the National Taiwan University Hospital. Informed consent was obtained from all patients.

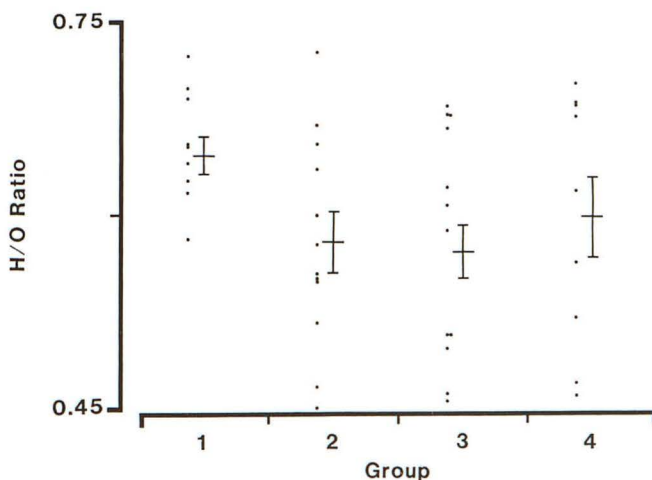


Fig. 2.—Ratio of hypothalamus and occipital cortex (H/O) count obtained from transaxial ^{99m}Tc -HMPAO brain SPECT images in nasopharyngeal cancer patient groups 1–4.

Results

The quantification of regional hypothalamic blood flow by ^{99m}Tc -HMPAO brain SPECT was quantified by three radiologists for the four groups as determined by the H/O ratio, which is shown in Figure 2, with 2 SDs.

The H/O ratio was significantly reduced 6 months and 1 year after cranial irradiation: mean \pm SD = 0.5801 ± 0.0829 ($p < .025$), 0.5725 ± 0.0791 ($p < .01$) versus 0.6477 ± 0.0458 before cranial irradiation, respectively. The H/O ratio was also reduced in group 4, 0.5986 ± 0.0963 , but did not reach statistical significance ($.05 < p < .1$). Four of 12 patients in group 2, five of 13 patients in group 3, and three of nine patients in group 4 had an H/O ratio below 2 SD of the normal mean; i.e., 0.5561 (Fig. 2).

Similar data were obtained for the H/P ratio on the coronal sections (Fig. 3). The H/P ratio was significantly reduced in groups 2, 3, and 4: mean \pm SD = 0.6650 ± 0.0958 ($p < .01$),

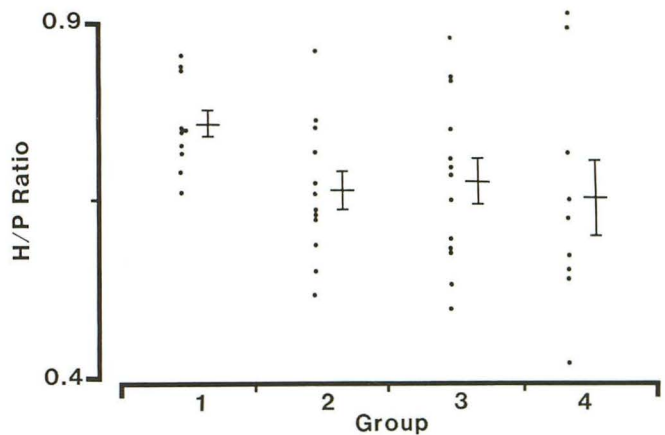


Fig. 3.—Ratio of hypothalamus and parasagittal cortex (H/P) count obtained from coronal ^{99m}Tc -HMPAO brain SPECT images in nasopharyngeal cancer patient groups 1–4.

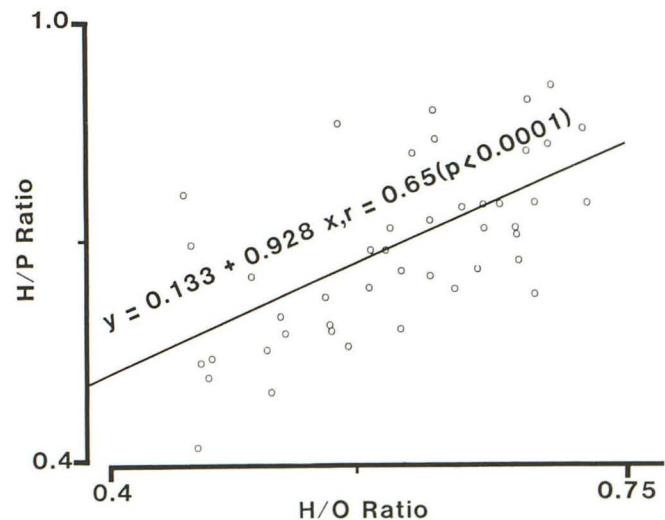


Fig. 4.—Correlation of hypothalamus/parasagittal (H/P) ratio and hypothalamus/occipital (H/O) ratio as evaluated by linear regression. We found a significant correlation between H/P and H/O ratios ($r = .65$, $p < .0001$), $y = 0.1334 + 0.93x$.

0.6776 ± 0.1170 ($p < .05$), 0.6558 ± 0.1619 ($p < .05$) versus 0.7564 ± 0.0641 before cranial irradiation, respectively. Four of 12 patients in group 1, five of 13 patients in group 3, and four of nine patients in group 4 had H/P ratios below 2 SD of the normal mean; i.e., 0.6282. Fifteen patients had H/O and/or H/P ratios below 2 SD of the normal mean.

Correlation of the H/P and H/O ratios was evaluated by linear regression (Fig. 4). We found a significant correlation between H/P and H/O ratios ($r = .65$, $p < .0001$), $y = 0.1334 + 0.93x$.

In this study, six patients with nasopharyngeal cancer were imaged twice with brain SPECT. The change in regional hypothalamic blood flow, expressed in the plot of H/O ratio over time, is shown in Figure 5. There was a decrease in the H/O ratio after cranial irradiation in five of the patients. Similarly, the H/P ratio was also reduced in four of these six patients after cranial irradiation (Fig. 6).

The results of the endocrinologic studies of all 34 patients are summarized in Figure 7 and Table 1. A deterioration of

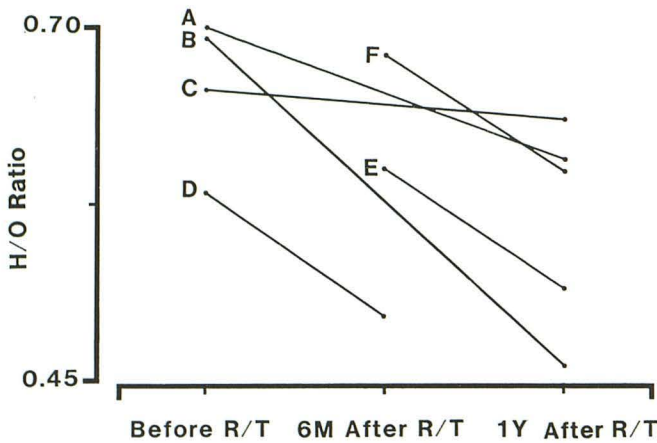


Fig. 5.—Results of study in which six patients with nasopharyngeal cancer were imaged twice with ^{99m}Tc-HMPAO brain SPECT after cranial irradiation. In five patients, the hypothalamus/occipital (H/O) ratio shows a decrease in regional hypothalamic blood flow after cranial irradiation.

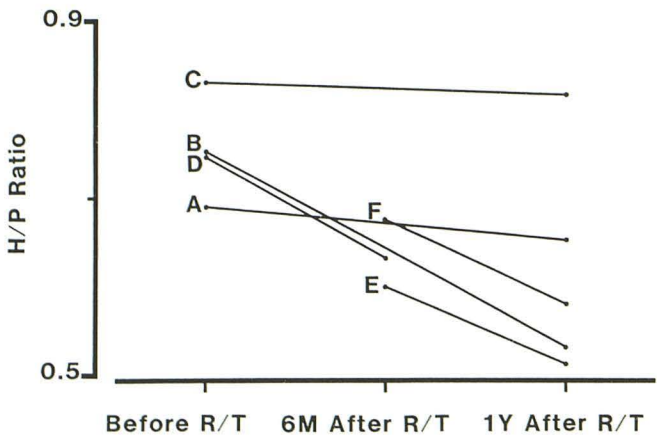


Fig. 6.—The hypothalamus/parasagittal (H/P) ratio shows a similar decrease in regional cerebral blood flow in four of the six patients after cranial irradiation.

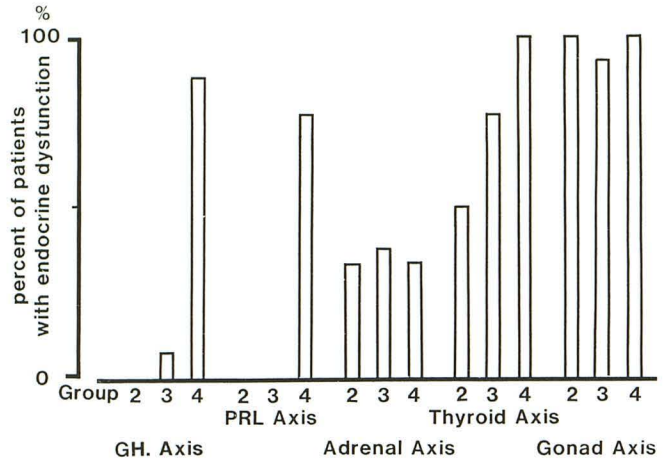


Fig. 7.—Summary of endocrinologic studies of 34 patients (groups 2–4) with nasopharyngeal cancer after cranial irradiation. Deterioration of endocrine function was evident, but there was no significant difference in function before and after irradiation in group 2 and 3 patients. After irradiation, endocrine function was significantly worse in group 4 as compared with the other groups.

TABLE 1: Endocrine Dysfunction in Four Groups of Patients

Group	No. of Patients	No. of Impaired Endocrine Axes ^a
1	10	0
2	12	1.82 ± 0.60
3	13	2.23 ± 0.60 ^b
4	9	4.00 ± 1.0 ^c

^a Mean ± SD.
^b .05 < $p < .1$ compared with group 2 by Student's t test.
^c $p < .0001$ compared with group 2 or 3 by Student's t test.

endocrine function after cranial irradiation was evident in group 4. There was no significant difference in function before and after irradiation among the patients in groups 2 and 3. After irradiation, endocrine function was significantly worse in group 4 as compared with the other groups.

Discussion

In this study we demonstrated that hypothalamic blood flow was reduced after cranial irradiation in patients with nasopharyngeal cancer. The H/O ratio of group 3 (1 year after cranial irradiation) and group 4 (5 years after cranial irradiation) was not different from that of group 2 (half a year after cranial irradiation).

With the development of radiopharmaceutical agents, quantifiable measurement of regional cerebral blood flow is now possible on a routine basis [11–13]. Several properties of ^{99m}Tc-HMPAO made this new radiopharmaceutical ideal for SPECT imaging of cerebral blood flow; i.e., good brain uptake (about 80% in one pass), prolonged retention of activity in the brain, slow regional redistribution, good physical characteristics, and easy availability of ^{99m}Tc [14].

Since the vertebral artery and the posterior cerebral arteries were shielded from cranial irradiation, the cerebral blood flow

to the occipital area should be relatively unchanged. The lack of significant difference in the H/O and H/P ratios in groups 2, 3, and 4 suggested that the reduction of hypothalamic blood flow, which is supplied by the anterior and middle cerebral arteries, is stabilized 6 months after insult from cranial irradiation. However, two of the six patients who had two cerebral blood flow studies showed a further decrease of H/P and H/O ratio 1 year after cranial irradiation. Neither was studied before cranial irradiation. Further follow-up study is needed to clarify the trend.

There are several ways to interpret the reduced H/O and H/P ratio. These include reduced hypothalamic volume, alteration of brain uptake mechanism, alteration of radiopharmaceutical metabolism, reduced metabolic activity or cellular dysfunction, and truly reduced blood flow. With the well-known limitation of CT, we can find no discernible lesion in the hypothalamus after cranial irradiation [6]. Whether there is persistent alteration of brain uptake mechanism and/or altered radiopharmaceutical metabolism is unknown. Reduced metabolic activity and reduced blood flow may be interrelated as autoregulation mechanisms and may be present in the hypothalamus. Among these possibilities, we believe reduced hypothalamic blood flow is the most likely explanation for decreased H/O or H/P ratio after cranial irradiation.

The paraventricular hypothalamus and other structures in its vicinity, as well as the supraoptic nucleus, would be included in the hypothalamus region of interest. However, the radiation effect on these deep cerebral structures might be rather similar, and thus quantification of regional cerebral blood flow at the hypothalamus should be verified on ^{99m}Tc -HMPAO brain SPECT. The regional cerebral blood flow at the pituitary was not quantified because this structure was not precisely located on our ^{99m}Tc -HMPAO brain SPECT image, which was definitely not a high-resolution SPECT study.

Since not all patients with impaired hypothalamic pituitary function had a decreased H/O or H/P ratio, we believe that reduced hypothalamic blood flow and decreased endocrine function are independent. Furthermore, much more severe hypopituitarism was found in group 4 patients [6] whose H/O or H/P ratio was almost equal to that of group 2 patients, and there was minimal hypopituitarism in group 2 patients [7]. The different sensitivity of each hypothalamus-pituitary axis also strengthens the notion that neuron damage and reduced blood flow may be independent in these patients. However, we still cannot exclude chronic ischemic changes as one of the causes of the progressive pituitary dysfunction. As in our previous studies, we found relatively few cases of hypothalamic-pituitary dysfunction 6 months or 1 year after cranial irradiation [7, 8]; but, as we report here, there was significant hypopituitarism in group 4 patients, who were irradiated more than 5 years before the study [6]. The progressive deterioration of hypothalamic pituitary function was in contrast to the stably reduced hypothalamic blood flow. If the hypopituitarism after cranial irradiation is attributed solely to the vascular damage, then a stabilized rather than progressive hypothalamic-pituitary dysfunction would be expected after cranial irradiation.

Histologically, early changes in the CNS after high doses of cranial irradiation include inflammation (demyelination) progressing to necrosis and fibrosis as a result of blood vessel sclerosis and thrombosis. Moreover, somatostatin and GRH neurons are distributed unevenly in the hypothalamus; if they have different radiosensitivity, more somatostatin neurons would be damaged as suggested by the previous study's data [8]. However, these patients received a fractionated dose of cranial irradiation, totaling about 5000 cGy to the hypothalamus and pituitary area, delivered over 8 weeks [15]. No anatomic change in the hypothalamus area could be found by brain CT in any of the group 4 patients [6]. With a fractional dose there may not be as much vascular damage as in single, large-dose irradiation. This study indicates that direct injury to the hypothalamic neurons, which secrete releasing hormone or somatostatin, is one of the major causes of progressive hypothalamic pituitary dysfunction after cranial irradiation with a fractional dose.

REFERENCES

1. Larkins RG, Martin FIR. Hypopituitarism after extracranial irradiation: evidence for hypothalamic origin. *Br Med J* **1973**;1:152-153
2. Perry-Keene DA, Connelly JE, Young RA, Wethenall HNB, Martin FIR. Hypothalamic hypopituitarism following external radiotherapy for tumors distant from the adenohypophysis. *Clin Endocrinol* **1976**;5:373-380
3. Shalet SM, Beardwell CG, MacFarlane IA, Jones PHM, Pearsen D. Endocrine morbidity in adults treated with cerebral irradiation for brain tumors during childhood. *Acta Endocrinol* **1977**;84:673-680
4. Samman NA, Vieto R, Schultz PN, et al. Hypothalamic pituitary and thyroid dysfunction after radiotherapy to the head and neck. *Int J Radiat Oncol Biol Phys* **1982**;8:1857-1867
5. Lam KSL, Wang C, Yeung RTT, et al. Hypothalamic hypopituitarism following cranial irradiation for nasopharyngeal carcinoma. *Clin Endocrinol* **1986**;24:643-651
6. Huang TS, Huang LS, Tung CC, et al. Effect of cranial irradiation on hypothalamus, pituitary function. *J Formosa Med Assoc* **1989**;88:682-688
7. Huang TS, Chen ST, Lui LT, Chang YL, Hsu MM. Early effects of cranial irradiation on hypothalamus pituitary function. *J Formosa Med Assoc* **1990**;89:541-547
8. Huang TS, Lui LT, Hsu MM, Chen FW. Follow-up study of hypothalamus pituitary function: one year after cranial irradiation. *J Formosa Med Assoc* **1991** (in press)
9. Travis EL. *Primer of medical radiobiology*. Chicago: Year-book Medical, **1975**
10. Duncan W, Nias AHW. *Clinical radiobiology*. London: Churchill Livingstone, **1977**
11. Sharp PF, Smith FW, Gemmell HG. Technetium-99m HMPAO stereoisomers as potential agents for imaging regional cerebral blood flow: human volunteer studies. *J Nucl Med* **1986**;27:171-172
12. Holm S, Anderson AR, Vorstrup S, Lassen NA, Paulson OB, Holmes RA. Dynamic SPECT of the brain using lipophilic technetium-99m complex, PnAo. *J Nucl Med* **1985**;26:1129-1134
13. Matsuda H, Oskoi SD, Kinuya K, et al. Nuclear medicine atlas: Tc-99m HMPAO brain perfusion tomography atlas using a high resolution SPECT system. *Clin Nucl Med* **1990**;15:428-431
14. Yeh SH, Liu RS, Hu HH, Wong WJ. Brain SPECT imaging with ^{99m}Tc -hexamethylpropyleneamine oxime in the early detection of cerebral infarction. Comparison with transmission computed tomography. *Nucl Med Commun* **1986**;7:873-878
15. Huang SC, Tak L, Lynn TC. Nasopharyngeal cancer: study III, a review of 1206 patients treated with combined modalities. *Int J Radiat Oncol Biol Phys* **1985**;11:1789-1793