

## Canavan Disease: CT and MR Imaging of the Brain

Jan Brismar<sup>1</sup>  
 Gudrun Brismar<sup>2</sup>  
 Generoso Gascon<sup>3</sup>  
 Pinar Ozand<sup>3</sup>

Canavan disease (spongy degeneration of the brain) is a rare lethal neurodegenerative disorder of infancy; fewer than 100 cases have been reported. We describe a series of nine patients with enzymatic defects and clinical features consistent with Canavan disease; in two patients the disease was proved by biopsy. All patients were examined with CT and seven with MR. In every instance, both CT and MR showed white-matter disease, sometimes sparing the external and internal capsules, the corpus callosum, and the deep cerebellar white matter. Atrophic changes were found in six patients; the changes were marked in one and slight in five. There was no obvious correlation between the severity of the white-matter disease and the clinical presentation—one patient with severe white-matter disease was clinically normal.

The CT and MR findings in Canavan disease are nonspecific and somewhat nonuniform: its preautopsy diagnosis relies primarily on biochemical findings.

*AJNR* 11:805–810, July/August 1990

Spongy degeneration of the brain, better known by the eponym Canavan disease [1] or van Bogaert–Bertrand disease [2], is a lethal neurodegenerative disorder of unknown cause characterized by severe motor and mental retardation, blindness, and macrocephaly. The symptoms usually start before 10 months of age, the disease progresses to decerebrate rigidity, and death usually occurs before the age of 3 years [3]. While an underlying metabolic block has now been identified for most of the neurodegenerative disorders of childhood, and biochemical diagnostic tests have subsequently been developed, Canavan disease has, together with Alexander disease, remained among the few disorders requiring brain biopsy for diagnosis [4]. Recently, however, evidence has accumulated that Canavan disease is associated with a profound deficiency of the enzyme aspartoacylase, resulting in an increased amount of *N*-acetylaspartic acid in urine and plasma [5–8]. A very high concentration of *N*-acetylaspartic acid is present in the normal human brain [9]; however, its exact physiologic function and the pathogenesis of Canavan disease as related to elevated levels of this compound remain unknown.

In this report, the radiologic findings in nine patients with a clinical history indicative of Canavan disease and proved aspartoacylase deficiency are presented.

### Materials and Methods

Our medical center is the only site within the Kingdom of Saudi Arabia with the resources for advanced biochemical and genetic workup in neurodegenerative disorders of childhood; therefore, as a tertiary referral center, we receive a large number of such patients. In these patients, an extensive biochemical evaluation is always performed to exclude the different enzymatic defects known to cause degeneration of the nervous system. This evaluation was recently expanded to include tests for aspartoacylase deficiency; this deficiency has now been found in nine patients (Table 1). All these patients had, or later developed, a clinical picture compatible with Canavan disease. In two patients the diagnosis was verified by brain

Received June 27, 1989; revision requested August 30, 1989; revision received January 27, 1990; accepted January 29, 1990.

<sup>1</sup> Department of Radiology, King Faisal Specialist Hospital and Research Centre, P.O. Box 3354, Riyadh 11211, Saudi Arabia. Address reprint requests to J. Brismar.

<sup>2</sup> Department of Surgery, Section of Ophthalmology, King Faisal Specialist Hospital and Research Centre, Riyadh 11211, Saudi Arabia.

<sup>3</sup> Department of Pediatrics, King Faisal Specialist Hospital and Research Centre, Riyadh 11211, Saudi Arabia.

0195–6108/90/1104–0805  
 © American Society of Neuroradiology

**TABLE 1: Clinical Findings in Patients with Aspartoacylase Deficiency and Features Consistent with Canavan Disease**

Case No.	Sex	Age at:		Clinical Status at Time of CT	Ophthalmologic Findings	Aspartoacylase in Human Fibroblasts (nmol · mg · hr) <sup>a</sup>
		First sign	Clinical and CT Studies			
1	F	3 mo	3½ yr	Severe mental retardation; macrocephaly; truncal axial hypotonia; spastic quadriplegia	Poor vision—? blind; mild optic atrophy; searching nystagmus	0.07
2	M	40 d	12 mo	Severe mental retardation; macrocephaly; truncal axial hypotonia; spastic quadriplegia	Poor vision; mild optic atrophy	0.09
3	M	2 mo	8 mo	Mental retardation; macrocephaly <sup>b</sup> ; severe truncal hypotonia; mild spasticity	Able to see; pupils responded sluggishly to light; mild optic atrophy	0.15
4	F	4 mo	16 mo	Severe mental retardation; macrocephaly; markedly axial hypotonia; increased tendon reflexes	Poor vision—? blind; minimal optic atrophy; nystagmoid eye movements	0.04
5	F	8 mo	2 yr	Severe mental retardation; normal-sized head; midline hypotonia; brisk tendon reflexes	Blind; bilateral severe optic atrophy	0.27
6	F	"Early infancy"	3 yr	Severe mental retardation; normal-sized head; midline hypotonia; very brisk tendon reflexes	Blind; bilateral severe optic atrophy	0.00
7	M	6 mo	12 mo	Severe mental retardation; normal-sized head; midline hypotonia; spastic diplegia	Blind; bilateral severe optic atrophy	0.35 <sup>c</sup>
8	M	10 mo	10 mo	Normal development; macrocephaly; neurologically normal <sup>d</sup>	Normal	0.36
9	M	2 mo	2 yr	Severe mental retardation; macrocephaly; some midline hypotonia; spastic diplegia	Probably blind; normal fundi	0.40 <sup>c</sup>

<sup>a</sup> Normal range:  $3.66 \pm 1.98$  nmol · mg · hr (mean  $\pm$  SD).

<sup>b</sup> Macrocephaly not fully developed until 12 months of age.

<sup>c</sup> Diagnosis of Canavan disease verified through brain biopsy.

<sup>d</sup> Lower-limb hyperreflexia started developing 2 months later.

biopsy. The detailed clinical and biochemical findings in these patients is the subject of a forthcoming article (Gascon et al., unpublished data).

All patients were examined with CT (GE 9800, Siemens Somatom, or Picker 1200SX unit) with 8- or 10-mm-thick contiguous slices. In four patients the examination was also performed after IV contrast administration (Ultravist, 300 mg/ml, 2 ml per kg body weight). In one patient multiple CT examinations were performed over a 7-month interval. The CT examinations were evaluated for signs of cortical atrophy, ventricular dilatation, infratentorial atrophy, and white-matter disease. The findings were subjectively graded as normal, slight or moderate atrophy, or marked or severe atrophy.

In seven patients MR was performed also (Picker Vista unit at 1.5 T). A dual-echo T2-weighted axial spin-echo sequence, 2000–2300/40,80 (TR/TE), with 7-mm contiguous slices was used. In all but one patient a sagittal midline T1-weighted scout view or a sagittal T1-weighted sequence (600–700/20) was obtained also. The MR studies were evaluated for posterior fossa atrophy and supratentorial gray-matter reduction, as well as for signs of white-matter disease (graded

as normal myelination, some [but defective] myelination, or no sign of myelination) for different regions of the brain.

## Results

The results of the CT and MR studies are summarized in Table 2. White-matter disease was seen in all cases; in all but one (case 6, Fig. 1), the changes were judged as severe. The white-matter disease was distributed symmetrically in every patient. The degree of white-matter disease was not related to age, aspartoacylase level, or even clinical symptomatology. In one patient with no clinical symptoms except macrocephaly (case 8), severe white-matter disease was seen on both CT and MR (Fig. 2).

The central white matter was usually better preserved than the subcortical white matter. In two of the six patients with severe subcortical white-matter disease, there was normal



**TABLE 2: CT and MR Findings in Patients with Aspartoacylase Deficiency and Clinical Findings of Canavan Disease**

Finding	Case No.								
	1	2	3 <sup>a</sup>	4 <sup>a</sup>	5	6	7	8	9
<b>CT</b>									
Cortical atrophy	++	+	N	N	N	N	+	N	N
Ventricular dilatation	++	N	N	N	N	+ <sup>b</sup>	N	N	N
Infratentorial atrophy	++	+	N	+	N	N	N	N	N
White-matter disease	++	++ <sup>c</sup>	++ <sup>c-e</sup>	++ <sup>c</sup>	++ <sup>d</sup>	+ <sup>d</sup>	++	++ <sup>d</sup>	++ <sup>c</sup>
<b>MR</b>									
White-matter changes									
Internal capsule									
Anterior limb	+	++	-	-	N	N	N	+	++
Posterior limb	+	++	-	-	N	N	+	+	++
External capsule	++	++	-	-	N	N	N	++	++
Genu of corpus callosum	++	++	-	-	+	N	++	+	+
Subcortical white matter	++	++	-	-	++	+	++	++	++
Posterior fossa	+	+	-	-	N	N	+	++	+
Posterior fossa atrophy	++	+	-	-	N	N	N	N <sup>f</sup>	+
Gray-matter reduction	+	+	-	-	N	N	N	++	+
Interval between CT and MR	13 mo	13 mo	-	-	4 d	3 d	1 d	2 d	1 mo

Note.—N = absent; + = slight or moderate; ++ = marked or severe.

<sup>a</sup> MR not performed.

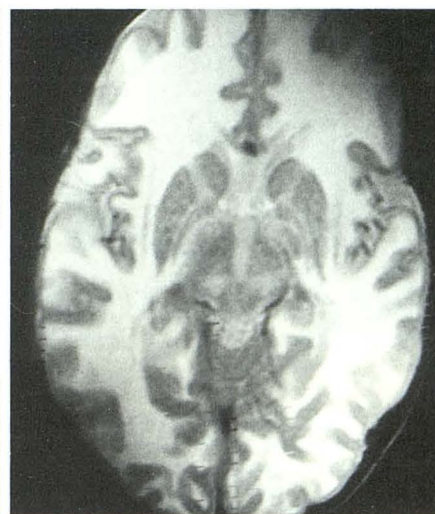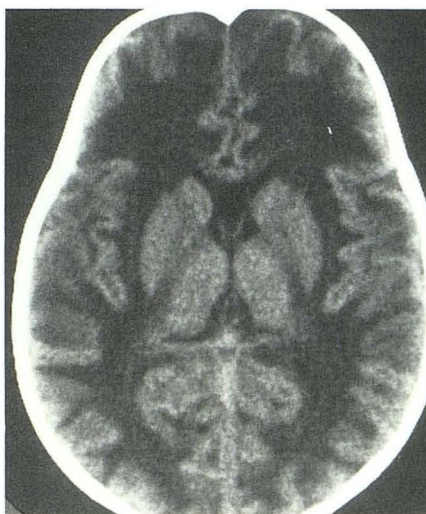
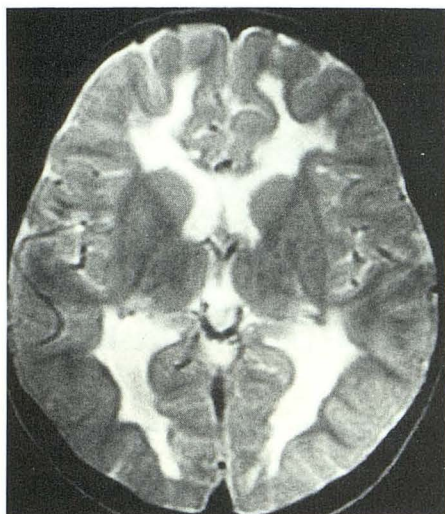
<sup>b</sup> Only slight dilatation of third ventricle.

<sup>c</sup> Decreased attenuation of thalami and globus pallidus also.

<sup>d</sup> Both nonenhanced and enhanced CT studies.

<sup>e</sup> Repeat CT examination 7 months later showed progression of white-matter disease.

<sup>f</sup> No lateral view available.



**Fig. 1.**—Case 6: 3-year-old blind, severely retarded girl with truncal hypotonia, brisk limb reflexes, and aspartoacylase deficiency. MR image (2300/80) shows normal myelination of internal and external capsules and genu of corpus callosum. Supratentorial white-matter disease with peripheral preservation of myelin. Posterior fossa appeared normal.

**Fig. 2.**—Case 8: 10-month-old macrocephalic boy, developmentally and neurologically normal, referred to rule out hydrocephalus. Aspartoacylase deficiency.

**A,** CT shows normal-sized ventricles and no sign of atrophy, but there is severe white-matter disease.

**B,** MR image (2000/80 at 1.5 T) verifies severe white-matter disease supratentorially. Remaining myelin within internal capsule and corpus callosum is abnormal, appearing brighter than normal. Note marked reduction of gray-matter thickness. Severe white-matter disease was present within posterior fossa also.

myelination of at least some of the central white matter (Figs. 3 and 4); in the only patient with less than severe subcortical white-matter disease, myelination of the central white-matter structures appeared normal (Fig. 1).

Findings other than white-matter changes were observed. In four patients the thickness of the cortical gray matter appeared reduced, markedly so in one (Fig. 2). Also, the central gray matter seemed to be affected: in four patients



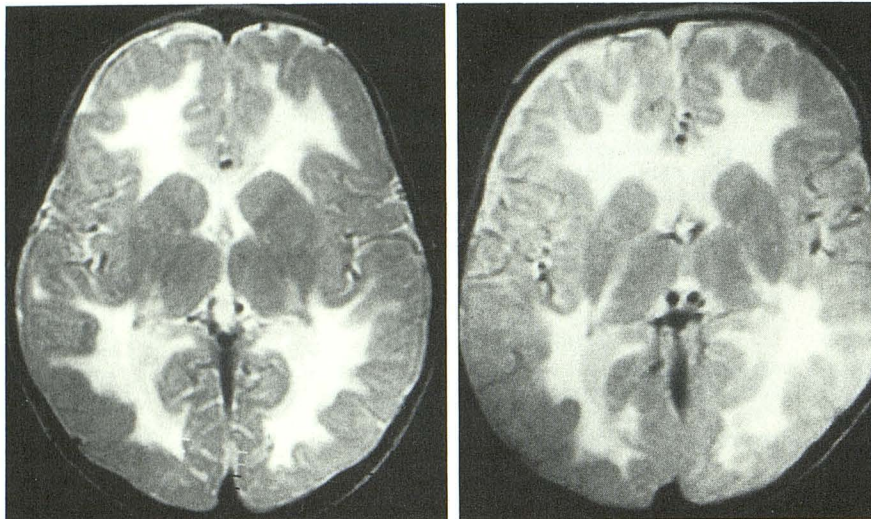


Fig. 3.—Case 5: 2-year-old mentally retarded girl with aspartoacylase deficiency, midline hypotonia, and brisk limb reflexes. No macrocephaly. MR image (2300/80) shows severe white-matter disease of subcortical white matter. Central white matter within internal and external capsules appears preserved, while myelination within genu of corpus callosum is abnormal. No gray-matter disease was seen. Posterior fossa white matter appeared normal.

Fig. 4.—Case 7: 12-month-old mentally retarded boy with midline hypotonia and spastic diplegia. Head was of normal size. Canavan disease was confirmed by brain biopsy. MR image (2000/80) shows marked subcortical white-matter disease. White-matter changes seen also within posterior limb of internal capsule and genu of corpus callosum. Anterior limb of internal capsule and external capsule appear normal.

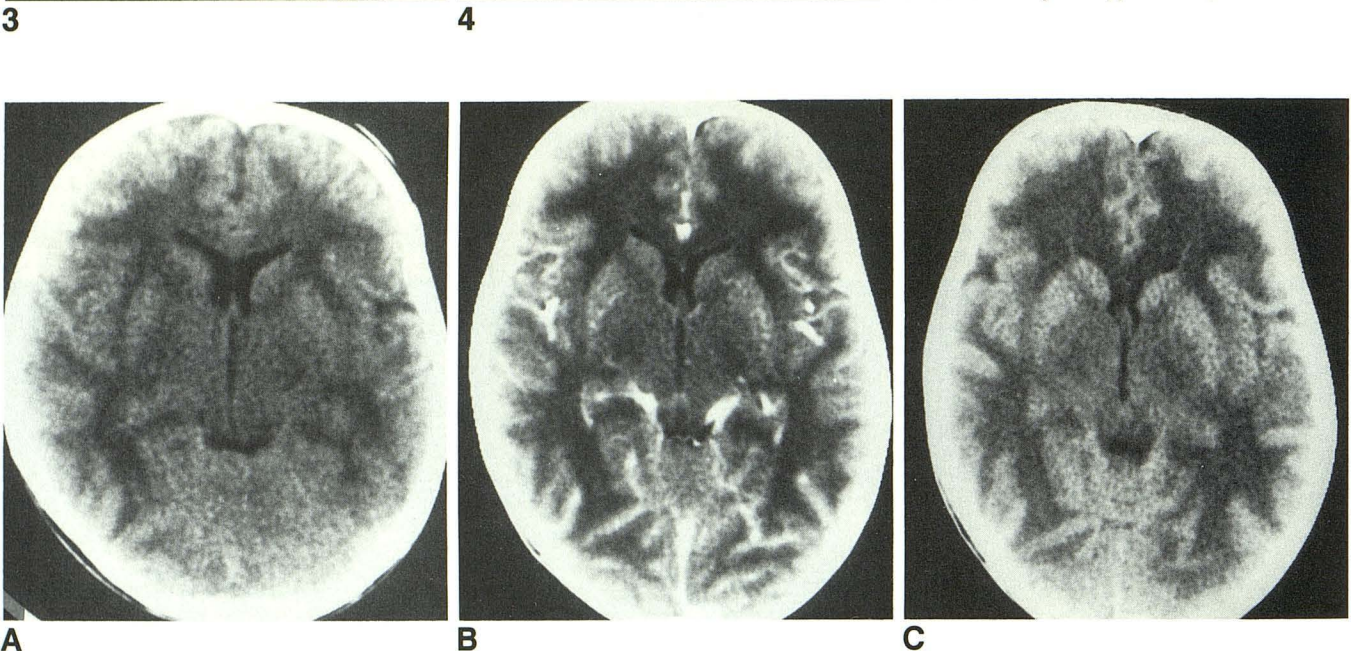


Fig. 5.—Case 3: 8-month-old mentally retarded boy with aspartoacylase deficiency, axial hypotonia, mild limb spasticity, and normal-sized head. A, CT shows marked, generalized white-matter disease; there are no signs of atrophy. B, IV contrast-enhanced CT scan at 12 months of age shows some gyral enhancement. C, CT scan at 15 months of age shows some progression of demyelination, especially in left parietooccipital region. Also note that density within globus pallidus and thalamus is somewhat reduced.

decreased attenuation was seen within the thalamus and globus pallidus, probably representing edema (Fig. 5).

In four patients CT was performed both before and after IV administration of contrast medium; no evidence of abnormal contrast enhancement was found, except that gyral enhancement was seen in one patient (Fig. 5).

Marked atrophic changes with ventricular dilatation and widening of sulci and fissures were found in only one child, the oldest patient in the series (case 1, Fig. 6). Marked atrophic changes within the posterior fossa were also seen in this patient. Slight atrophic changes were found in five patients; in three there were no signs of atrophy.

## Discussion

Canavan disease is a rare form of leukodystrophy, inherited as an autosomal-recessive disease. A 1965 review [3] found that a total of 26 cases had been reported internationally. A 1979 review [10] found 48 affected families worldwide. Seventeen children were added in a 1983 series [11]. Including our material and single case presentations, less than 100 cases have been reported to date.

The CT findings in verified Canavan disease have been addressed in several case reports [12–17]; in addition, the findings in presumed Canavan disease have been discussed

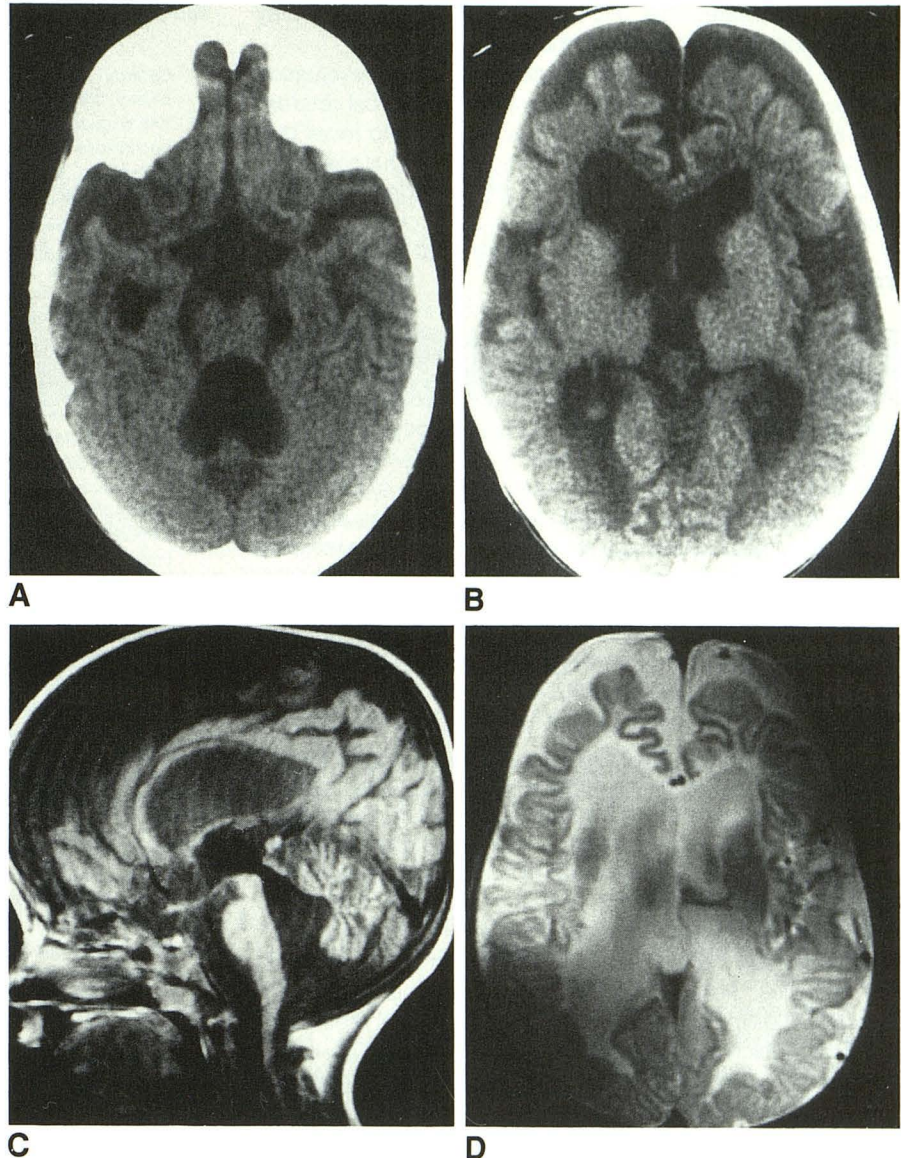


**Fig. 6.**—Case 1: 3½-year-old severely mentally retarded, macrocephalic girl with axial hypotonia and spastic quadriplegia.

**A and B,** CT shows severe white-matter disease and atrophic changes, supra- as well as infratentorially.

**C,** Sagittal midline MR section (700/20) shows extent of atrophic changes in posterior fossa.

**D,** Axial MR image (2000/80) confirms extensive white-matter disease and also reduction of gray-matter thickness.



[18, 19]. The first case was reported by Boltshauser et al. [12, 13]. Their patient showed pronounced white-matter disease and normal-sized ventricles at 11 months of age; 10 months later the ventricles were markedly dilated. Rushton et al. [15] found normal-sized ventricles and symmetrically decreased white-matter density in two patients with verified Canavan disease. As similar findings were reported by others [14, 19], these authors concluded that this CT picture was typical enough to permit differentiation between Canavan disease and both adrenoleukodystrophy and Alexander disease. An additional case with a similar CT presentation led Andriola [16] to suggest that the findings may be typical enough to obviate brain biopsy.

The results from our series, however, supported by other case reports [13, 17], show that the CT picture is less uniform and that changes of cortical atrophy or ventricular dilatation are by no means incompatible with the diagnosis of Canavan

disease. Ventricular dilatation was also documented in a review of 16 autopsy cases [3]: the ventricular system was definitely enlarged in one patient and slightly enlarged in seven.

It has been discussed whether Canavan disease is a dysmyelinating or a demyelinating disorder [3]. In one of our cases, followed over a 7-month period with repeat CT examinations, progression of white-matter disease was observed (Fig. 5). This finding, as well as a similar observation by Rushton et al. [15], supports the now prevalent opinion that Canavan disease is a process of demyelination.

An analysis of histologic data from autopsies [3] revealed that the brain was usually large and heavy with diffuse lack of myelin; distinctive sponginess explained the macrocephaly. These changes were found to be most pronounced at the junction of the cortex and white matter. However, the finding of preserved peripheral myelination in one of our cases (case



6, Fig. 1) indicates that the changes in earlier stages may have a more periventricular distribution.

Even if the patients usually undergo radiologic evaluation with a clinical picture of severe mental and physical retardation, as did eight of our patients, it is important to recall that the only clinical finding may be macrocephaly. Our case 8 as well as both patients of Rushton et al. [15] (aged 10 and 11 months, respectively) were clinically and neurologically intact at the time of CT; despite this, CT showed severe white-matter disease (Fig. 2).

The radiologic differential diagnosis in the individual patient with white-matter disease is usually difficult to establish. While a few neurodegenerative disorders exhibit more uniformly distinctive features, such as symmetric low-density CT lesions with peripheral enhancement in adrenoleukodystrophy [20] and symmetric homogeneous thalamic hyperdensity in Sandhoff disease [21], most white-matter diseases exhibit characteristic features only sporadically. As experience accumulates it becomes increasingly obvious that in the large majority of cases a combined neurologic and biochemical approach must be used in order to achieve a definitive diagnosis in patients with a clinical and neuroradiologic appearance of white-matter disease. Chromosome studies and the clinical presentation can be used to rule out Cockayne syndrome. Blood amino acid and urinary organic acid determinations eliminate disorders of the intermediary metabolism; in difficult cases these tests could be supplemented by serial determinations of blood lactate and lactate acid levels in response to carbohydrate loading, to exclude congenital lactic acidosis and Leigh disease. Determination of specific enzymes makes it possible to rule out Krabbe leukodystrophy and metachromatic leukodystrophy. Suspected cases of neonatal peroxisomal disorders must be worked up for peroxisomal structure and enzymes. Pelizaeus-Merzbacher disease is caused by defective biosynthesis of a CNS myelin-specific proteolipid protein for which a DNA probe has recently become available.

The main clinical presentation of Canavan disease is progressive infantile encephalopathy with clinical evidence of white-matter disease and macrocephaly. The latter feature can be absolute or relative as compared with other growth parameters. Canavan disease is not the only macrocephalic leukodystrophy; other conditions such as Alexander disease might manifest similarly. Because no biochemical defect or marker is known for Alexander disease, that diagnosis can be ascertained only by biopsy or autopsy.

Canavan disease should be considered when severe white-matter disease is seen, regardless of whether concomitant atrophic changes are present, even if the neurologic examination is normal.

## REFERENCES

1. Canavan M. Schilder's encephalitis periaxialis diffusa. *Arch Neurol Psychiatry* **1931**;25:299-308
2. Van Bogaert L, Bertrand I. Sur une idiotie familiale avec dégénérescence spongieuse du nevraxe (note préliminaire). *Acta Neurol Belg* **1949**;49:572-587
3. Buchanan DS, Davis RL. Spongy degeneration of the nervous system. A report of four cases with a review of the literature. *Neurology* **1965**;15:207-222
4. Boltshauser E, Wilson J. Value of brain biopsy in neurodegenerative disease in childhood. *Arch Dis Child* **1976**;51:264-268
5. Matalon R, Michals K, Sebesta D, Deanching M, Gashkoff P, Casanova J. Aspartoacylase deficiency and N-acetylaspartic aciduria in patients with Canavan's disease. *Am J Med Genet* **1988**;29:463-471
6. Hagenfeldt L, Bollgren I, Venizelos N. N-Acetylaspartic aciduria due to aspartoacylase deficiency—a new etiology of childhood leukodystrophy. *J Inherited Metab Dis* **1967**;10:135-141
7. Kvittingen EA, Guldal G, Borsting S, Skalpe IO, Stocke O, Jellum E. N-Acetylaspartic aciduria in a child with a progressive cerebral atrophy. *Clin Chim Acta* **1986**;158:217-227
8. Matalon R, Kaul R, Casanova J, et al. Aspartoacylase deficiency: the enzyme defect in Canavan disease. *J Inherited Metab Dis* **1989**;12[Suppl 2]:329-331
9. Miyake M, Morino H, Mizobuchi M, Kakimoto Y. N-Acetylaspartic acid, N-acetyl-alpha-L-aspartyl-L-glutamic acid, and beta-citryl-L-glutamic acid in human urine. *Clin Chim Acta* **1982**;120:119-126
10. Banker BQ, Victor M. Spongy degeneration in infancy. In: Goodman RM, Motulsky AG, eds. *Genetic diseases among Ashkenazi Jews*. New York: Raven, **1979**:201-217
11. Ungar M, Goodman RM. Spongy degeneration of the brain in Israel: a retrospective study. *Clin Genet* **1983**;23:23-29
12. Boltshauser E, Isler W. Computerised axial tomography in spongy degeneration. *Lancet* **1976**;1:1123
13. Boltshauser E, Speiss H, Isler W. Computed tomography in neurodegenerative disorders in childhood. *Neuroradiology* **1978**;16:41-43
14. Kendall BE, Claveria LE, Quiroga W. C.A.T. in leukodystrophy and neuronal degeneration. In: Du Boulay GH, Moseley IF, eds. *The first European seminar on computerized axial tomography in clinical practice*. Heidelberg: Springer, **1977**:191-201
15. Rushton AR, Shaywitz BA, Duncan CC, Geehr RB, Manuelidis EE. Computed tomography in the diagnosis of Canavan's disease. *Ann Neurol* **1981**;10:57-60
16. Andriola MR. Computed tomography in the diagnoses of Canavan's disease. *Ann Neurol* **1982**;11:323-324
17. Patel PJ, Kolawole TM, Mahdi AH, Wright EA. Sonographic and computed tomographic findings in Canavan's disease. *Br J Radiol* **1986**;59:1226-1228
18. Barnes DM, Enzmann DR. The evolution of white matter disease as seen on computed tomography. *Neuroradiology* **1981**;138:379-383
19. Lane B, Carrol BA, Pedley TA. Computerized cranial tomography in cerebral diseases of white matter. *Neurology* **1978**;28:534-544
20. Aubourg P, Diebler C. Adrenoleukodystrophy—its diverse CT appearances and an evolutive or phenotypic variant: the leukodystrophy without adrenal insufficiency. *Neuroradiology* **1982**;24:33-42
21. Brismar J, Brismar G, Coates R, Gascon G, Ozand P. Increased density of the thalamus on CT scans in patients with GM<sub>2</sub> gangliosidosis. *AJNR* **1990**;11:125-130