

Postoperative Cervical Pseudomeningocele

Pseudomeningoceles can occur after surgery as a consequence of an inadvertent tear of the dura mater and pia arachnoid or a lack of closure of the dura with resultant CSF leakage into the paraspinal tissues. Posterior cervical pseudomeningocele has been reported by a few authors [1–6] as a rare, delayed complication of decompressive laminectomy. We report a case of an anterior CSF leak detected 1 week after anterior cervical discectomy.

Case Report

A 45-year-old woman was transferred to our institution 1 week after C6–C7 anterior cervical discectomy. Physical examination showed right-sided Horner syndrome; multiple palpable soft neck masses, greater on the right than on the left; and Brown-Séquard syndrome. The last included weakness of the right upper and lower extremities and decreased sensation of the left upper and lower extremities. CT showed anterior water-density collections in the neck, more on the right than on the left (Fig. 1A). Metrizamide myelogram showed a large CSF collection in the soft tissues of the anterior part of the neck on the right side (Fig. 1B). Postmyelogram CT showed the CSF leak well (Figs. 1C and 1D). No cord compression was noted. No respiratory compromise was present, so the patient was treated conservatively by having her stay supine. After 3 months, follow-up CT no longer showed the pseudomeningocele.

Discussion

Spinal pseudomeningoceles are CSF-filled pouches that extend into the paraspinal tissues because of CSF leakage [1]. They occur after trauma or surgery as a consequence of a tear in the dura mater and pia arachnoid or because of a lack of closure of the dura during surgery. Pseudomeningoceles occur more frequently in the lumbar than in the cervical region.

Postoperative cervical pseudomeningocele, a rare complication of decompressive laminectomy for cervical spondylosis, trauma, or herniated nucleus pulposus, has been reported in nine cases [1–6]. The pseudomeningocele is usually posterior or posterolateral to the thecal sac [7]. The anterior location of the extravasated CSF in our case is a rarity; no case of pseudomeningocele after anterior cervical discectomy has been reported.

Although cervical meningoceles are not uncommon after surgical procedures in which the dura has been left open for decompression, most are asymptomatic [3, 4]. Pseudomeningoceles may, however,

cause signs and symptoms either by mass effect with compression of neural elements or by herniation of neural structures through the dura mater [1, 4]. The interval between trauma or laminectomy and discovery of the pseudomeningocele varies from a few months to many years because radiculomyelopathy is delayed [1, 5]. In our case, Brown-Séquard and Horner syndromes occurred within 1 week after surgery. Formation of a pseudomeningocele may be rapid and is a mechanical process [2, 8]. The size of the defect in the dura-arachnoid, the pressure of the spinal fluid, and the resistance of the soft tissue presumably determine the size of the pseudomeningocele, which was extensive in this case.

Some [2] have recommended that all patients with symptomatic postoperative cervical pseudomeningocele should have repeat surgery. Others [9] state that a pseudomeningocele will decrease spontaneously in size over a period of months unless a valvelike flap of tissue encourages the continued collection of CSF, in which case repeat surgery is the proper management. In our case, spontaneous resolution occurred within 3 months.

Sandra W. Horowitz
Behrooz Azar-Kia
Michael Fine
Loyola University Medical Center
Maywood, IL 60153

REFERENCES

1. Helle TL, Conley FK. Postoperative cervical pseudomeningocele as a cause of delayed myelopathy. *Neurosurgery* 1981;9:314–316
2. Maiuri F, Corriero G, Giamundo A, Donati P, Gambardella A. Postoperative cervical pseudomeningocele. *Neurochirurgia* 1988;31:29–31
3. Burres KP, Conley FK. Progressive neurological dysfunction secondary to postoperative cervical pseudomeningocele in a C-4 quadriplegic. *J Neurosurg* 1978;48:289–291
4. Cobb C, Ehni G. Herniation of the spinal cord into an iatrogenic meningocele. *J Neurosurg* 1973;39:533–536
5. Hanakita J, Kinuta Y, Suzuki T. Spinal cord compression due to postoperative cervical pseudomeningocele. *Neurosurgery* 1985;17:317–319
6. Goodman S, Gregorius FK. Cervical pseudomeningocele after laminectomy as a cause of progressive myelopathy. *Bull Los Angeles Neurol Soc* 1974;39:121–127
7. Kolawole TM, Patel PJ, Rahaman NU. Post-surgical anterior pseudomeningocele presenting as an abdominal mass. *Comput Radiol* 1987;11:237–240
8. Miller PR, Elder FW. Meningeal pseudocysts (meningocele spurium) following laminectomy. *J Bone Joint Surg [Am]* 1968;50-A:268–276
9. Youmans JR. *Neurological surgery*. Philadelphia: Saunders, 1981

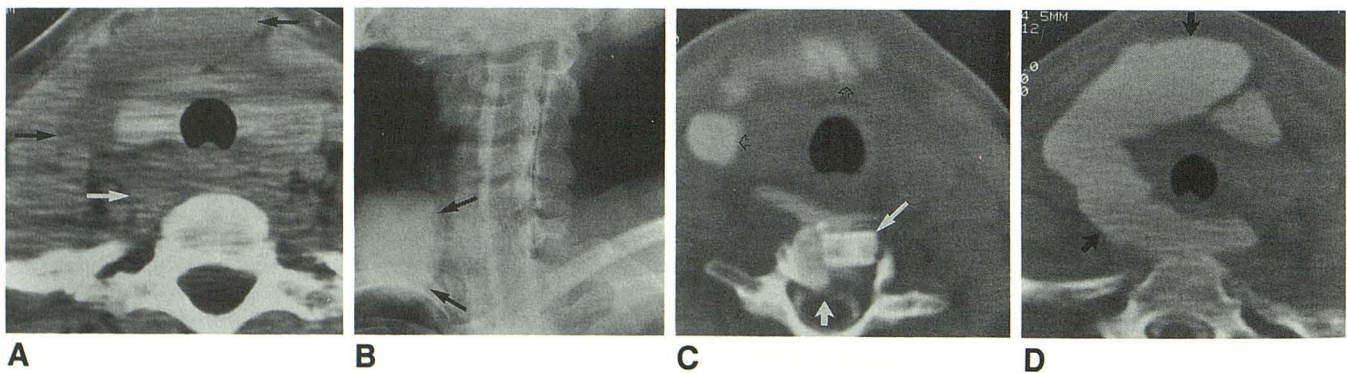


Fig. 1.—Postoperative cervical pseudomeningocele.
A, Axial CT scan at C7–T1 shows water-density collections (arrows) anterior, lateral, and posterior to thyroid gland, more on right than on left.
B, Oblique view of myelogram shows large anterior collection of CSF (arrows) in soft tissues of neck on right side.
C, Postmyelogram axial CT scan at C6–C7 shows right-sided ventral extradural defect on thecal sac (small solid arrow) from posterior vertebral body margin at level of bone graft (long arrow) and extravasation of CSF anteriorly on right side of neck (open arrows).
D, Postmyelogram axial CT scan at T1 sharply delineates extent of large CSF leak (arrows) anterior and posterior to thyroid gland and trachea.