

# MR Imaging of Optic Nerve Lesions: Value of Gadopentetate Dimeglumine and Fat-Suppression Technique

Lloyd E. Hendrix<sup>1</sup>  
 J. Bruce Kneeland<sup>1</sup>  
 Victor M. Haughton<sup>1</sup>  
 David L. Daniels<sup>1</sup>  
 Jerzy Szumowski<sup>2</sup>  
 Alan L. Williams<sup>1</sup>  
 Leighton P. Mark<sup>1</sup>  
 Leo F. Czervionke<sup>1</sup>

Eleven patients with known or suspected optic nerve lesions and eight normal subjects were examined with spin-echo technique at 1.5 T with unenhanced T1-weighted imaging, IV gadopentetate-dimeglumine-enhanced T1-weighted imaging, and enhanced T1-weighted imaging with fat suppression. Two pathologically proved and four presumed optic nerve meningiomas demonstrated significant enhancement and were best seen with the fat-suppression technique. None of the three presumed optic nerve gliomas nor the optic nerves of normal subjects demonstrated qualitative enhancement.

We conclude that the use of a fat-suppression technique with gadopentetate dimeglumine enhancement improves delineation of enhancing optic nerve lesions. This technique should be useful for evaluating other anatomic regions where enhancing tissue marginates fat.

*AJNR* 11:749-754, July/August 1990; *AJR* 155: October 1990

The T1 shortening effect of gadopentetate dimeglumine results in a significant increase in signal intensity of many lesions, such as meningiomas and acoustic neuromas, on short TR spin-echo (SE) images. This effect can increase the contrast between the lesion and surrounding tissues and result in improved detection of an abnormality [1-3]. However, in the orbit as well as other regions where the anatomic structure of interest is surrounded by fat, it may be difficult to distinguish between an enhanced structure and fatty tissue [4]. To overcome this problem we [5] and others [6] have previously suggested the use of fat-suppression sequences in conjunction with gadopentetate dimeglumine enhancement. A number of fat-suppression techniques for MR imaging have been previously introduced, including frequency-selective saturation pulses [7, 8], the STIR technique [9], Dixon's technique [10], and chopper fat suppression [11, 12]. We reasoned that such a fat-suppression technique should allow selective reduction of the fat signal intensity without affecting the signal intensity of the adjacent contrast-enhanced tissues. The purpose of this study was to determine if contrast-enhanced short TR SE imaging with a fat-suppression method would result in improved delineation and characterization of optic nerve/sheath lesions.

## Materials and Methods

Nineteen subjects, 18-76 years old, were examined with MR imaging at 1.5 T (Signa, General Electric Medical Systems, Milwaukee, WI). The eight control subjects consisted of four normal volunteers and four patients without known orbital disease. Eleven other patients were referred for known or suspected optic nerve lesions. The diagnosis was optic nerve sheath meningioma in six cases, optic nerve glioma in three cases (one patient with diagnosed neurofibromatosis), glial cyst with ectasia of the optic nerve sheath in one case, and sphenoid wing meningioma with orbital extension in one patient. These diagnoses were based on surgical and pathologic findings in four patients (two with optic nerve meningiomas, one with optic nerve sheath cyst, and one with sphenoid meningioma) and on a combination of CT, MR, and clinical findings in seven cases.

Received October 4, 1989; revision requested December 10, 1989; revision received January 31, 1990; accepted February 22, 1990.

This work was supported in part by NIH Grant No. 2 ROI NS-CA22913-04 RNM.

<sup>1</sup>Department of Radiology, Medical College of Wisconsin, Froedtert Memorial Lutheran Hospital, 9200 W. Wisconsin Ave., Milwaukee, WI 53226. Address reprint requests to L. E. Hendrix.

<sup>2</sup>Department of Radiology, Oregon Health Sciences University, Portland, OR 97201.

0195-6108/90/1104-0749

© American Society of Neuroradiology

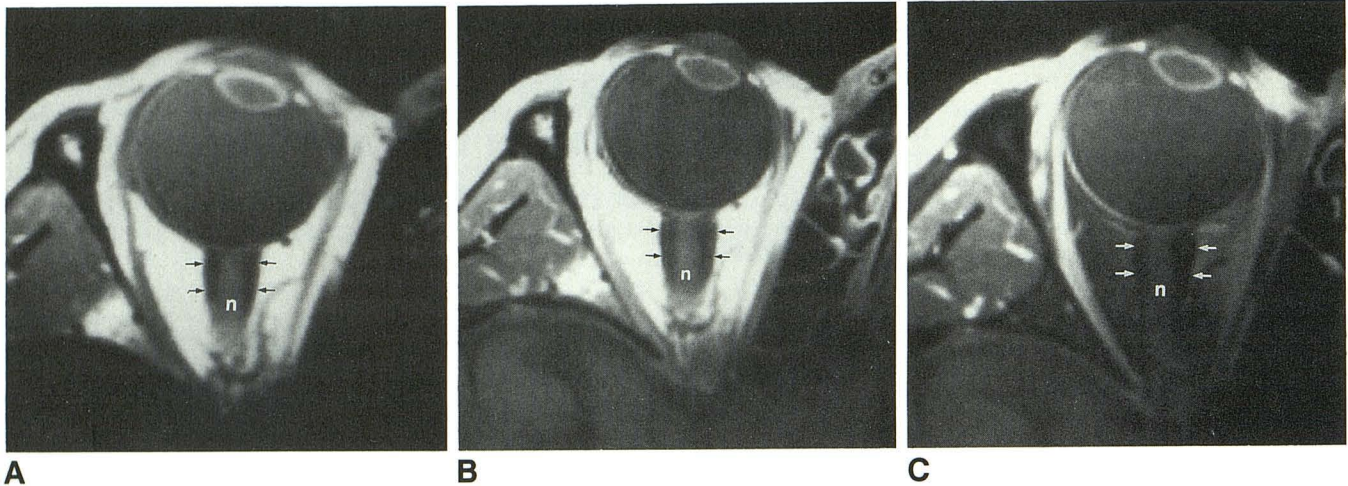


Fig. 1.—A–C, Axial T1-weighted spin-echo MR images of a normal orbit before IV injection of gadopentetate dimeglumine (A), after contrast injection (B), and with suppression after contrast injection (C). Fat suppression results in the low signal intensity of the intraconal fat in C. There is no appreciable enhancement of the optic nerve (n) or sheath (arrows) in B or C. Enhancement of the extraocular muscles, seen in the postcontrast images, is more apparent with the fat-suppression technique (C). This individual has a relatively prominent nerve sheath. The relatively increased brightness of soft tissue anterolaterally is a reflection of greater sensitivity of the reception field near the surface coil.

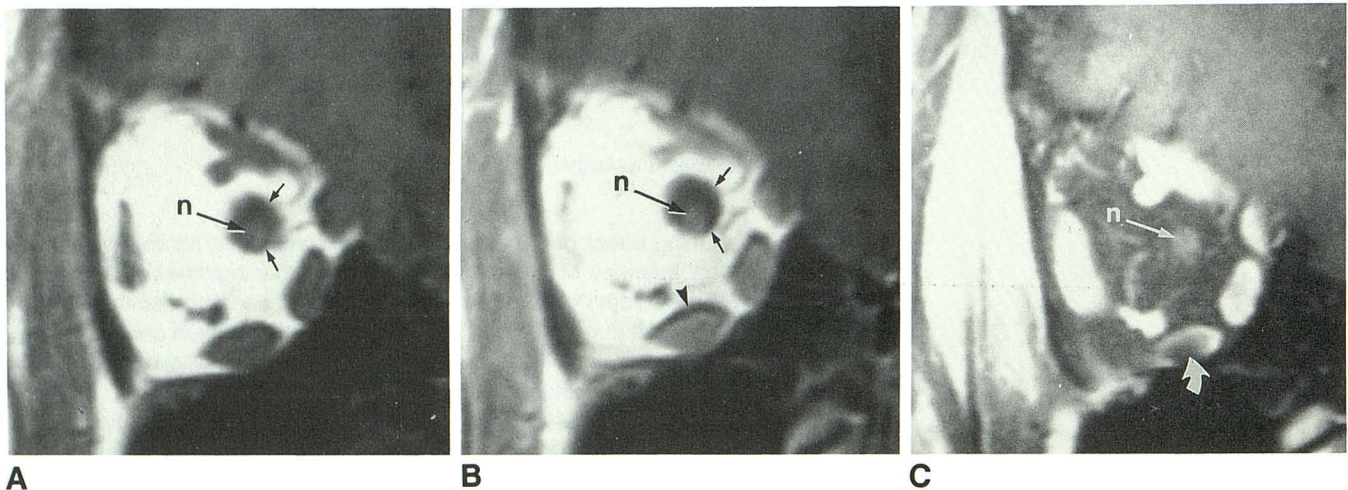


Fig. 2.—A–C, Coronal T1-weighted spin-echo MR images of a normal orbit before IV injection of gadopentetate dimeglumine (A) after contrast injection (B), and with fat suppression after contrast injection (C). In B, chemical-shift misregistration results in an artifactual black band (arrowhead) at superior margin of medial and inferior rectus muscles and increases prominence of the optic nerve sheath (arrows) superiorly. This effect is not evident with fat suppression (C). With fat suppression, in C, there is an artifactual signal void (curved arrow) within inferior rectus muscle, believed to be related to magnetic susceptibility differences between the muscle and air within the adjacent maxillary sinus. The increased signal intensity of the superior and inferior ophthalmic veins, seen in B and especially in C, is probably caused by T1 shortening of slow-flowing blood by gadopentetate dimeglumine. The enhancement is more obvious with fat suppression (C) owing to increased contrast between the vessels and surrounding fat. (n = optic nerve)

Fat suppression was accomplished with a frequency-selective presaturation pulse [8] in three subjects. In the remaining 16 subjects, fat suppression was done by using a hybrid technique that combines the 1331 sequence [13] used for solvent suppression in proton spectroscopy with the chopper fat-suppression sequence [11]. The 1331 sequence is a series of four pulses that is designed to avoid exciting the peak of interest (in this case water) while exciting the other components of the proton spectrum (the fat) with a 90° rotation. A spoiler gradient is then applied to dephase the magnetization. The chopper fat-suppression technique can be viewed as a real-time Dixon technique [10] in which the in-phase (water + fat) and opposed-phase (fat – water) signals are obtained in an interleaved fashion within the same sequence and subtracted to suppress the fat.

All patients with orbital disease were imaged with routine unenhanced T1-weighted (short TR/TE) SE imaging and gadopentetate-dimeglumine-enhanced T1-weighted SE imaging with and without fat suppression. Precontrast fat-suppression imaging was also performed in selected cases (four patients with meningioma, one with optic glioma, one with optic nerve sheath cyst, and three normal volunteers). Gadopentetate dimeglumine was injected IV in a dose of 0.1 mmol/kg body weight. Imaging was resumed within minutes after injection. Twelve of the subjects were examined with the use of a 7.5-cm-diameter receive-only surface coil (General Electric, Milwaukee); four of these subjects were also studied with the use of a head coil. Seven subjects were studied with only the head coil. Imaging parameters included 600/20 (TR/TE); slice thickness/gap = 3/1 mm;

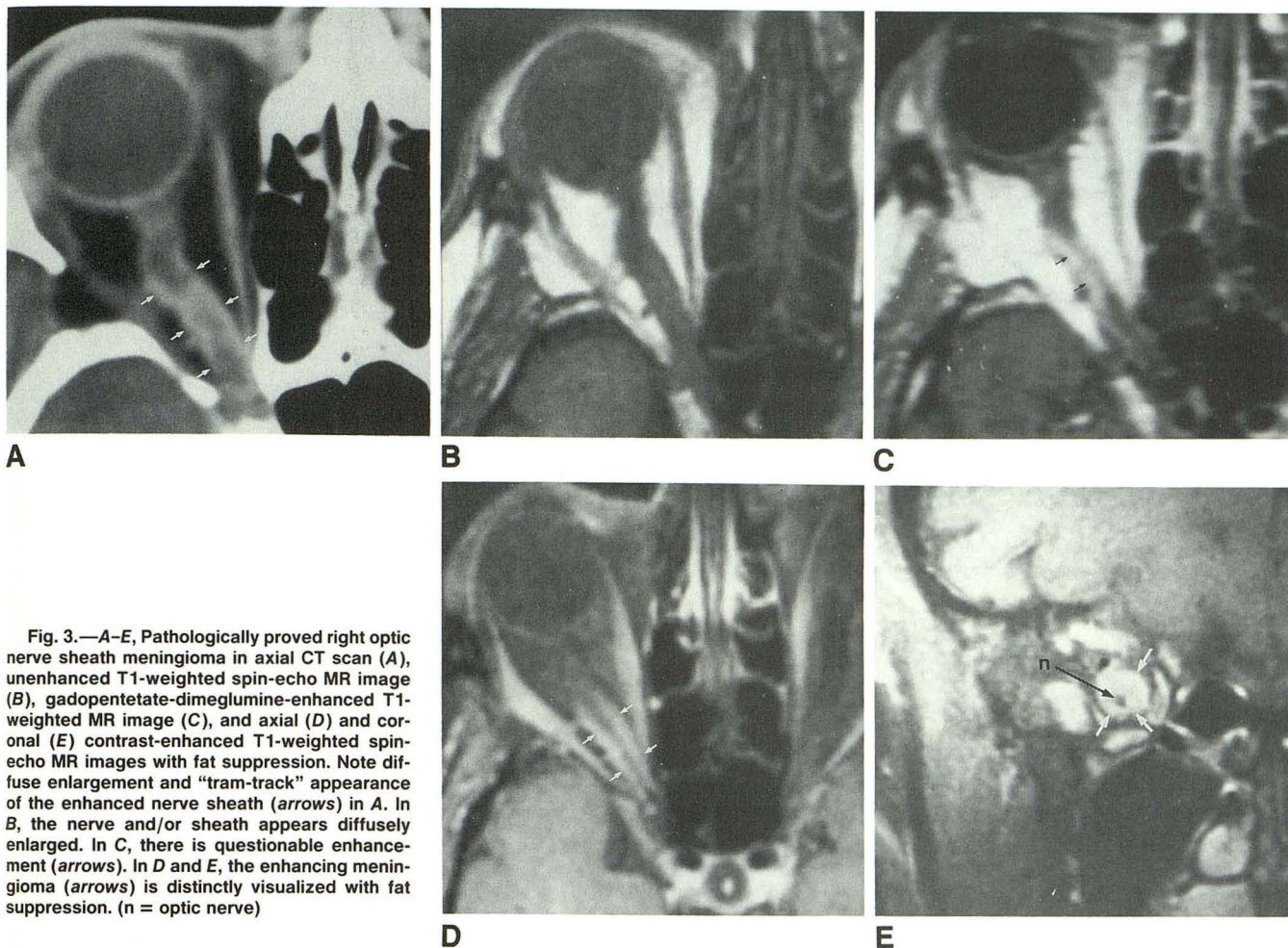


Fig. 3.—A–E, Pathologically proved right optic nerve sheath meningioma in axial CT scan (A), unenhanced T1-weighted spin-echo MR image (B), gadopentetate-dimeglumine-enhanced T1-weighted MR image (C), and axial (D) and coronal (E) contrast-enhanced T1-weighted spin-echo MR images with fat suppression. Note diffuse enlargement and “tram-track” appearance of the enhanced nerve sheath (arrows) in A. In B, the nerve and/or sheath appears diffusely enlarged. In C, there is questionable enhancement (arrows). In D and E, the enhancing meningioma (arrows) is distinctly visualized with fat suppression. (n = optic nerve)

14 or 20 cm field of view, depending on the use of the surface or head coil, respectively;  $256 \times 128$ , 192, or 256 acquisition matrix for axial images, and  $256 \times 128$  matrix for coronal images; and two excitations in all cases. Enhancement was evaluated qualitatively in all subjects. All MR images were evaluated in a retrospective, non-blinded fashion.

## Results

No appreciable enhancement of the optic nerve, nerve sheath, or orbital fat was observed in normal subjects (Figs. 1 and 2). All (six) optic nerve sheath meningiomas enhanced and were best seen with fat-suppression imaging after contrast administration (Figs. 3–5). In unenhanced images three meningiomas were not apparent, one was considered as a questionable abnormality (a small lesion next to the optic nerve near the orbital apex), one appeared as diffuse enlargement of the nerve, and the other as a focal, fusiform enlargement of the posterior portion of the nerve. After administration of gadopentetate dimeglumine, three of the lesions could be partially visualized and were thought to have enhanced slightly. With the addition of the fat-suppression sequence, all seven meningiomas were identifiable and appeared more

extensive than was apparent in images without fat suppression. Enhanced tumor surrounded the lower-intensity nerve in a concentric fashion (five of six) or was seen adjacent to it (one of six) (Fig. 5). The nerve sheath could often be seen as a uniformly thin line (axial plane) or ring (coronal plane) of high signal intensity surrounding the nerve even where there was no gross tumor or obvious thickening of the sheath.

Each of the three optic nerve gliomas presented as diffuse enlargement of the nerve on unenhanced MR images. The optic glioma signal intensity in each case was indistinguishable from that of normal nerve. In one patient the nerve sheath was diffusely thickened. Neither the optic nerve gliomas nor the glial cyst enhanced: after contrast administration there was no evident change in the appearance of the optic nerve or sheath with or without fat suppression (Fig. 6).

Fat suppression without gadopentetate dimeglumine, relative to routine SE imaging, did not improve visualization of optic nerve lesions in this series; contrast resolution of the lesions was not increased, and the images obtained in this fashion suffered from a slight qualitative decrease in signal-to-noise ratio.

Enhancement of the extraocular muscles was observed in all subjects (Figs. 1–6). This enhancement was especially

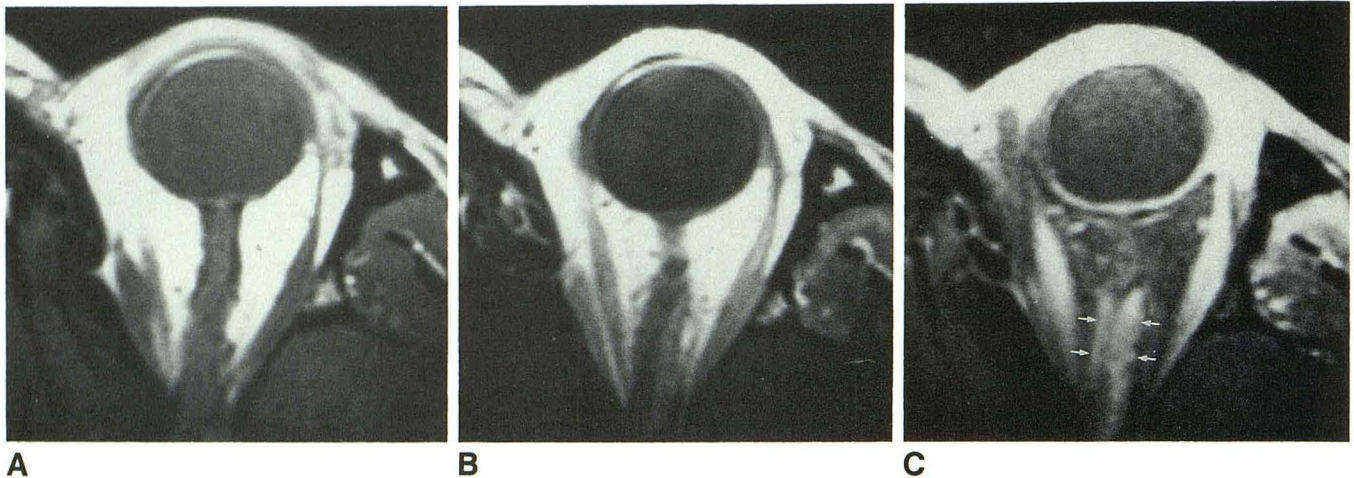


Fig. 4.—A–C, Axial T1-weighted spin-echo MR images of an optic nerve sheath meningioma before IV injection of gadopentetate dimeglumine (A), after contrast injection (B), and with fat suppression after contrast injection (C). The lesion was not appreciated in the unenhanced image (A). After IV contrast administration, a thin band of moderately enhancing tissue is seen posteriorly alongside lateral aspect of nerve (B). With fat suppression (C), tumor (arrows) is distinctly seen medial and lateral to the optic nerve. This patient was originally referred for suspected optic neuritis. A fundoscopic examination after MR imaging showed optociliary shunt vessels, and subsequent CT findings were most consistent with meningioma.

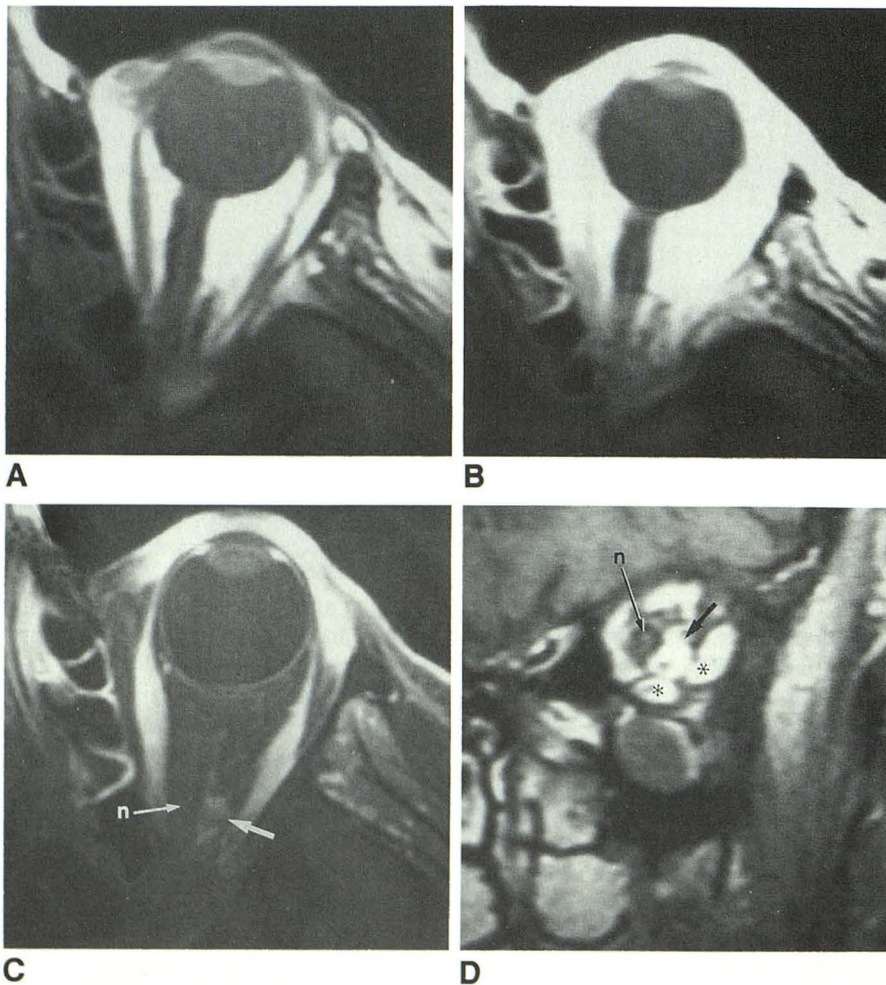


Fig. 5.—A–D, Axial (A–C) and coronal (D) T1-weighted spin-echo MR images of a small optic nerve sheath meningioma before IV injection of gadopentetate dimeglumine (A), after contrast administration (B), and with fat suppression after contrast administration (C and D). The lesion could be mistaken for normal vessels in A or B, but in C enhancing lesion (arrow) is clearly seen lateral to optic nerve (n), and in D it is seen as eccentric lesion (arrow) inferolateral to optic nerve in coronal plane. Lesion appears virtually isointense with extraocular muscles (asterisks in D). Fundoscopic examination and CT findings were most consistent with meningioma. (Case courtesy of Drs. Richard E. Appen and Joel Weinstein.)

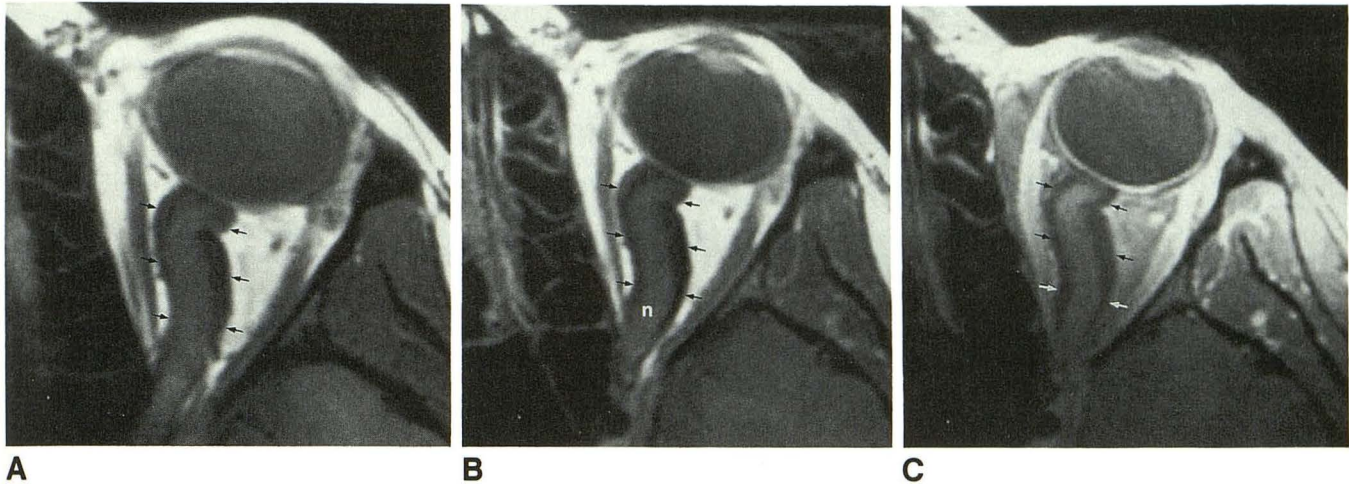


Fig. 6.—A–C, Axial T1-weighted spin-echo MR images of an optic nerve glioma before IV injection of gadopentetate dimeglumine (A), after contrast administration (B), and with fat suppression after contrast administration (C). No appreciable enhancement of the optic nerve (n) or sheath (arrows) is observed in either B or C. Thickening of the nerve sheath is probably due to arachnoid hyperplasia.

evident in the fat-suppressed images. The contrast-enhanced meningiomas appeared isointense (particularly in the coronal plane) or slightly hypointense relative to the muscles.

There was considerable reduction of the chemical-shift misregistration artifact with the fat-suppression sequence. However, an artifactual signal void within the inferior rectus muscle (probably caused by a difference in magnetic susceptibility between the muscle tissue and nearby air within the maxillary sinus) was consistently seen in one or two coronal fat-suppressed images in each subject (Fig. 2).

## Discussion

The hybrid sequence used in this study provides a straightforward, effective method of fat suppression that does not require an increase in acquisition time. However, certain parameters must be adjusted in an interactive fashion during a prescan, and improper adjustment can result in poor fat suppression. Additionally, both the 1331 sequence and the chopper sequence are dependent on good static field homogeneity for effective fat suppression.

Certain findings of this study deserve further comment. With gadopentetate dimeglumine enhancement and fat suppression, the appearance of meningiomas is analogous to that seen in CT studies [14–18]; a so-called “donut” configuration (five of six) or “tram-track” [17, 18] appearance (five of six) of the nerve surrounded by enhanced tumor was seen in coronal and axial views, respectively. As noted earlier (see Results), the contrast-enhanced meningiomas were essentially isointense with the extraocular muscles. This observation is relevant in that an eccentric meningioma may resemble an extraocular muscle in the coronal plane (Fig. 5).

The gliomas in this series were confined to the optic nerve and were typical of the more common benign, hamartomalike subset of these tumors [19, 20]. Consistent with previous observations [21], we found the signal intensity of these optic nerve gliomas to be indistinguishable from that of normal

nerve. The nerve sheath was diffusely thickened in one patient with an optic glioma. This phenomenon, caused by arachnoid hyperplasia, is known to occur in some cases of optic glioma and the appearance may resemble that of a meningioma [15, 19, 22, 23]. Significantly, unlike the meningiomas, the thickened sheath associated with the optic glioma did not enhance.

Advantages of fat suppression for orbital imaging have been described [12]. The fat-suppression sequence reduces the chemical-shift misregistration artifact [7, 12, 24, 25] and can increase the contrast between fat and high signal intensity lesions, such as uveal melanoma or subacute hemorrhage [12]. However, we did not find the fat-suppression sequence without gadopentetate dimeglumine to be beneficial in the evaluation of optic nerve lesions.

Pathologic verification was not obtained in all cases in this study. Three patients (one with known neurofibromatosis) had characteristic radiologic and clinical findings of optic nerve glioma; these lesions are not routinely biopsied or resected at our institution. Four patients with typical radiologic and clinical features of optic nerve sheath meningioma were not considered surgical candidates.

In summary, the technique of gadopentetate dimeglumine enhancement combined with fat suppression improves MR imaging of enhancing optic nerve lesions and may help to differentiate nerve sheath meningiomas from optic nerve gliomas. We believe that this technique is promising for the evaluation of other orbital lesions and should prove to be useful in studies of other anatomic regions. Further refinements in fat-suppression techniques will undoubtedly serve to increase the number of potential applications.

## ACKNOWLEDGMENTS

We thank Richard E. Appen and Joel Weinstein of the Department of Ophthalmology; Pat Turski of the Department of Radiology, University of Wisconsin, Madison; and R. Anne Papke for their assistance in the completion of this study.

## REFERENCES

1. Berry I, Brant-Zawadzki M, Osaki L, Brasch R, Murovic J, Newton TH. Gd-DTPA in clinical MR of the brain: 2. extraaxial lesions and normal structures. *AJNR* **1986**;7:789-793
2. Breger RK, Papke RA, Pojunas KW, Haughton VM, Williams AL, Daniels DL. Benign extraaxial tumors: contrast enhancement with Gd-DTPA. *Radiology* **1987**;163:427-429
3. Haughton VM, Rimm AA, Czervionke LF, et al. Sensitivity of Gd-DTPA-enhanced MR imaging of benign extraaxial tumors. *Radiology* **1988**;166:829-833
4. Sze G, Krol G, Zimmerman RD, Deck MDF. Malignant extradural spinal tumors: MR imaging with Gd-DTPA. *Radiology* **1988**;167:217-223
5. Hendrix LE, Mark LP, Czervionke LF, et al. MR characterization of optic nerve lesions with Gd-DTPA enhancement and "chopper" fat suppression technique (abstr). *Radiology* **1988**;169(P):145
6. Simon JH, Szumowski J. Chemical shift imaging with paramagnetic contrast material enhancement for improved lesion depiction. *Radiology* **1989**;171:539-543
7. Frahm J, Haase A, Hanicke W, Matthaei D, Bomsdorf H, Helzel T. Chemical shift selective MR imaging using a whole-body magnet. *Radiology* **1985**;156:441-444
8. Rosen BR, Wedeen VJ, Brady TJ. Selective saturation NMR imaging. *J Comput Assist Tomogr* **1984**;8:813-818
9. Bydder GM, Young IR. MR imaging: use of the inversion recovery sequence. *J Comput Assist Tomogr* **1985**;9:659-675
10. Dixon WT. Simple proton spectroscopic imaging. *Radiology* **1984**;153:189-194
11. Szumowski J, Plewes DB. Separation of lipid and water MR imaging signals by chopper averaging in the time domain. *Radiology* **1987**;165:247-250
12. Simon J, Szumowski J, Totterman S, et al. Fat-suppression MR imaging of the orbit. *AJNR* **1988**;9:961-968
13. Hore PJ. Solvent suppression in fourier transform nuclear magnetic resonance. *J Magn Reson* **1983**;55:283-300
14. Swenson SA, Forbes GS, Younge BR, Cambell RJ. Radiologic evaluation of tumors of the optic nerve. *AJNR* **1982**;3:319-326
15. Jakobiec FA, Depot MJ, Kennerdell JS, et al. Combined clinical and computed tomographic diagnosis of orbital glioma and meningioma. *Ophthalmology* **1984**;91:137-155
16. Daniels DL, Williams AL, Syvertsen A, Gager WE, Harris GJ. CT recognition of optic nerve sheath meningioma: abnormal sheath visualization. *AJNR* **1982**;3:181-183
17. Peyster RG, Hoover ED, Hershey BL, Haskin ME. High-resolution CT of lesions of the optic nerve. *AJNR* **1983**;4:169-174
18. Johns TT, Citrin CM, Black J, Sherman JL. CT evaluation of perineural orbital lesions: evaluation of the "tram-track" sign. *AJNR* **1984**;5:587-590
19. Marquardt MD, Zimmerman LE. Histopathology of meningiomas and gliomas of the optic nerve. *Hum Pathol* **1982**;13:226-235
20. Russell DS, Rubinstein LJ. Tumours of specialized tissues of central neuroepithelial origin. In: *Pathology of tumours of the nervous system*, 5th ed., Baltimore: William & Wilkins, **1989**:370-376
21. Holman RE, Grimson BS, Drayer BP, Buckley EG, Brennan MW. Magnetic resonance imaging of optic gliomas. *Am J Ophthalmol* **1985**;100:596-601
22. Tumors of the eye, lids and orbita in children. In: Harley RD, ed. *Pediatric ophthalmology*, 2nd ed. Philadelphia: Saunders, **1983**:1259-1262
23. Cooling RJ, Wright JE. Arachnoid hyperplasia in optic nerve glioma: confusion with orbital meningioma. *Br J Ophthalmol* **1979**;63:596-599
24. Daniels DL, Kneeland JB, Shimakawa AJ, et al. MR imaging of the optic nerve and sheath: correcting for the chemical shift misregistration effect. *AJNR* **1986**;7:249-253
25. Atlas SW, Grossman RI, Axel L, et al. Orbital lesions: proton spectroscopic phase-dependent contrast MR imaging. *Radiology* **1987**;164:510-514