

# Xe/CT Cerebral Blood Flow Evaluation of Delayed Symptomatic Cerebral Ischemia after Subarachnoid Hemorrhage

Melanie B. Fukui,<sup>1</sup> David W. Johnson,<sup>1</sup> Howard Yonas,<sup>2</sup> Laligam Sekhar,<sup>2</sup> Richard E. Latchaw,<sup>3</sup> and Susan Pentheny<sup>1</sup>

**Purpose:** We examined the xenon/CT method of measuring cerebral blood flow in assessing the location, pattern of onset, and severity of delayed cerebral ischemia. **Patients and Methods:** Fourteen patients with delayed neurologic deficits due to ischemia were selected from a group of 66 patients with subarachnoid hemorrhage. All blood flow studies were performed within 12 hours of deterioration and at regular intervals during medical management. **Results:** In 10 of the 14 patients, noncontrast CT did not identify a cause for deterioration, whereas the blood flow study revealed diminished flow values. Location of blood flow reduction was variable. In five of the 14 patients, blood flow reduction was closely related anatomically to the vessel of aneurysm origin. In another three, blood flow reduction was anatomically remote to the vessel of origin. The remaining six experienced local and remote cerebral blood flow reduction. Six of 14 patients suffered sudden, devastating deterioration, refractory to therapy and associated with blood flow of 15 cc/100 g·min or less, resulting in local or widespread infarction. The remaining eight had less severe blood flow reduction and did not infarct those territories. **Conclusions:** Vasospasm can affect remote vessels as severely as local vessels and can affect remote vessels alone. Diminished cerebral blood flow correlated closely with clinical vasospasm in this group of patients. Xenon/CT cerebral blood flow studies can identify tissue at risk of infarction when CT is normal.

**Index terms:** Cerebral blood flow; Computed tomography, xenon study; Brain, ischemia; Aneurysm, cerebral

AJNR 13:265-270, January/February 1992

Delayed cerebral ischemia due to vasospasm is one of the most devastating sequelae of subarachnoid hemorrhage (SAH) secondary to ruptured aneurysms. Usually, diagnosis of symptomatic vasospasm following SAH has been made by patient history and physical exam with computed tomography (CT) and/or angiographic confirmation. The findings of headache, fever, elevated white blood cell count, and delayed neurologic deficit are helpful, but not specific, for vasospasm.

Although angiography is considered to be the standard for diagnosing vasospasm, it is associated with a high rate of morbidity after SAH (1). Many authors have suggested the use of noninvasive cerebral blood flow (CBF) studies to measure tissue perfusion as an alternative to angiography in the diagnosis and management of vasospasm (2-4). In fact, noninvasive CBF studies have proved useful in identifying patients with initially reduced CBF values, who, despite good clinical grade, are at risk for developing vasospasm (4, 5).

We have used the xenon/CT (Xe/CT) CBF method because of its accessibility, capacity for direct anatomic correlation, and sensitivity in detecting CBF values near zero. Xe/CT CBF studies have provided useful information in the evaluation of delayed cerebral ischemia by identifying tissue at risk for infarction.

## Methods

Fourteen patients with delayed neurologic deficits were selected from a group of 66 patients with SAH due to

---

Received May 25, 1990; revision requested September 3, 1990; revision received June 5, 1991; final acceptance June 24, 1991.

<sup>1</sup> Address reprint requests to D. W. Johnson, Department of Radiology, University of Pittsburgh, Presbyterian-University Hospital, DeSoto & O'Hara Streets, Pittsburgh, PA 15213.

<sup>2</sup> Department of Neurosurgery, University of Pittsburgh, Presbyterian-University Hospital, Pittsburgh, PA 15213.

<sup>3</sup> University of Minnesota Hospital, Department of Radiology, Box 292, Harvard St, East River Road, Minneapolis, MN 55455.

AJNR 13:265-270, Jan/Feb 1992 0195-6108/92/1301-0265

© American Society of Neuroradiology



aneurysm rupture. The 52 remaining patients were asymptomatic and had normal Xe/CT CBF studies. No electrolyte imbalance, evidence of hydrocephalus, or rebleeding was detected coincident with the onset of neurologic deficit. Patients were graded according to the Hunt and Hess classification (6). Xe/CT CBF studies, along with CT imaging, were performed on all 14 patients within 12 hours of delayed neurologic deficit. Those treated with medical therapy were also scanned 4–6 days and 8–10 days after SAH.

Xe/CT CBF studies were performed on a GE 9800 CT scanner equipped with an integrated hardware and software system for measurement and calculation of CBF (GE Medical Systems, Milwaukee, WI). Patients were connected to a gas delivery system that supplies a 33% xenon/67% oxygen mixture. Two baseline scans were obtained at each level of study before xenon delivery. Four to six enhanced images were obtained during the first 4.5 minutes of xenon inhalation. A more detailed description of the method has previously been reported (7). CBF data were quantified by placing multiple 2-cm diameter or greater regions of interest over the cerebral cortex.

## Results

The onset of symptoms of delayed ischemia due to vasospasm was typical, and ranged from 3–10 days post hemorrhage (Table 1). In 10 of 14 patients with delayed neurologic deficits, CT did not identify a cause for deterioration; however, CBF studies revealed diminished flow values that corresponded to the clinical deficits. In the remaining four patients, CT revealed infarcts, and the concurrent CBF studies showed significantly larger areas of compromised blood flow.

The distribution of ischemia varied. In five patients, reduction of CBF was anatomically closely related to the vessel of origin, which we termed local. In three patients, the reduction of CBF was anatomically unrelated to the vessel of origin, which we termed remote. The CBF studies of six patients demonstrated both local and remote reductions in CBF. The distribution of aneurysm origin is listed in Table 1. There was no clear difference in outcome based on the distribution of cerebral ischemia.

Six patients suffered sudden, devastating neurologic deterioration that was refractory to hyperventilatory therapy. Initial CBF values after the onset of symptoms of less than 15 cc/100 g·min, often near zero, were measured in these patients and were accompanied by local or global infarction on CT. The remaining eight patients had less severe reductions in CBF and responded to therapy with increased CBF and no CT-defined infarction.

## Cases

### *Patient 4: Local Vasospasm*

A 24-year-old man presented five days after the initial SAH and 1 day after rebleeding from a ruptured anterior communicating artery aneurysm. The initial CT showed a minimal amount of blood in the cistern of the lamina terminalis and the frontal interhemispheric cistern. Twenty-four hours after operation for aneurysm clipping, the patient rapidly developed left-sided weakness,

TABLE 1: Correlation of Xe/CT CBF findings with CT and clinical signs

Patient Number	Age/Sex	Aneurysm Site	Outcome	Site of Lowest CBF	Lowest CBF Values	Clinical Grade on Admission	Deficit	Onset of Deficit (days after SAH)
1	42/F	R P-Comm	Discharged w/o deficit	R ACA/PCA L ACA/MCA/PCA	33	II	Transient R drift	8
2	69/F	R P-Comm	Rehab	R,L ACA/MCA/PCA	20	I-IV	L hemiparesis	3
3	71/F	L MCA	Infarct	L MCA	18	III	Lethargy	4
4	24/M	A-Comm	Infarct	R ACA	5	I-II	L hemiparesis	6
5	56/F	A-Comm	Death	R PCA, L MCA/PCA	17	II		7
6	40/F	Basilar	Death	R,L ACA	10	III	Lethargic	6
7	59/F	A-Comm	Death	R,L ACA	0	IV	Unresponsive	7
8	46/F	R MCA	Death	R,L ACA/MCA/PCA	30	III	L hemiparesis	6
9	46/M	A-Comm	Death	R,L ACA/MCA	10	I-II	R hemiparesis	6
10	47/F	R ICA	Death	R ACA/MCA	9	II	L hemiplegia	4
11	61/F	R MCA	Discharged w/deficit	L MCA	15	IV	L hemiparesis	10
12	86/F	L P-Comm	Death	L MCA	8	IV	R hemiparesis	8
13	69/F	L P-Comm	Aphasic	R,L ACA/MCA/PCA	20	IV	Aphasia	3
14	43/F	A-Comm	Death	Bilateral ACA/MCA/PCA	21	V	Pupils fixed, decorticate	7

Note.—R, right; L, left; P-Comm, posterior communicating artery; A-Comm, anterior communicating; ACA, anterior cerebral artery; MCA, middle cerebral artery; PCA, posterior cerebral artery; w/o, without; w, with.



leg greater than arm. A CBF study showed decreased flow values in both anterior cerebral artery (ACA) territories: 5 cc/100 g·min on the right and 20 cc/100 g·min on the left (Figs. 1A and 1B). With pressors and volume expansion, the patient's neurologic course stabilized. A repeat CBF study showed improved blood flow (30 cc/100 g·min) in the left ACA territory, and persistence of flow values near zero on the right, corresponding to a right ACA infarct on CT (Figs. 1C and 1D).

#### Patient 9: Local and Remote Vasospasm

A 46-year-old man was grade 1 on transfer to our hospital, three days after SAH from a ruptured ACA aneurysm. CT performed on day 1 showed a large amount of subarachnoid blood at the base of the brain and over the convexities; this had resolved by the first CBF study performed on day 3. The study showed diminished blood flow values in the arterial border zones, and near normal flows in the sylvian regions of the brain (Figs. 2A and 2B).

The following day, the patient suddenly became comatose. Although CT did not show infarct or new hemorrhage, a second CBF study showed severely decreased flow values (less than 15 cc/100 g·min) in the ACA and middle cerebral artery (MCA) territories bilaterally (Figs. 2C and 2D). The patient died within 24 hours.

#### Patient 6: Remote Vasospasm

A 40-year-old woman was transferred to our hospital five days after SAH from a ruptured basilar tip aneurysm. She presented with frontal lobe dysfunction and severe hypertension (blood pressure, 190/120). CT showed a minimal amount of blood in the ventricles and the interpeduncular fossa. The initial CBF study showed diminished flow values in the frontal lobes (20 cc/100 g·min) (Fig. 3A). Normal flows were noted in the thalamus, basal ganglia, and calcarine cortex.

Five days later, she became oriented and her blood pressure returned to normal spontaneously. A second CBF study revealed markedly elevated flow values diffusely (greater than 70 cc/100 g·min), including the previously ischemic frontal lobes (Fig. 3B). Within hours of the onset of hyperemic flows, the patient rebleed and died.

#### Discussion

When hyponatremia, hydrocephalus, and rebleeding have been excluded as causes for delayed neurologic deterioration after SAH, ischemia due to vasospasm is implicated (8). The demonstration by angiography of narrowed blood vessels has been the standard for diagnosing vasospasm, but it is not a good predictor of clinical outcome. Although vasospasm is seen on approximately 30%–40% of arteriograms 4–12

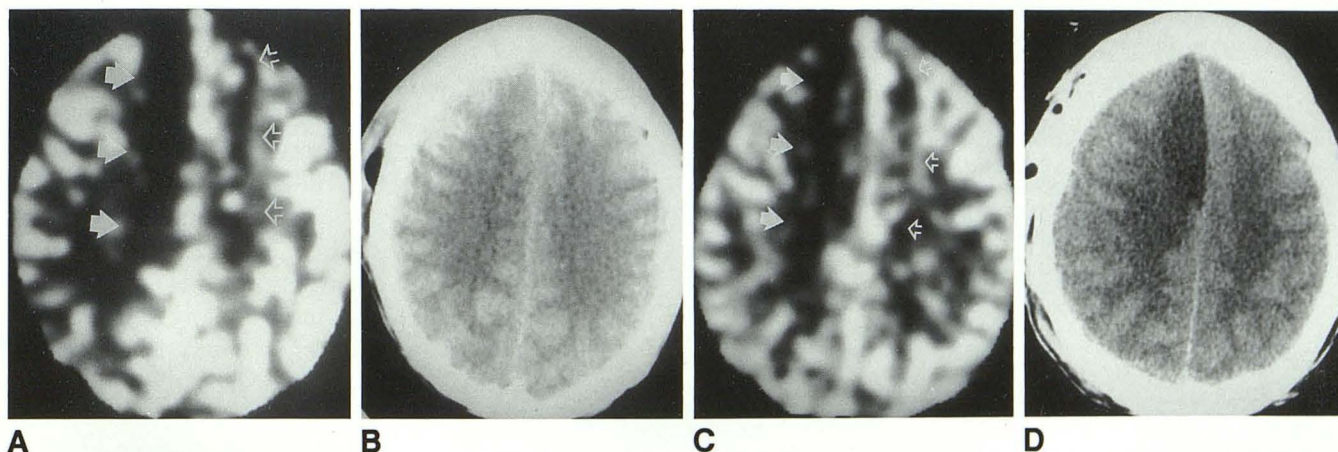


Fig. 1. Patient 4: local vasospasm; anterior communicating artery aneurysm.

A, Six days post SAH Xe/CT CBF study shows decreased blood flow in both ACA territories: 5 cc/100 g·min on the right (solid arrows) and 20 cc/100 g·min on the left (open arrows).

B, The accompanying CT scan shows normal brain parenchyma.

C, Three days later (9 days post SAH), and after hypertension and hemodilution therapy, a repeat CBF study shows improved blood flow in the left ACA territory (30 cc/100 g·min) (open arrows) and persistent low blood flow (5 cc/100 g·min) on the right (solid arrows).

D, CT shows the corresponding infarct in the right ACA territory.



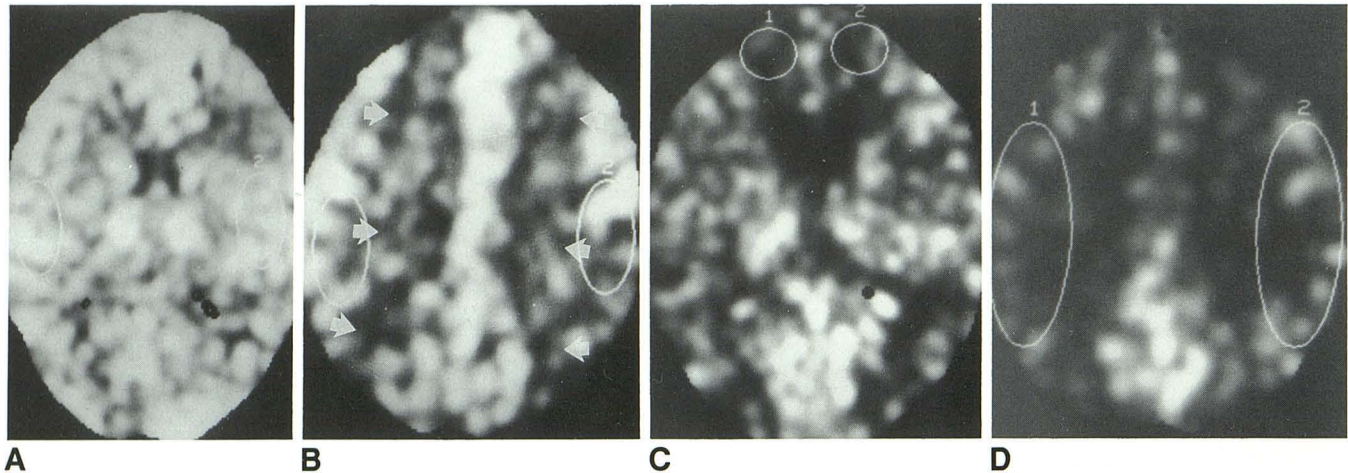


Fig. 2. Patient 9: local and remote vasospasm; anterior communicating artery aneurysm.

*A* and *B*, Six days post SAH. Global CBF within the slice was 60 cc/100 g·min. CBF in both region of interest (ROI) cursors in the sylvian regions was 60 cc/100 g·min. Note diminished flow values in the arterial border zones at the convexity (*arrows*).

*C* and *D*, Seven days post SAH. The patient suddenly became comatose. CBF was 10 cc/100 g·min in the ACA (marked by ROIs), 20 cc/100 g·min in the MCA territories, and 40 cc/100 g·min in the PCA territories. CBF in the MCA territories marked by the ROIs (CT was normal) is below 10 cc/100 g·min.

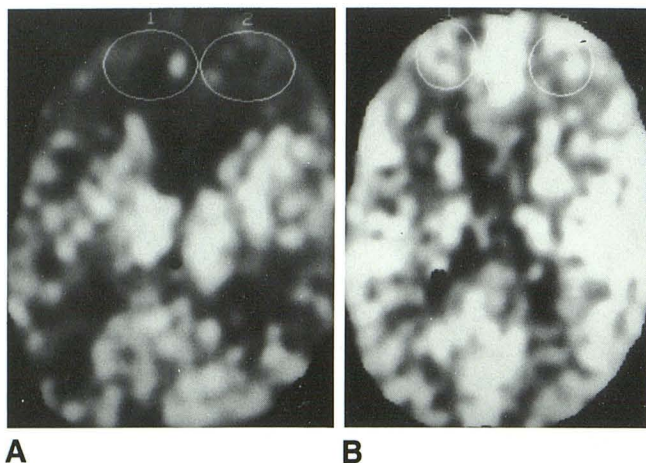


Fig. 3. Patient 6: remote vasospasm; basilar tip aneurysm.

*A*, Initial CBF study 6 days after SAH, shows severely diminished blood flow in the frontal lobes (20 cc/100 g·min) (marked by ROIs).

*B*, Five days later, CBF was 20 cc/100 g·min in ROI 1, 60 cc/100 g·min in ROI 2 and 46 cc/100 g·min in ROI 3. Global CBF within the slice is elevated above 70 cc/100 g·min.

days after SAH (9–12), only 20%–30% of patients experience delayed neurologic deterioration (13–16). Schneck and Kricheff reported a poor correlation between angiographic vasospasm and cerebral infarction after SAH (17). Angiographic vasospasm does not reliably predict clinically significant ischemia. Other investigators have reported that angiographic arterial narrowing is limited to the major vascular territory corresponding to the aneurysm origin (3, 13). These observations may be explained by the fact that angiog-

raphy demonstrates the major basal and cortical arteries only, and cannot detect small vessel narrowing. Since there must be at least 80% narrowing of the vessel lumen (18) before the distal circulation is affected, focal ischemia and infarcts do not consistently follow angiographic vasospasm (19). Global reductions in CBF measured with Xe<sup>133</sup> correlated poorly with the distribution of arterial narrowing by angiography (20); this is further evidence of the limited scope of angiography in the evaluation of ischemia. The discrepancy between angiographic findings and clinical signs of ischemia, coupled with a report of the high degree of variability in the interpretation of angiographic vasospasm (21), suggests that angiography is unreliable and not the best technique for the diagnosis of clinically significant vasospasm. Although the cause of vasospasm is not well understood, the risk of secondary ischemia leading to infarction is undisputed.

The Xe/CT technique for measuring CBF provides a noninvasive method to evaluate ischemia. Some investigators have reported poor correlation between diminished CBF and neurologic deficits (19), while others have measured diminished CBF in clinically affected territories (22, 23). In our group of patients, CBF of 20 cc/100 g·min or less correlated closely with neurologic deficits. These results confirm those that Powers et al obtained using positron emission tomography (PET) (24). Although CT alone has been used to correlate acute focal hemorrhage with vasospasm



(13), delayed ischemia may occur in the absence of CT-defined hemorrhage. In 10 of 14 cases in our series with delayed neurologic deficits and dramatic reduction of CBF, CT scans were normal at the time of symptoms. We found Xe/CT was more sensitive than CT alone in detecting foci of ischemia that corresponded to neurologic deficits.

Despite the advantages of Xe/CT in the evaluation of symptomatic vasospasm, there are limitations. The disadvantages of radiation dose and pharmacologic effects of xenon have been discussed previously (7) and are considered to be acceptable in the risk benefit analysis. The most important pharmacologic effects of xenon, including respiratory depression and bronchospasm, have occasionally resulted in termination of the study, but no deaths have been reported. Giller et al reported alteration in cerebral blood velocity associated with xenon inhalation (25). They believed this could impair the ability of the Xe/CT technique to measure CBF reliably. Although a rise in cerebral blood velocity could compromise the accuracy of Xe/CT CBF measurement, other studies have indicated that because this activation of CBF occurs only after 2 minutes, it has an insignificant impact on the calculated CBF (26, 27).

The work of Fisher et al showing the proximity of vasospasm to retained subarachnoid hematoma by CT (13) reflects the current thinking that clinical vasospasm is most severe at the vessel of aneurysm origin and is proportional to the extent of SAH. In our series, delayed cerebral ischemia was variable in distribution. In 11 of 14 patients, reduction of CBF occurred in the territory of the vessel of aneurysm origin, although six of these 11 patients had additional areas of reduced CBF remote from the vessel of origin. Three patients experienced remote ischemia exclusively. This challenges the concept that vasospasm is related to or caused by focal hematoma. The observation that delayed cerebral ischemia can occur remote from the vessel of aneurysm origin suggests that CT alone is not an adequate predictor of location/severity of vasospasm.

Delayed ischemia typically is gradual in onset and responsive to hypervolemic therapy; however, we observed a high degree of variability in the time course and severity of CBF reduction. Eight patients experienced gradual reduction in CBF (20–25 cc/100 g·min), with mild to moderate neurologic impairment that responded to therapy without CT-defined infarction. These results are similar to those of Symon (28). Six

patients, however, suffered sudden, devastating deterioration with an abrupt reduction in CBF to 15 cc/100 g·min or less, resulting in local or global infarction that was unresponsive to therapy. In addition to a correlation between symptoms and low CBF, a positive correlation between CBF of 15 cc/100 g·min or less and infarction has also been observed by Powers et al using PET (24). The rapid onset of severe vasospasm refractory to medical therapy, however, has been described as very unusual (29). Although the high frequency with which rapid deterioration was observed in our series may be due, in part, to the small patient population, the important benefit of CBF measurement is the potential to identify patients who may not improve with therapy.

Some have suggested that delayed cerebral ischemia after SAH might be due to diminished metabolism (18) or small vessel spasm undetected by angiography (5). Knuckey et al stated that narrowing of high-resistance arterioles might explain diminished CBF that is not attributable to large vessel narrowing (5). The possible roles of arteriolar narrowing and altered metabolism might account for the distribution and severity of ischemia in our series. Although it would be ideal to obtain data on CBF and cerebral metabolism on aneurysm patients, PET data suggest that local CBF alone can predict irreversible ischemia in patients with vasospasm (24).

Our results confirm the complexity of delayed cerebral ischemia and suggest that alternate theories must be invoked to explain cases of remote ischemia. Current theories for the pathogenesis of vasospasm include chemical factors, such as prostaglandins (30, 31), catecholamines (32, 33), serotonin (31, 32, 34), and angiotensin (35); mechanical factors, such as stretching of arachnoid fibers, "chordae" (36); and morphologic changes in vessels, such as myonecrosis (37). None of these theories, with the exception of the mechanical theory of Arutiunov et al (36), precludes the possibility of ischemia occurring remote from the vessel of origin.

Medical treatment for vasospasm includes hemodilution and hypertensive therapy to improve blood rheology and remains the initial treatment for vasospasm. With recent advances in the use of angioplasty in the treatment of vasospasm, Xe/CT may prove to be a useful tool in making management decisions. Early reports of the use of angioplasty in the treatment of vasospasm suggest high success rates ranging from 71% to 75% (38, 39).



Clinical vasospasm is a poorly understood disease. Our series demonstrates that both the vessel of origin and remote vessels can be equally and severely affected. One or more vascular territories can be devastated early and rapidly progress to infarction despite aggressive medical therapy. Local and remote vascular territories may be less severely affected, revealing a marginal CBF above the minimum (15 cc/100 g·min) for tissue viability, but not precluding a normal CT scan.

## References

1. Nibbelink DW, Torner J, Henderson WG. Intracranial aneurysm and subarachnoid hemorrhage: report on a randomized treatment study. *Stroke* 1977;8:202-218
2. Rosenstein J, Suzuki M, Symon L, Redmond S. Clinical use of a portable bedside CBF machine in the management of aneurysmal subarachnoid hemorrhage. *Neurosurgery* 1984;15:519-525
3. Mickey B, Vorstrup S, Voldby B, Lindewald H, Harmsen A, Larsen NA. Serial measurement of regional CBF in patients with subarachnoid hemorrhage using  $^{133}\text{Xe}$  inhalation and emission computerized tomography. *J Neurosurg* 1984;60:916-922
4. Ferguson GG, Farrar JK, Meguro K, Peerless SJ, Drake CG, Barnett HJM. Serial measurements of CBF as a guide to surgery in patients with ruptured intracranial aneurysms. *J Cereb Blood Flow Metab* 1981;1:S518-S519
5. Knuckey NW, Fox RA, Surveyor I, Strokes BAR. Early CBF and computerized tomography in predicting ischemia after cerebral aneurysm rupture. *J Neurosurg* 1985;62:850-855
6. Hunt WE, Hess RM. Surgical risk as related to time of intervention in the repair of intracranial aneurysms. *J Neurosurg* 1968;28:14-20
7. Johnson DW, Stringer WA, Marks MA, Yonas H, Good WF, Gur D. Stable xenon/CT cerebral blood flow imaging: rationale for and role in clinical decision making. *AJNR* 1991;12:201-213
8. Peerless SJ. Pre- and postoperative management of cerebral aneurysms. *Clin Neurosurg* 1979;26:209-301
9. Allcock JM, Drake CG. Ruptured intracranial aneurysms: the role of arterial spasm. *J Neurosurg* 1965;22:21-29
10. Fletcher TM, Taveras JM, Pool JL. Cerebral vasospasm in angiography for intracranial aneurysms: incidence and significance in 100 consecutive angiograms. *Arch Neurol* 1959;1:38-47
11. Graf CJ, Nibbelink DW. Cooperative study of intracranial aneurysms and subarachnoid hemorrhage. *Stroke* 1974;5:559-601
12. Weir B, Grace M, Hansen J, Rothberg C. Time course of vasospasm in man. *J Neurosurg* 1978;48:173-178
13. Fisher CM, Kistler JP, Davis JM. Relation of cerebral vasospasm to subarachnoid hemorrhage visualized by computerized tomographic scanning. *Neurosurgery* 1980;6:1-9
14. Heros RC, Zervas NT, Negoro M. Cerebral vasospasm. *Surg Neurol* 1976;5:354-362
15. Nibbelink DW, Torner JC, Henderson WG. Intracranial aneurysms and subarachnoid hemorrhage: a cooperative study. *Stroke* 1975;6:622-629
16. Sundt TM, Kobayashi S, Fode NC, Whisnant JP. Results and complications of surgical management of 809 intracranial aneurysms in 722 cases. *J Neurosurg* 1982;56:753-765
17. Schneck SA, Kricheff II. Intracranial aneurysm rupture, vasospasm and infarction. *Arch Neurol* 1964;11:668-680
18. Grubb RJ Jr, Raichle ME, Eichling JO, Gado MH. Effects of subarachnoid hemorrhage on cerebral blood volume, blood flow, and oxygen utilization in humans. *J Neurosurg* 1977;46:446-453
19. Geraud G, Tremoulet M, Guell A, Bes A. The prognostic value of noninvasive CBF measurement in subarachnoid hemorrhage. *Stroke* 1984;15:301-305
20. Bergvall U, Steiner L, Forster DMC. Early pattern of circulatory disturbances following subarachnoid hemorrhage. *Neuroradiology* 1973;5:24-32
21. Eskesen V, Karle A, Kruse A, Kruse-Larsen C, Praestholm J, Schmidt K. Observer variability in assessment of angiographic vasospasms after aneurysmal subarachnoid hemorrhage. *Acta Neurochir* 1987;87:54-57
22. Heilbrun MP, Olesen J, Lassen NA. Regional CBF studies in subarachnoid hemorrhage. *J Neurosurg* 1972;3:36-44
23. Ishii R. Regional CBF in patients with ruptured intracranial aneurysms. *J Neurosurg* 1979;50:587-594
24. Powers WJ, Grubb RL Jr, Baker RP, Mintun MA, Raichle ME. Regional CBF and metabolism in reversible ischemia due to vasospasm. *J Neurosurg* 1985;62:539-546
25. Giller CA, Purdy P, Lindstrom WW. Effects of inhaled stable xenon on cerebral blood flow velocity. *AJNR* 1990;11:177-182
26. Lindstrom WW, Cecil R. *Computer simulation of the effects of xenon-induced flow activation on quantitative CBF xenon/CT results*. Presented at the International Conference on Stable Xenon/CT CBF, Orlando, Florida, February, 1990.
27. Good WF, Gur D. Xenon-enhanced CT of the brain: effect of flow activation on desired cerebral blood flow measurements. *AJNR* 1991;12:83-85
28. Symon L. Disordered cerebrovascular physiology in aneurysmal subarachnoid hemorrhage. *Acta Neurochir* 1978;41:7-22
29. Heros RC, Zervas NT, Varsos V. Cerebral vasospasm after subarachnoid hemorrhage: an update. *Ann Neurol* 1983;14:599-608
30. Yamamoto YL, Feindel W, Wolfe LS, et al. Experimental vasoconstriction of cerebral arteries by prostaglandins. *J Neurosurg* 1972;37:385-397
31. White RP, Hagen AA, Morgan H, et al. Experimental study on the genesis of cerebral vasospasm. *Stroke* 1975;6:52-57
32. Simeone FA, Ryan KG, Cotter JR. Prolonged experimental vasospasm. *J Neurosurg* 1968;29:357-366
33. Fraser RA, Stein BM, Barrett RE, Pool JL. Noradrenergic mediation of experimental cerebrovascular spasm. *Stroke* 1970;1:356-362
34. Zervas NT, Hori H, Rosoff CB. Experimental inhibition of serotonin by antibiotic: prevention of cerebral vasospasm. *J Neurosurg* 1974;41:59-62
35. Gavras H, Andrews P, Papadakis N. Reversal of experimental delayed cerebral vasospasm by angiotensin-converting enzyme inhibition. *J Neurosurg* 1981;55:884-888
36. Arutiunov AI, Baron MA, Majorova NA. The role of mechanical factors in the pathogenesis of short-term and prolonged spasm of cerebral arteries. *J Neurosurg* 1974;40:459-472
37. Hughes JT, Schianch PM. Cerebral arterial spasm: a histological study at necropsy of the blood vessels in cases of subarachnoid hemorrhage. *J Neurosurg* 1978;48:515-525
38. Brothers MF, Holgate RC. Intracranial angioplasty for the treatment of vasospasm after subarachnoid hemorrhage: technique and modifications to improve branch access. *AJNR* 1990;11:239-247
39. Higashida RT, Halbach VV, Dormandy B, Bell J, Brant-Zawadski M, Hiehima GB. New microballoon device for transluminal angioplasty of intracranial arterial vasospasm. *AJNR* 1990;11:233-238