

## Retroclival Arachnoid Cyst

Eric C. Bourekas,<sup>1</sup> M. Reza Raji,<sup>1</sup> Khurshed J. Dastur,<sup>1</sup> Gregory J. Francken,<sup>1</sup> David J. Engle,<sup>2</sup> and Narayan T. Nayak<sup>2</sup>

**Summary:** Retroclival arachnoid cyst is a rare mass lesion, with only seven cases previously reported in literature. MR is the imaging modality of choice in its evaluation and in its differentiation from epidermoid cyst. The case reported here was surgically proved and had an uncharacteristic MR signal intensity that was higher than that of cerebrospinal fluid due to previous hemorrhage.

**Index terms:** Arachnoid cysts; Clivus

Arachnoid cysts are benign, avascular, thin-walled, cerebrospinal fluid (CSF)-containing mass lesions, that occur most commonly in the middle cranial fossa (1). Posterior fossa arachnoid cysts are less common and retroclival cysts are rare (2, 3). We present the magnetic resonance (MR) findings of a surgically proved case and review the literature.

### Case Report

A 54-year-old woman presented complaining of a 6-month history of ataxia, quadraparesis, headaches, intermittent slurred speech, and urinary incontinence. A progressive 10-year history of decreasing hearing in the right ear was also noted.

Physical examination revealed an ataxic gait, bilateral Babinski signs, and decreased auditory acuity in the right ear. Motor and sensory examinations were normal.

MR examination revealed a large, extraaxial, retroclival mass extending from the posterior suprasellar region into the upper cervical spinal canal and into both cerebellopontine angles, right greater than left. Compression and posterior displacement of the brain stem was noted. The lesion demonstrated low signal intensity on the T1-weighted (390/16/4) (TR/TE/excitations) images and converted to high signal intensity on proton-density (190/40/2) and T2-weighted (1900/95/2) images. The signal intensity was higher than CSF on all sequences (Figs. 1A, 1B, and 1C). Cerebral angiography showed displacement of the basilar artery posteriorly and to the left, by an extraaxial avascular mass in the retroclival region. Scout films of the skull prior to angiography and MR (Fig. 1A) suggested erosion of the dorsum sellae and clivus. Differential diagnosis was arach-

noid cyst with high protein content most probably secondary to prior hemorrhage, versus epidermoid cyst.

At surgery, through a right retromastoid craniectomy and C1 laminectomy, a retroclival and cerebellopontine angle cyst was fenestrated. Cyst-fluid analysis revealed xanthochromic fluid consistent with prior hemorrhage. No evidence of infection was found. Cyst-wall histology was consistent with an arachnoid cyst.

### Discussion

After the middle cranial fossa, the posterior fossa is the most common location of arachnoid cysts (1). Within the posterior fossa, they are most commonly located in the midline and posterior to the cerebellum (4). Arachnoid cysts at the clivus are rare (2, 3). The subject of this report is a retroclival cyst extending from the posterior suprasellar region to the foramen magnum.

Some cysts lined by ependymal or choroidal cells may mimic arachnoid cysts, but most extraaxial posterior fossa cysts containing CSF are lined by arachnoid cells. A great deal of controversy exists as to the origin of arachnoid cysts. Many divide them into congenital and acquired. Acquired cysts are secondary to adhesive arachnoiditis, caused by prior trauma (5) or infection (6). Some believe that even congenital cysts are in fact acquired secondary to birth trauma. The most commonly accepted theory is that of Starkman et al (7), who felt that arachnoid cyst formation was the result of an aberration of CSF flow resulting in splitting of the arachnoid membrane during development.

Obstruction of CSF flow resulting in hydrocephalus and compression of adjacent brain parenchyma are causative factors in symptomatic patients with retroclival cysts. However, the clinical findings are nonspecific. Headache, dizziness, cranial nerve signs, and monobrachial weakness may be present. Ataxia, nystagmus, and signs of raised intracranial pressure are often found on

Received June 28, 1991; revision requested August 6; revision received September 10; final acceptance September 24.

<sup>1</sup> Department of Radiology, Mercy Hospital of Pittsburgh, 1400 Locust Street, Pittsburgh, PA 15219. Address reprint requests to E. C. Bourekas.

<sup>2</sup> Department of Neurosurgery, Mercy Hospital of Pittsburgh, Pittsburgh, PA 15219.



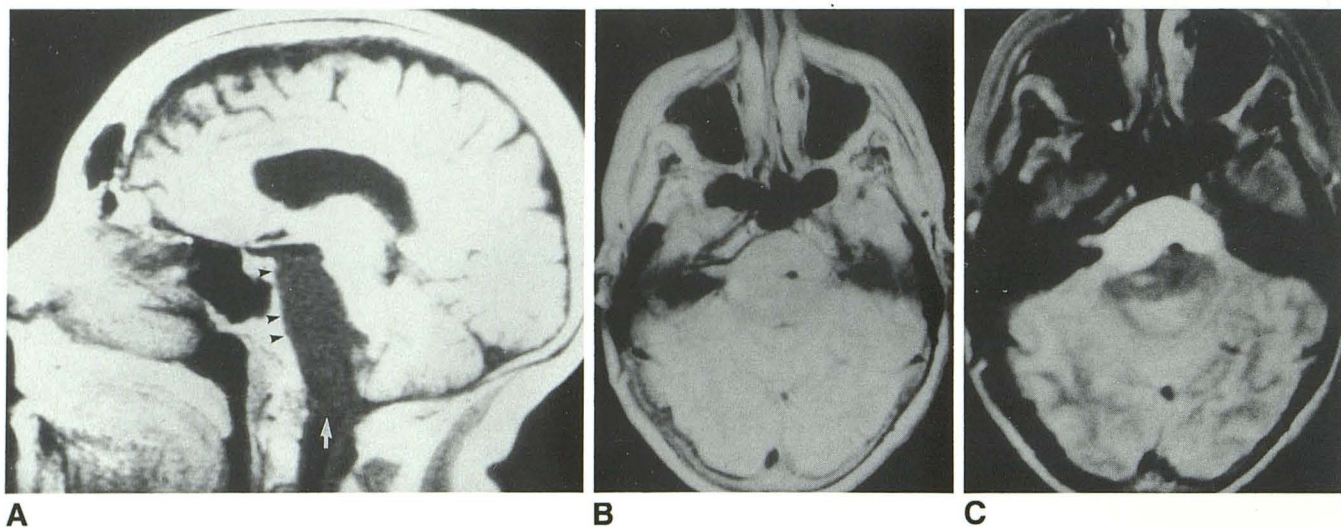


Fig. 1. A, Sagittal T1-weighted (390/16/4) image reveals a large, retroclival cyst extending from the posterior suprasellar region to the foramen magnum (arrow), causing compression and posterior displacement of the brain stem and erosion of the dorsum sellae and clivus (arrowheads). B and C, Axial proton-density (1900/40/2) and T2-weighted (1900/95/2) images show the arachnoid cyst compressing the brain stem and extending into the right internal auditory canal. The signal intensity of the cyst is higher than that of CSF because of prior hemorrhage.

physical exam. Hydrocephalus has been reported in most cases and was present in our case.

Diagnosis of arachnoid cyst has been greatly facilitated by computed tomography (CT) and MR. On CT, the margins of arachnoid cysts are sharp and well defined. The lesions are homogeneous, nonenhancing, noncalcified, and are of CSF density (8). MR, because of its multiplanar imaging and lack of beam hardening artifact, provides better anatomic detail for posterior fossa mass lesions. On MR, the signal intensities of the cyst contents are consistent with CSF on both T1- and T2-weighted images, unless the cyst contents have an elevated protein content secondary to hemorrhage or infection. Increased protein content of the cyst fluid shortens T1 and lengthens T2, causing increased signal intensity relative to CSF on both pulse sequences, as was noted in our case. This was felt to be due to previous hemorrhage. Contrast cisternography may demonstrate whether there is communication between cyst and subarachnoid space, which may be of significance in the choice of treatment modality (9). Cerebral angiography may demonstrate an avascular mass causing posterior displacement of the basilar artery. Erosion of the dorsum sellae and clivus may be demonstrated on radiography of the skull and MR.

The major differential diagnosis of a retroclival arachnoid cyst is an epidermoid tumor. On CT, epidermoids are extraaxial, low-density mass lesions, that may have rim calcification and may

show peripheral enhancement. MR is useful in differentiating epidermoids from arachnoid cysts. On MR, epidermoids have irregular margins, heterogeneous signal, and are of higher signal intensity than CSF on T1-weighted, proton-density and T2-weighted images (10).

Surgical options for treatment of symptomatic arachnoid cysts include: suboccipital craniectomy with fenestration of the cyst, stereotactic drainage through the vertex (2), and ventriculoperitoneal shunting if the cyst does communicate with the CSF-space or cystoperitoneal shunting if the cyst does not communicate (9).

## References

1. Heier L, Zimmerman R, Amster JL, et al. Magnetic resonance imaging of arachnoid cysts. *Clin Imaging* 1989;13:281-291
2. Iacono RP, Labadie EL, Johnstone SJ, Teresa K, Bendt RN. Symptomatic arachnoid cyst at the clivus drained stereotactically through the vertex. *Neurosurgery* 1990;27:130-133
3. Rousseaux M, Lesoin F, Dhellemmes P, Jomin M. Retroclival cysts. *Neurochirurgia* 1986;29:244-247
4. Little JR, Gomez MR, MacCarthy CS. Infratentorial arachnoid cysts. *J Neurosurg* 1973;39:380-386
5. Gomez MR, Yanagihara T, MacCarthy CS. Arachnoid cyst of the cerebellopontine angle and infantile spastic hemiplegia case report. *J Neurosurg* 1968;29:87-90
6. Craig WM. Chronic cyst arachnoiditis. *Am J Surg* 1932;17:384-388
7. Starkman SP, Brown TC, Linell EA. Cerebral arachnoid cysts. *J Neuropathol Exp Neurol* 1958;17:484-500
8. Leo LS, Pinto RS, Julrat GF, Epstein F, Kricheff II. Computed tomography of arachnoid cysts. *Radiology* 1979;130:675-680
9. Lehman LB. Arachnoid cysts: diagnosis and treatment. *Hosp Practice (Off)* 1989;24:139-142
10. Panagopoulos K, El-Azouzi M, Chisholm H, Joslesz F, Black P. Intracranial epidermoid tumors. *Arch Neurol* 1990;47:813-816.