

---

# CT of Severe Inner Ear Anomalies, Including Aplasia, in a Case of Wildervanck Syndrome

Gilbert Keeney,<sup>1</sup> Stephen S. Gebarski,<sup>1</sup> and James A. Brunberg<sup>1</sup>

**Summary:** The authors describe some unusual features of a case of Wildervanck syndrome (male patient and facial nerve paralysis), and present and discuss CT images of inner ear aplasia.

**Index terms:** Temporal bone, computed tomography; Ear, abnormalities and anomalies; Ear, computed tomography

The Wildervanck (or cervico-oculo-acoustic) syndrome consists of the characteristic triad of Klippel-Feil anomaly, abducens nerve palsy, and congenital deafness. It is a rare "disorder of polygenic heredity with sex limitation predominant to the female" (female-male ratio is 10:1) (1). Hearing loss is most commonly neurosensory due to developmental inner ear anomalies. Only a single case of associated congenital facial nerve paralysis has been described (2).

We report this case of Wildervanck syndrome to display computed tomography (CT) images of inner ear aplasia (a rare anomaly) and to cite some unusual features, namely male sex and facial nerve paralysis.

## Patient and Methods

A 29-year-old man with profound congenital neurosensory hearing loss, Klippel-Feil anomaly, and congenital right abducens and facial nerve palsies presented for CT evaluation of his temporal bones and brain. The patient had a history of cleft palate repair, webbed neck, asymmetric head shape, and mental retardation. CT was obtained on a GE 9800 HR CT unit (General Electric, Milwaukee, WI). Contiguous sections, 1.5-mm thick, of the temporal bones and posterior fossa were obtained using a 14-cm field of view. Both soft tissue and bone algorithms were utilized. The angle of acquisition was nearly parallel to the clivus. Ten-millimeter contiguous axial images were then acquired through the remainder of the cranial vault. No contrast material was employed.

## Results

The right temporal bone demonstrated hypoplasia of the petrous portion and complete inner ear aplasia. The middle and external ear structures were mildly dysplastic. No clearly definable internal auditory canal was present. A diminutive, dysplastic facial nerve canal was present.

The left temporal bone showed severe inner ear dysplasia with a globular bony labyrinth. The internal auditory canal was hypoplastic. The middle and external ear structures were mildly dysplastic.

The sphenoid bone was markedly hypoplastic with near apposition of the carotid canals. There was mild plagiocephaly, probably secondary to lambdoidal suture synostosis. No brain stem abnormality was demonstrated.

## Discussion

Otologic abnormalities occur frequently in congenital head and neck syndromes. The Klippel-Feil anomaly is associated with congenital hearing loss, both sensorineural and conductive, in one third of cases. The combination of the Klippel-Feil anomaly and hearing loss are features of the Wildervanck and Goldenhar syndromes. Wildervanck syndrome also includes the Duane retraction syndrome, which is a distinctive eye movement disorder due to altered abducens innervation, most likely supranuclear in location. The Goldenhar syndrome in contrast has associated epibulbar dermoids, lipodermoids, preauricular appendages, and aural fistulas. It has been postulated that the Wildervanck and Goldenhar syndromes are not isolated entities, but part of a

---

Received February 7, 1991; revision requested April 2, revision received June 5; final acceptance July 9.

<sup>1</sup> All authors: Department of Radiology, University of Michigan Hospitals, Room B1 D530, Ann Arbor, MI 48109-0030. Address reprint requests to S. S. Gebarski.



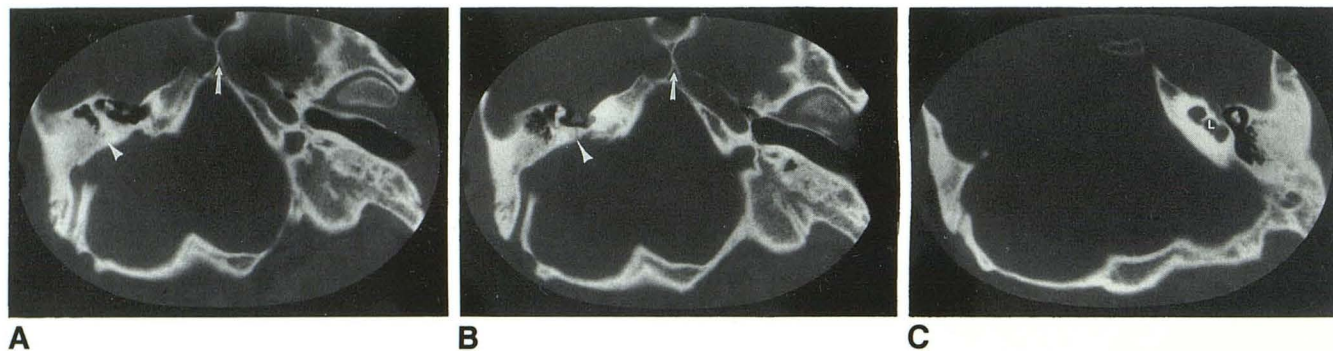


Fig. 1. A–C, Serial temporal bone CT from the petrous portion of the internal carotid artery (A) through to the left labyrinth (C). Right temporal bone (A and B); mildly dysplastic middle ear structures. The petrous portion of the temporal bone is nearly absent with aplasia of inner ear structures. Dyplastic facial nerve canal (*arrowhead*). Sphenoid bone (A and B); marked hypoplasia of the body of the sphenoid bone with near apposition of the carotid canals (*arrow*). Left temporal bone (A–C); globular dysplastic bony labyrinth (L).

continuum of the same hereditary disorder (3, 4).

Since there has been one previous clinical report of facial nerve palsy with Wildervanck syndrome, this finding may also represent an associated anomaly rather than coincidence (2). Temporal bone CT was not included in this previous report.

The right-sided inner ear aplasia in our case of Wildervanck syndrome suggests that a failure in otologic development must have occurred prior to or approximately at 5 weeks gestation. The insult causing the left inner ear dysplasia could have occurred anytime between the 5th and 8th week of gestation. The 5th through 8th weeks of gestation are when the globular otic vesicle, formed from the rhombencephalic ectodermal otic placode, carries out its differentiation into a mature appearing labyrinth (5).

### Dedication

This work is dedicated to the memory of Gilbert Keeney.

### References

1. Wildervanck LS. The cervico-oculo-acusticus syndrome. In: Vinken PJ, Bruyn GW, Myrianthopoulos NC, eds. *Handbook of clinical neurology*. Vol 32. New York: Elsevier/North-Holland Biomedical Press, 1978:123–130
2. Strisciuglio P, Raia V, Di Meo A, Rinaldi E, Andria G. Wildervanck's syndrome with bilateral subluxation of lens and facial paralysis. *J Med Genet* 1983;20:72–73
3. Ohtani I, Dubois CN. Aural abnormalities in Klippel-Feil syndrome. *Am J Otol* 1985;6:468–471
4. Gellis SS, Feingold M. Congenital brevicollis (Klippel-Feil syndrome). *Am J Dis Child* 1971;121:501–502
5. Sadler TW. *Langman's medical embryology*. 5th ed. Baltimore: Williams & Wilkins, 1985:311–319