

Morphometric Changes of the Human Midbrain with Normal Aging: MR and Stereologic Findings

P. Murali Doraiswamy,¹ Chul Na,¹ Mustafa M. Husain,³ Gary S. Figiel,⁴ William M. McDonald,¹ Everett H. Ellinwood, Jr,¹ Orest B. Boyko,² and K. Ranga R. Krishnan¹

Purpose: To determine the effects of age on estimated midbrain volume. **Patients and Methods:** T2-weighted MR imaging and an unbiased stereologic method were used in 75 volunteers; the subjects ranged in age from 21 to 82 years and were without any significant neurologic or psychiatric disorders. **Results:** Age was negatively correlated with estimated midbrain volume ($R = -.39, P < .0005$), with the anteroposterior diameter through the substantia nigra ($R = -.33, P < .004$) and with the interpeduncular distance ($R = -.24, P < .04$). The linear measurements for the right and left side were almost identical. These findings are consistent with prior reports of nigrostriatal degeneration with increasing age. Furthermore, they suggest a close symmetry of age-related changes between the right and left side in normal subjects. **Conclusion:** Volumetric and linear measurements of midbrain morphology with MR may prove useful in the investigation of neurologic disorders such as Parkinson disease.

Index terms: Age and aging; Mesencephalon, magnetic resonance; Brain, volume

AJNR 13:383-386, January/February 1992

Age-related degenerative changes in the midbrain, particularly in the nigrostriatal system, may play a role in the pathogenesis of several disorders, notably Parkinson disease (1), Shy-Drager syndrome (2), striatonigral degeneration, olivoponto-cerebellar atrophy (2), Alzheimer disease (3), Wilson disease (4), and Huntington disease (5). Data on age-related changes of the midbrain in normal subjects will facilitate further investigation of the relation between midbrain changes and the neuromotor decline with normal aging. This normative data can also be used to compare findings in patients with neurologic disorders related to the nigrostriatal system.

Most of our current knowledge on age-related changes in the nigrostriatal system comes from postmortem and positron emission tomography

(PET) studies. Postmortem studies by McGeer et al (6), Thiessen et al (7), and Mann et al (8) have documented decreased counts of nigrostriatal neurons with advancing age. In addition, De Keyser et al (9) found a steady decrease of presynaptic dopaminergic uptake sites in the putamen nucleus at autopsy between the ages of 19 to 88 yr, suggestive of age-related loss of nigrostriatal axons. However, postmortem studies are subject to criticism because they are retrospective and factors such as postmortem delay and inadequate screening of control subjects can confound the results. Two in vivo studies have used PET to evaluate age-related changes in the nigrostriatal system, but have reported conflicting results. Martin et al (10) found a linear decrease in fluoro-Dopa uptake into striatal tissue with advancing age. Sawle et al (11) analyzed their fluoro-Dopa uptake data separately for the caudate and putamen nuclei and found no age effects.

Magnetic resonance (MR) imaging can visualize with high-resolution regions within the midbrain, such as the substantia nigra (12, 13), red nucleus, the colliculi, and peduncles (4, 13). MR can also be used for quantitative morphometric studies of the midbrain. Recent MR studies have correlated midbrain morphology with symptomatology in several disorders, including Parkinson disease

Received June 28, 1991; revision requested August 12; revision received August 29; final acceptance September 9.

¹ Department of Psychiatry, Box 3215, Duke University Medical Center, Durham, NC 27710. Address reprint requests to K. R. Krishnan.

² Department of Radiology, Duke University Medical Center, Durham, NC 27710.

³ Department of Psychiatry, University of Texas-Southwestern Medical Center, Dallas, TX.

⁴ Department of Psychiatry, Washington University, St. Louis, MO.

AJNR 13:383-386, Jan/Feb 1992 0195-6108/92/1301-0383

© American Society of Neuroradiology

(12) and Wilson disease (4), suggesting that morphometric data may indirectly reflect underlying neurochemical or pathologic processes.

Systematic stereology is an unbiased and efficient method of brain morphometry (14) that has also been applied for cell counts in the midbrain (15). We have previously reported using this method in vivo with MR images to rapidly estimate volumes of the basal ganglia nuclei (16) and the cerebellum (17). In this prospective study, we use this method with MR imaging to determine the effects of age on midbrain volume in a sample of 75 healthy subjects.

Materials and Methods

Subjects

Seventy-five normal volunteers participated after giving written informed consent. Each subject underwent a thorough neurologic, psychiatric, and physical examination and was determined to be free of any significant neurologic and psychiatric illnesses. The 75 subjects (34 men) ranged in age from 21 to 82 yr with a mean age (SD) of 52.5 (18) yr. The mean age (SD) of the female subjects was 54 (18) and for men was 51 (19) years. Thirty-four subjects were below the age of 50 yr and 41 subjects were above the age of 50 yr.

MR Acquisition

MR was performed with a 1.5 T GE Signa System (General Electric, Milwaukee, WI). The subjects were positioned in a quadrature head coil with the canthomeatal line at 0 degrees from the vertical axis and the laser of the imager grid centered at the nasion. Five-millimeter thick axial slices (interslice gap of 2.5 mm) were obtained parallel to the canthomeatal line using flow compensation and a variable band-width pulse sequence. Spin echo acquisition parameters were 500/20 (TR/TE) for the T1-weighted images, 2800/30 and 2800/80 for intermediate (first echo) and T2-weighted (second echo) images, respectively. The T2-weighted second echo image (Fig. 1) was used to measure midbrain volume and linear dimensions, since this allowed for adequate distinction of the midbrain from surrounding tissue and CSF.

T1- and T2-weighted images were reviewed to exclude gross pathology, such as space occupying lesions and obvious anatomical variations.

Midbrain Volume and Linear Measurements

The volume of the midbrain was measured using systematic sampling and the point counting method described previously (16, 17). A professionally calibrated computer-generated transparent square lattice grid, with the area of each square measuring exactly 1.0 mm × 1.0 mm, was placed randomly on the midbrain and the number of cross

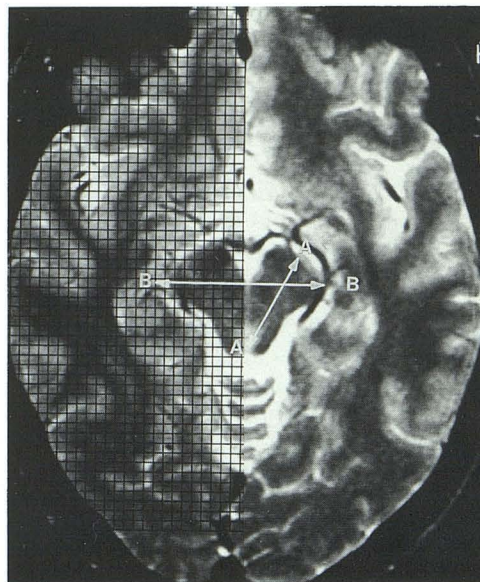


Fig. 1. T2-weighted MR image at the level of the midbrain substantia nigra and red nucleus illustrating linear measurements and method of point counting using a square grid. The grid was placed over the entire midbrain and not on one-half as shown here.

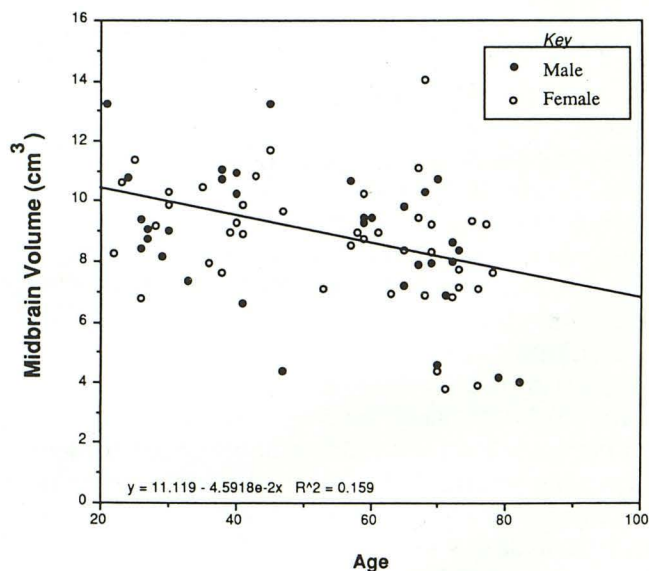


Fig. 2. Plot showing the relationship between age and estimated midbrain volume in 75 normal subjects. Two 39-year old subjects, one man and one woman, had identical volumes and, hence, only 74 data points are seen.

hairs intersecting the midbrain were counted. Midbrain volume was obtained using the formula: Volume = ((slice thickness + interslice gap) × (points counted for all slices) × (area of square on the grid) × (magnification factor)²).

In addition, the following linear measurements were obtained using a computer-generated transparent scale calibrated to 0.5 mm: the maximum anteroposterior diameter of the midbrain through the substantia nigra (A-A

in Fig. 1); the maximum interpeduncular distance (*B-B* in Fig. 1); and the maximum diameter of the red nucleus. Linear measurements were made at the level of the substantia nigra and red nucleus (4).

All measurements were made blinded to the subject's age and using head-mounted magnifying glasses. An MR atlas and an anatomic-MR correlative study of the brain stem (13) was used to identify boundaries when in doubt. Data reported reflect actual brain sizes.

Statistical Analysis

Data was analyzed using PC-SAS software (SAS Institute, Cary, NC). All data are reported as the mean (\pm SD). The Student's two-tailed *t*-test procedure was used to evaluate significant differences between groups, and the Pearson's correlation coefficient was used to evaluate correlations between variables. Subjects were also divided into young (≤ 50 yr) or old (> 50 yr), since some previous reports have specifically investigated midbrain changes using this cutoff and since Parkinson disease commonly presents at 50 years of age (11). A *P* value less than .05 was considered significant.

Results

For all subjects the mean (\pm SD) estimated midbrain volume was 8.71 (± 2) cc with a range of 3.8 to 14 cc. The mean anteroposterior diameter, 2.7 (± 0.3) cm, was almost identical for right and left sides, and ranged from 1.9 cm to 3.98 cm. The mean interpeduncular distance was 4.03 (± 0.6) cm, with a range of 2.7 to 5.3 cm. The mean diameter of the red nucleus was 6.2 mm (± 1) for the right side and 6.4 (± 1) mm for the left side, with a range of 4.0 to 9.3 mm.

Subjects older than 50 years of age had significantly smaller estimated midbrain volume ($t = 2.96$, $P < .005$) and average anteroposterior diameter ($t = 2.44$, $P < .018$) than younger subjects. Age was correlated negatively with estimated midbrain volume ($R = -.39$, $P < .0005$) (Fig. 2), with anteroposterior diameter ($R = -.33$, $P < .004$ for both left and right side) and with interpeduncular distance ($R = -.24$, $P < .04$), but not with red nucleus size ($R = -.13$) and $R = .01$, $P > .8$ for right and left sides). Average anteroposterior diameter and red nucleus size was almost identical for the right and left side. Both anteroposterior diameter and interpeduncular distance were correlated with estimated midbrain volume ($R = .69$, and $R = .67$, $P < .0001$).

Male subjects (mean age = 51, SD = 19) did not differ from female subjects (mean age = 54, SD = 18) in age ($t = .76$, $df = 73$, $P = 0.45$). Age was negatively correlated with estimated

midbrain volume in both males ($R = -.44$, $P = .0097$) and females ($R = -.36$, $P = .02$). Mean midbrain volumes did not differ when males were compared to females ($t = -.16$, $df = 73$, $P = .87$).

Discussion

The main findings in this study were that estimated midbrain volume, the anteroposterior diameter intersecting the substantia nigra, and the interpeduncular distance declined with advancing age. Estimated midbrain volumes showed a three-fold variation for all subjects. Linear midbrain measurements were almost identical for the left and right sides, suggesting a close symmetry of change in healthy subjects during normal aging. The uniform MR methodology, the prospective selection of normal volunteers, and the relatively large sample size adds credence to our findings.

As mentioned above, volumetric data may potentially provide indirect information regarding underlying neurochemical or pathologic changes. Speculatively, the age-related decline in midbrain volume may be related to the previously reported (6–10) age-related loss of substantia nigra neurons or to degeneration of other neuronal systems (eg, serotonergic or cranial nerve nuclei).

Our findings also have some potential clinical implications. Several studies, including a recent study of linear measurements of the midbrain in Wilson disease (4), have found midbrain morphology on MR to correlate with neurologic status. We speculate that a decline in midbrain volume with advancing age may be related to the reported decline in some neuromotor functions with normal aging (reviewed in reference 11). Since all of our controls were neurologically normal, the values presented here will also serve as normative data for comparison with findings in patients with neurologic disorders related to the midbrain. Estimated midbrain volume declined with age in both men and women and did not differ between men and women. This is consistent with our previous report that caudate volumes do not differ between men and women of similar age (16). The symmetry in midbrain measurements between the right and left side in normal subjects may be of radiologic interest, since it has been reported that asymmetry in pars compacta width may be a sensitive MR indicator for the early detection of Parkinson disease with predominant unilateral clinical symptoms (12).

There are some potential limitations in interpreting the results of our study. We used external rather than internal landmarks to orient our axial MR images. In addition, the protocol for axial imaging in our normal subjects, designed to match the protocol currently accepted for routine clinical brain MR studies at our institution, used 5-mm thick slices with a 2.5-mm interslice gap not graphically prescribed to any internal brain landmarks. This was essential in order to compare control scans with previously obtained patient scans in future studies. A future study of interest would be to compare volumetric data obtained using thinner interleaved slices perpendicular to the long axis of the midbrain with those in this study. Although the absolute values obtained could be different, we would predict that the trend for age-related volume loss would still be found. The normative estimated volume obtained from systematic stereology provides an advantage for group comparison studies since this technique can easily be applied to hard-copy films and to protocols where the first slice intersects the structure of interest randomly. Volumes of other brain structures estimated by stereology from 5-mm thick axial MR images with a 2.5-mm gap were similar to those obtained in autopsy studies (16). Thus, we feel that our measurements provide a valid estimate of midbrain volume for purposes of group comparison.

The midbrain is suspected to be involved in several neurologic disorders, including Parkinson disease (1), multisystem atrophy (2), Alzheimer disease (3), Wilson disease (4), and Huntington disease (5). Quantitative morphometric studies of the midbrain may provide valuable insights into the pathogenesis or early detection of these disorders, and MR provides a useful noninvasive method for testing these hypotheses.

References

1. Calne DB, Eisen A, McGeer EG, Spencer P. Alzheimer's disease, Parkinson's disease and motorneuron disease: abiotrophic interaction between aging and environment. *Lancet* 1986;1:1067-1070
2. Tsuchiya K. High-field MR findings in multiple system atrophy. *Nippon Igaku Hoshasen Gakkai Zasshi* 1991;50:772-779
3. Rinne J, Rummukainen J, Paljarui L, Sako E, Mols P, Rinne U. Neuronal loss in the substantia nigra in patients with Alzheimer's disease and Parkinson's disease in relation to extrapyramidal symptoms and dementia. *Prog Clin Biol Res* 1989;317:325-332
4. Grimm G, Prayer L, Older W, et al. Comparison of functional and structural brain disturbances in Wilson's disease. *Neurology* 1991;41:272-276
5. Oyanagi K, Takeda S, Takahashi H, Ohama E, Ikuta F. A quantitative investigation of the substantia nigra in Huntington's disease. *Ann Neurol* 1989;26:13-19
6. McGeer PL, McGeer EG, Suzuki JS. Aging and extrapyramidal function. *Arch Neural* 1977;34:33-35
7. Thiessen B, Rajput AH, Laverty W, Desai H. Age, environments, and the number of substantia nigra neurons. *Adv Neurol* 1990;53:201-206
8. Mann DMA, Yates PO, Maryniuk B. Monoaminergic neurotransmitter systems in presenile Alzheimer's disease and in senile dementia of Alzheimer's type. *Clin Neuropathol* 1984;3:199-205
9. De Keyser J, Ebinger G, Vauquelin G. Age-related changes in the human nigrostriatal dopaminergic system. *Ann Neurol* 1990;27:157-161
10. Martin WR, Palmer MR, Patlack CS, Calne DB. Nigrostriatal function in humans studied with positron emission tomography. *Ann Neurol* 1989;26:535-542
11. Sawle GV, Colebatch JG, Shah A, et al. Striatal function in normal aging: implications for Parkinson's disease. *Ann Neurol* 1990;28:799-804
12. Huber SJ, Chakeres DW, Paulson GW, Khanna R. Magnetic resonance imaging in Parkinson's disease. *Arch Neurol* 1990;47:735-737
13. Solsberg MD, Fournier D, Potts DG. Magnetic resonance imaging of the excised brain stem: correlative neuroanatomic study. *AJNR* 1990;11:1003-1013
14. Braendgaard H, Gundersen HJG. Recent stereological developments in neuroscience. *J Neurosci Methods* 1986;18:39-78
15. Pakkenberg B, Moller A, Gundersen HJ, Pakkenberg H. The absolute number of substantia nigra nerve cells in normal subjects and in Parkinson's disease. *J Neurol Neurosurg Psychiatry* 1991;54:30-33
16. Krishnan KR, Husain MM, McDonald WM, et al. In vivo stereological assessment of caudate nuclei using MRI: effect of age. *Life Sci* 1990;47:1325-1329
17. Escalona PR, McDonald WM, Doraiswamy PM, et al. In vivo stereological assessment of cerebellar volume using MR: effects of gender and age. *AJNR* 1991;12:927-929