

Nonlissencephalic Cortical Dysplasias: Correlation of Imaging Findings with Clinical Deficits

A. James Barkovich¹ and Bent O. Kjos²

Purpose: To establish correlations between MR patterns and clinical outcome in patients with nonlissencephalic cortical dysplasias. **Patients and Methods:** MR and clinical data from 36 patients with cerebral cortical gyral anomalies (other than classical type I or type II lissencephaly) were retrospectively reviewed. **Result:** The five patients with diffuse cortical dysplasia, including two with congenital infections, had microcephaly and severe development delay from a very early age. Infantile spasms occurred in three of the five. Focal areas of cortical dysplasia were most common in the frontal lobes, but were seen in all areas of the brain. The most common MR appearances were 1) a thickened, irregularly bumpy cortex with shallow, wide sulci, and 2) a deep infolding of thickened cortex. The twelve patients with bilateral focal dysplasia had a high incidence of bilateral motor dysfunction (67%), delayed speech (67%), and generalized developmental delay (92%). When the dysplasia was unilateral, contralateral spastic hemiplegia or monoplegia was present in 14 of 19 patients (74%), but dysphasia was uncommon, even in patients with dysplasia in the frontal lobe of the dominant hemisphere. **Conclusion:** Surgical resection of focal areas of cortical dysplasia in patients with medically refractory seizures is becoming more common, and the neuroradiologist will play an increasingly important role in the initial diagnosis and delineation of these anomalies.

Index terms: Migration anomalies; Magnetic resonance, in infants and children

AJNR 13:95-103, January/February 1992

Until very recently, anomalies of neuronal migration were thought to be rare (1-3). The increased sensitivity of magnetic resonance (MR) and an enhanced awareness of these disorders in the radiologic community has resulted in an increasing recognition thereof. Although the expected clinical course of patients with severe anomalies of neuronal migration, such as lissencephaly and unilateral megalencephaly, is well established (2-7), information regarding the clinical prognosis of focal anomalies of neuronal migration (focal cortical dysplasia) in various cortical locations is scarce. Therefore, we undertook the project of analysis of clinical records in a large series of patients with congenital cortical dyspla-

sia in an attempt to correlate MR findings with clinical manifestations.

Patients and Methods

MR scans and clinical records of 36 patients with congenital cortical dysplasia (other than classical type I or type II lissencephaly (2, 7)) were retrospectively reviewed. The patients ranged in age from 1 week to 40 years at the time of the MR scan (mean age was 10.5 years, median age was 3 years). Twenty-two patients were male and 14 were female. Patient charts were reviewed with specific attention to the following: presence or absence of seizures; type of seizures; presence or absence of motor deficits; type of motor deficit (spastic vs flaccid); area of body involved (quadripareisis vs hemiparesis vs monoparesis); developmental level (percent of developmental age as determined by the Denver Developmental Screening Test) in younger patients; intelligence quota in older patients; and development and/or attainment of normal speech. MRs were evaluated with specific attention to: the severity, location, and size of anomaly (involved lobes); presence or absence of continuity of the anomalous cortex with the sylvian fissure; presence or absence of prolonged T2 relaxation in the underlying white matter; configuration of the dysplastic cortex (flat cortex or infolded cortex); and presence or

Received April 1, 1991; accepted and revision requested May 28; revision received June 25; final acceptance June 25.

¹ Department of Radiology, Neuroradiology Section L371, University of California, San Francisco, 505 Parnassus Avenue, San Francisco, CA 94143-0628. Address reprint requests to A.J. Barkovich.

² Department of Radiology, Swedish Hospital, Seattle, WA 98116.

AJNR 13:95-103, Jan/Feb 1992 0195-6108/92/1301-0095

© American Society of Neuroradiology

absence of associated anomalies. Patients with known genetic syndromes were excluded. Extent of lobar involvement was assessed by examination of sagittal, axial and coronal images in combination. The size of a lesion was judged small if it involved less than one-third of a lobe, medium if it involved between one-third and two-thirds of a lobe, and large if it involved more than two-thirds of a single lobe or if it involved more than one lobe of a hemisphere. Cortical thickness was measured on long TR/TE images in patients younger than 10 months and in patients older than 24 months. The thickness was measured on T1-weighted images in patients between 10 months and 24 months old because the changing signal intensity of the subcortical white matter makes the inner cortical margin difficult to evaluate on T2-weighted images at that time (8). The thicknesses were measured on axial or coronal images at locations in which the imaging plane was felt to be most perpendicular to the involved gyrus. Films were read separately by the authors without knowledge of detailed clinical history. Clinical data were then obtained for each patient scanned. The imaging data was not known by the clinicians at the time of their examination of the patients.

Six patients were scanned at 0.35 T. Sagittal spin echo (SE) 500–600/30–40/2 images (TR/TE/excitations) were obtained using a 5–7 mm slice thickness, 1–3 mm “gap”, and 128 × 256 matrix. Axial 5–7 mm SE 2000/40–80 images were obtained in all six patients and coronal 5–7 mm SE 500/40 images were obtained in four of the six. The remaining patients were all scanned at 1.5 T. Sagittal 5 mm SE 600/20 and axial 5 mm 2500–3000/25–60, 70–120 images (2.5 mm “gap”) were obtained in all patients. Supplemental coronal 5 mm SE 600–800/20 or SE 2000–3000/25–60, 70–120 images were obtained in 27 of the 30. Axial 5 mm SE 600/20 images were obtained in all patients less than 18 months old.

Statistical analysis was performed using the null hypothesis and the Fisher exact probability test (9). Disorders of development, speech, and motor function were correlated with the extent of cortical involvement (diffuse, bilateral, and unilateral), location (left hemisphere, right hemisphere, individual lobes), size of involved area (small, medium, or

large), seizures, and presence of foci of prolonged T2 relaxation.

Results

A compilation of clinical and MR findings of the 36 patients are listed in Tables 1–4. A key to the abbreviations used in the tables is provided. Of the 31 patients (62 hemispheres) with focal cortical dysplasia, 43 hemispheres were involved. Of these, 17 hemispheres had only frontal lobe involvement, eight had only parietal involvement, three had only occipital involvement, 10 had frontal and parietal involvement, and one patient had each of frontal, parietal, and occipital, temporal and parietal, temporal and occipital, temporal and frontal, and temporal, frontal and parietal involvement.

Diffuse Cortical Dysplasia

Patients with diffuse cortical dysplasia included two born prematurely (33 and 34 weeks) and three born at term. Variable decelerations and terminal bradycardia were noted at delivery in one of the infants born at term, who had APGARS of 5 and 9 at 1 and 5 min. No complications were noted at delivery in the other four patients. All presented in the first few months of life (median age was 4 months old) with hypotonia; the older patients developed appendicular hypertonia and spasticity. Four of the five had severe microcephaly, the lone exception having a normal head circumference in spite of hydrocephalus. All patients old enough to have attained milestones were severely developmentally delayed. Only one had a frank seizure disorder, although three had infantile spasms; the spasms were never noted before the age of 4 weeks. The cerebral cortex in

Key to Abbreviations Used in Tables

C/M	Cognition/milestones	Occ	Occipital
CMV	Cytomegalovirus infection (congenital)	Par	Parietal
D	Delayed	PC	Partial complex seizures
DP	Diplegia	PMG	Pathologically proven polymicrogyria
DQ	Developmental quotient	QP	Quadripareisis
FM	Focal motor seizures	RHP	Right hemiparesis
Fr	Frontal	RMP	Right monoparesis
HCP	Hydrocephalus	T	Temporal
IQ	Intelligence quotient	↑T2 WM	Areas of prolonged T2 in white matter
(L), (M), (S)	Large, medium, small	TC	Tonic clonic seizures
LHP	Left hemiparesis	Temp	Involving temporal lobe
LMP	Left monoparesis	Toxo	Toxoplasmosis infection (congenital)
NL	Normal	Y	Patient too young to evaluate

TABLE 1: Diffuse Cortical Dysplasia: Five Patients

Patient	Sex	Age	Motor	Speech	C/M	Seizures	Comments
1	F	7 days	Hypotonia	Y	Y	Spasms	HCP Congenital CMV
2	M	4 mo	Hypotonia	Y	Y	Spasms	HC < 2%, PMG
3	F	7 mo	Diffuse spasticity	Y	D (DQ < 50)	θ	↑ T2 WM HC < 2%
4	M	3.5 yr	QP	D	D (DQ = 50)	θ	Congenital Toxo HC < 2%
5	M	14 yr	QP	Few words	D (DQ < 50)	Myoclonic	Heterotopias Occipital encephalocele HC < 2% ↑ T2 WM

TABLE 2: Bilateral Focal Cortical Dysplasia: 12 Patients

Patient	Sex	Age	Right Hemisphere	Left Hemisphere	Motor	Speech	C/M	Seizures	Comments
6	F	13 mo	Fr (L)	Fr (L)	QP	D	DQ = 80		
7	M	15 mo	Par (M)	Par (M)	Central hypotonia	D	DQ = 70	Spasms	
8	M	17 mo	Occ (M)	Occ (M)	Dystonia choreoathetosis	Autistic	DQ = 50-70	PC	Asphyxia myelin delay
9	F	23 mo	Fr-Par (L)	Fr-Par (L)	QP	D	DQ = 70	FM	
10	M	2 yr	Fr (L)	Fr (S)	DP	D	DQ = 50	FM, TC	Congenital CMV ↑ T2 WM
11	M	2 yr 2 mo	Par (L)	T-Par (L)	NL gross	D	DQ = 50-70		
12	M	2 yr 6 mo	Par (S)	Fr-Par (L)	LHP	Receptive aphasia	DQ = 70		↑ T2 WM
13	M	3 yr	Fr (L)	Fr (L)	LHP	D	DQ = 50-70		↑ T2 WM
14	M	12 yr	Fr-Par (L)	Fr-Par (L)	QP	D	IQ < 50	PC, FM, TC	Multiple anomalies
15	M	17 yr	Par (S)	Par (S)	NL	Was delayed	IQ = 70	TC	
16	M	31 yr	Par (L)	Par (L)	NL	Was delayed	IQ = 70-90	TC	Seizures onset age 2
17	F	32 yr	Fr (L)	Fr (L)	QP	Was delayed	IQ = 90	FM	Seizures onset age 3

TABLE 3: Right Focal Cortical Dysplasia: 13 Patients

Patient	Sex	Age	Location	Motor	Speech	C/M	Seizures	Comments
18	M	4 mo	Fr-Par (L)	LHP	Y	D	FM	Prune belly syndrome
19	F	9 mo	Fr-Par (L)	LHP	Y	DQ = 70	FM	
20	F	1 yr	Fr (L)	LHP	Y	DQ = 70		
21	M	1 yr	Fr (L)	LHP	Y	DQ = 50-70	FM	
22	M	3 yr	Fr-Par (L)	LHP	D	DQ = 50-70		Behavior problems ↑ T2 WM
23	M	7 yr	Fr (L)	LHP	NL	IQ = 70	FM, TC	PMG
24	M	8 yr	Fr (M)	LHP	NL	IQ = 70	FM	
25	M	17 yr	Occ (S)	NL	NL	IQ = 80-90	FM, PC	↑ T2 WM
26	M	23 yr	Temp-Occ (L)	NL	NL	IQ = 70	PC	↑ T2 WM, poor memory, PMG
27	M	29 yr	Fr (M)	NL	NL	IQ = 70	FM	Seizures onset 27 yr
28	M	35 yr	Temp-Fr (L)	LHP	NL	IQ = 50-70	FM	
29	M	37 yr	Fr (M)	LMP (leg)	NL	NL	FM	Seizures onset 37 yr
30	M	40 yr	Par-Occ (L)	LHP	NL	IQ = 70	FM, TC	↑ T2 WM, PMG

TABLE 4: Left Focal Cortical Dysplasia: Six Patients

Patient	Sex	Age	Location	Motor	Speech	C/M	Seizures	Comments
31	F	20 mo	Fr (M)	RMP (leg)	NL	NL		
32	F	2 yr	Fr-Par (L)	RMP (leg)	NL	NL		
33	F	3 yr	Fr-Par (L)	RHP	D	DQ = 70	FM	
34	F	3 yr	Fr-T-Par (L)	RHP	D	DQ = 50	FM	
35	F	4 yr	Fr (S)	NL	NL	NL	FM	Calcified
36	F	36 yr	Fr (S)	NL	NL	NL	FM	

all of these patients showed normal to increased cortical thickness and an irregular, bumpy gyral pattern with shallow sulci (Fig. 1). All had diminished underlying cerebral hemispheric white matter. Two patients had serologic evidence of congenital infections and one had multiple brain anomalies.

Focal Cortical Dysplasia

Birth history was available for seven patients with focal cortical dysplasia. One was born prematurely (33 weeks). Two infants born at term showed failure to progress during labor and were delivered by cesarean section. One of the patients delivered by cesarean section and one of the infants born at term delivered vaginally were depressed at birth and were felt to have suffered birth injury. Patients were referred for MR because of new onset of seizures, change in seizure pattern, or developmental delay. No significant difference was apparent in the reasons for referral of the patients with unilateral focal cortical dysplasia compared with those with bilateral focal

cortical dysplasia. On MR, all patients with focal cortical dysplasia showed cortical thickening, ranging from 5–9 mm thickness (normal equals 3–5 mm (4)) with irregular, bumpy inner and outer cortical surfaces, broad gyri, and shallow sulci. This appearance has been described previously (5, 10) in conjunction with cortical dysplasia secondary to anomalies of neuronal migration. The cortical dysplasia involved the sylvian fissure in 25 of 43 affected hemispheres (58%). The appearance in some patients was that of a focally thickened cortex (15 hemispheres, Fig. 2), which often extended abnormally high into the hemisphere (Fig. 3). In other areas, the cortical dysplasia appeared as an infolding of abnormally thickened cortex (19 hemispheres, Figs. 3 and 4). In some patients (9 hemispheres, Fig. 3) both appearances were present. When the dysplasia was continuous with the sylvian fissure, the fissure appeared to extend all the way to the top of the hemisphere on parasagittal images through the sylvian region (Fig. 4). Areas of prolonged T2 relaxation were present in the underlying white matter in seven patients (23%).

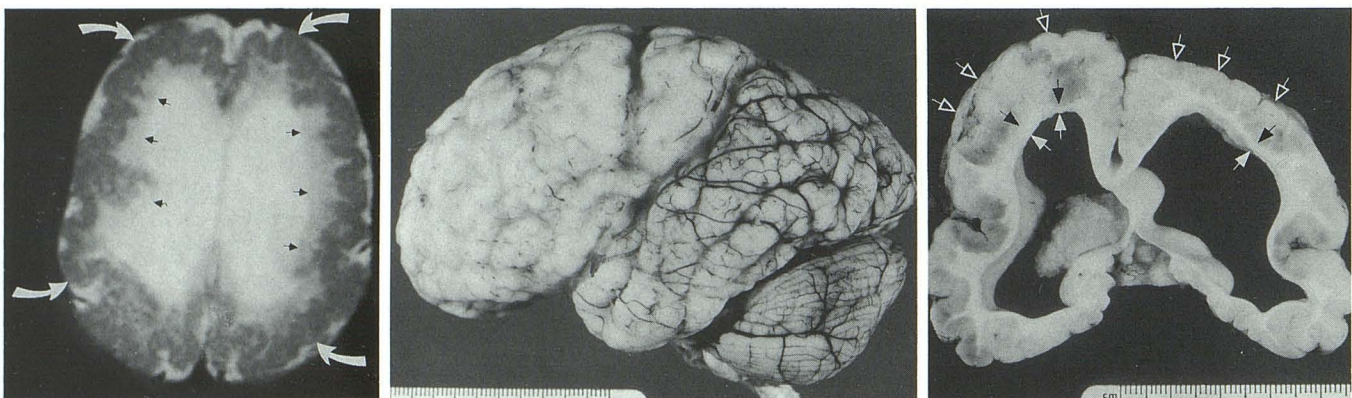


Fig. 1. Patient 2; diffuse cortical dysplasia.

A, Axial long TR/TE image shows diffusely abnormal cortex (*curved white arrows*), which is abnormally thickened with an irregularly bumpy gyral pattern. Diminished white matter (*black arrows*) is seen underlying the cortex. The speckled appearance of the cortex is artifactual.

B, Uncut fixed brain shows a diffusely abnormal gyral pattern, with multiple irregular small gyri and shallow sulci.

C, Cut brain section shows abnormally thick cortex (*open arrows*) with an irregularly bumpy inner and outer cortical surfaces. Diminished white matter (*closed arrows*) separates the cortex from the enlarged lateral ventricles.

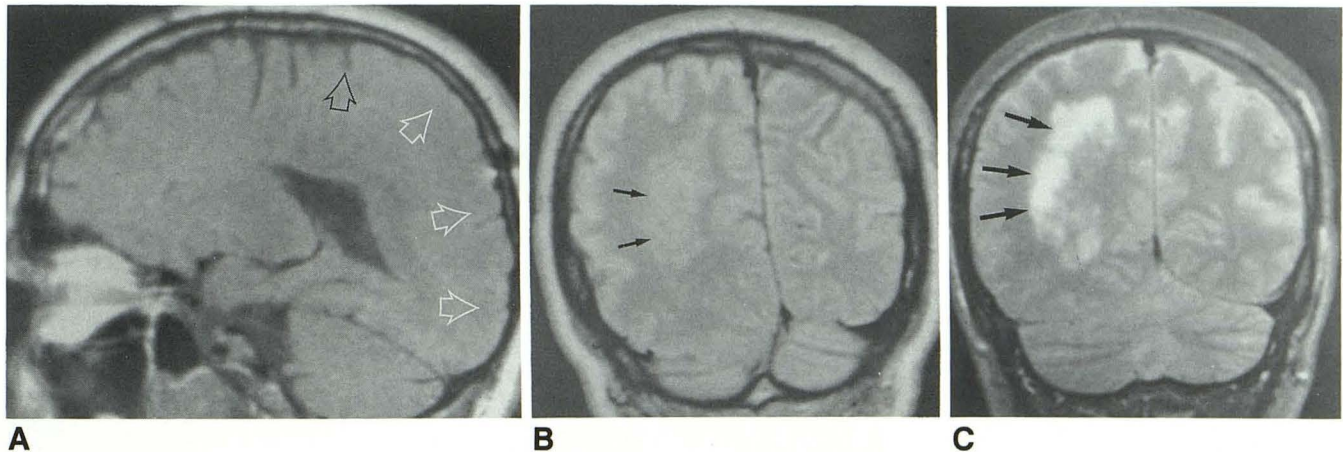


Fig. 2. Patient 30; focal cortical dysplasia.

A, Parasagittal short TR/TE sequence shows a lack of normal gyri and sulci in the left posterior frontal, parietal, and occipital lobes (white arrows). Black arrow points to the central sulcus.

B, Coronal long TR/short TE image shows thickened cortex with shallow sulci and an irregularly bumpy gyral pattern. Compare with the normally thin cortex and deep sulci on the contralateral (left) side. Some heterotopic gray matter (arrows) is present deep in the white matter underlying the abnormal cortex.

C, Coronal long TR/TE image 2 1/2 cm anterior to (B) shows prolongation of T2 relaxation time (arrows) suggestive of gliosis in the deep white matter.

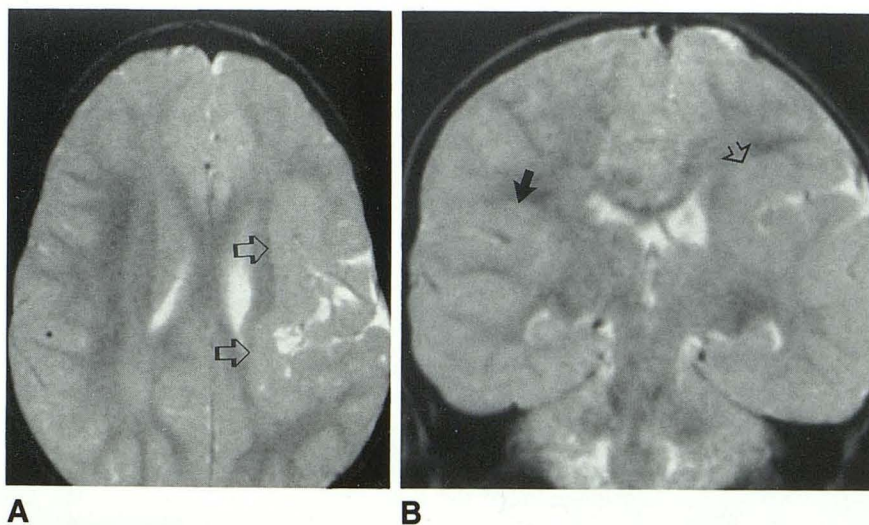


Fig. 3. Patient 31; focal cortical dysplasia.

A, Axial long TR/TE image at the level of the bodies of the lateral ventricles shows the left sylvian fissure extending abnormally high into the cerebral hemisphere. The insular cortex (arrows) is abnormally thick.

B, Coronal long TR/TE image at the posterior sylvian fissure level shows the sylvian cortex (open arrow) extending abnormally high into the left hemisphere (compare with the level of the normal right sylvian fissure (closed arrow)). At this level the cortical dysplasia appears as an infolding of cortex. The relative lack of white matter on the left and the slightly enlarged left lateral ventricle may reflect the in utero injury that caused the anomalous neuronal migration.

Bilateral Focal Cortical Dysplasia. Of 12 patients (24 hemispheres) with bilateral focal cortical dysplasia, eight hemispheres had only frontal lobe involvement, eight had isolated parietal lobe involvement, two had disease limited to the occipital lobes, five had frontoparietal involvement, and one had temporoparietal involvement. The areas of dysplasia were symmetrical in eight patients and asymmetrical in four. Patients with bilateral dysplasia presented at a young age (median age at the time of MR was 2 years) with motor dysfunction, developmental delay, or seizures. All nine patients with involvement of the posterior frontal lobes (motor cortex) had spastic

motor dysfunction; conversely, the three patients in whom the posterior frontal lobes were spared did not. The two patients with late onset of seizures were the two oldest in this group.

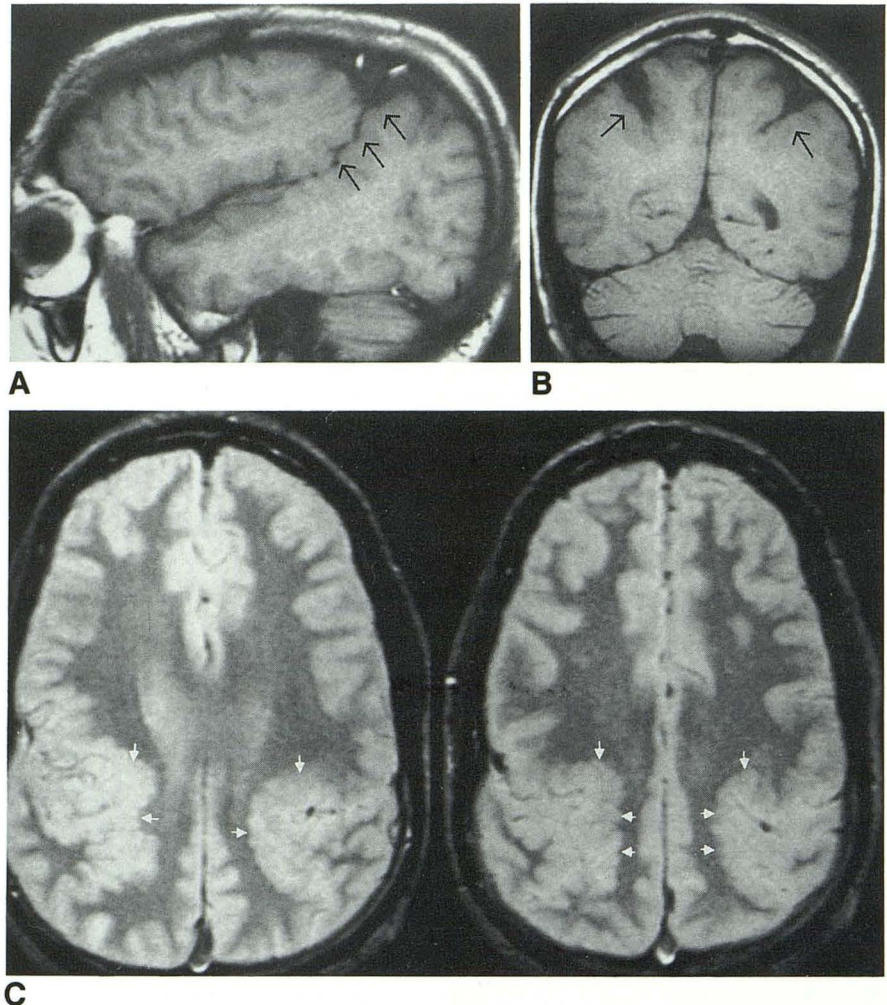
Right Focal Cortical Dysplasia. The 13 patients in this group had predominantly frontal (six patients) and frontoparietal (three patients) involvement. In addition, single patients had occipital, fronto-parieto-occipital, temporo-occipital, and temporo-frontal involvement. These patients presented at older ages (median age at time of scanning was 8 years) and were less severely affected than the other groups. Speech was delayed in one patient but developed normally in

Fig. 4. Patient 14; bilateral focal cortical dysplasia.

A, Short TR/TE parasagittal image shows continuity of the left frontoparietal area of cortical dysplasia (*arrows*) with the posterior portion of the sylvian fissure.

B, Coronal short TR/TE image shows the bilateral cortical infoldings (*arrows*). Note that the infoldings are lined by abnormally thick cortex with irregular inner surfaces.

C, Axial long TR/short TE images at the level of the centrum ovale. Bilateral cortical infoldings (*arrows*) composed of thick cortex with abnormally irregular inner surfaces are present in the posterior frontal-anterior parietal regions bilaterally.



the other eight who were old enough to evaluate. Two patients were considered to have normal intelligence and eight others were considered only mildly delayed (IQ or DQ 70 to 90). Motor deficits were absent in all patients without posterior frontal lobe involvement.

Left Focal Cortical Dysplasia. Of the six patients with left focal cortical dysplasia, three patients had exclusive frontal lobe involvement, two had fronto-parietal involvement, and one had temporo-fronto-parietal involvement. These patients were scanned at a median age of 3 years old. This group had the highest percentage of smaller lesions, with 50% judged to be either small or medium in size. Speech was normal in four of the six (100% of those with smaller lesions), four of six were developmentally normal (100% with smaller lesions), and two had normal motor examinations (both with small lesions).

Statistical Analyses

Only two correlations were found to be statistically significant: speech delay was significantly

more common in infants with bilateral hemispheric involvement than unilateral ($P = .005$) and motor dysfunction was significantly associated with frontal lobe involvement ($P = .03$). It is noteworthy that this analysis is not based on a random sampling of patients, but on a selected group (selected in that they were chosen to be examined by MR). These factors should be kept in mind in the utilization of this data, as outlined below in the discussion.

Discussion

It appears from this study as though the clinical consequences of cortical dysplasia relate in some degree to the extent and location of cortical involvement: those patients with diffuse involvement presented earliest and did most poorly, those with bilateral focal involvement were older at presentation and had less severe motor and cognitive dysfunction, and those with unilateral focal involvement had the least motor, cognitive, and speech dysfunction. Moreover, those patients with frontal lobe involvement were significantly

more likely to have motor dysfunction. As expected, the posterior frontal lobe (motor cortex) seems to be the critical area for motor function, as the three patients with frontal lobe involvement but normal motor function all had less than two-thirds of the frontal lobe involved (with sparing of the motor region).

The fact that speech was abnormal in all patients with diffuse or bilateral involvement and normal in almost all patients with focal right hemispheric involvement was not surprising, as speech is usually considered a left hemispheric function. In fact, left sylvian cortical dysplasia has been previously reported in a patient with developmental dysphasia (11). More surprising was the normal development of speech in four of the six patients with focal left hemispheric involvement. In patients 35 and 36, a possible explanation is the focal, prefrontal location of the lesion; the speech centers, located around the sylvian fissure, were spared. Much more difficult to explain is the normal development of speech in patients 31 and 32. Both of these children had abnormalities that clearly involved the primary motor speech area (Broca's area), as well as the insular cortex which is also postulated to be involved in the speech process (12). One possible explanation for this phenomena is that both of these patients had dominant right hemispheres, either genetically or as a result of the injury to the left hemisphere. In fact, injury to the left hemisphere has been proposed as a cause of left handedness in some patients (12). Thus, the presence of normal speech in these children may be a manifestation of neuronal plasticity (ie, other areas of brain taking over functions of damaged ones (13)), a concept that developed from the observation of recovery of function after brain injury. In fact, it has been shown that dendrites from nearby ganglion cells will grow into an area of damaged brain to establish an active contact with nearby undamaged axons (14). The exact mechanism of this reestablishment of synapsis is not known, but it is clear that this plasticity is greater in younger patients than in older patients (13, 14). It is reasonable to postulate, therefore, that neuronal and dendritic adaptation and synaptic regeneration in response to a midgestational injury such as a neuronal migration anomaly would be very significant. If one invokes neuronal plasticity as the cause for normal speech development, one must question why compensation for damage to the motor regions is not equally effective. One possibility is that the motor system

has less inherent plasticity; if so, the diminished plasticity of the motor system may explain why motor dysfunction is more severe than intellectual dysfunction in premature infants with periventricular white matter damage and in infants with hypoxic ischemic injury (15). Another possibility would be that the motor system, which is phylogenetically (and presumably ontogenetically) much older than speech, is formed and its connections established prior to the time of the cortical injury and that, therefore, establishment of alternative pathways is more difficult.

It is necessary to comment upon the patient selection for this study. This study is biased in the sense that the patients were selected by the clinicians' decision to obtain imaging studies. Therefore, it is likely that some very severely affected patients were too young or too ill to scan and were eliminated. Similarly, it is possible that a subset of patients with subclinical or clinically mild anomalies were not scanned. It may be possible, for example, that patients without seizures were underrepresented. Similarly, patients with posterior frontal lesions may be overrepresented as the result of their very clinically apparent motor dysfunction. Finally, we are limited by the imaging technique and by the index of suspicion and diagnostic acuity of the radiologists who originally reviewed these studies. Several abnormalities may not be apparent on MR scans or may be missed if scans in the proper plane are not obtained (16).

We have intentionally used the nonspecific term "cortical dysplasia" in this paper because the terms "pachygyria" and "polymicrogyria" are histologic descriptions and differentiation of the two can at times be difficult on both gross pathologic study and on MR exam. The four pathologically proven cases in this study (patients 2, 23, 26, and 35), however, all had polymicrogyria and the authors believe that the large majority, if not all, of the patients described herein had polymicrogyria.

Nine patients in this study (25%) had areas of prolonged T2 relaxation time in their hemispheric white matter underlying the damaged cortex. One of them (patient 26) had resection of the damaged cortex that included some of the underlying white matter. On histologic exam, the white matter showed an abnormally large number of astrocytes ("gliosis"), indicating previous damage. It has been demonstrated that the glial response of the brain to injury is very limited before approximately 26 weeks gestational age (17, 18). Therefore, it

seems likely that the injury to the white matter in this subset of patients took place at or after approximately 26 weeks gestational age. This result would seem to support the findings of Evrard et al (19) that polymicrogyria can result from injuries as late as the end of the second trimester, or even the early third trimester. Another possibility is that an ongoing infection or injury may have caused the white matter damage sometime after the cortical damage occurred.

Other studies have commented on the high incidence of congenital infections in patients with polymicrogyria and other focal anomalies of neuronal migration (10, 19). We found clinical or serologic evidence of congenital infection in only four of 36 patients in this series. Perhaps the low number encountered is the result of the high percentage of focal lesions in the present series; indeed two of five patients with diffuse cortical dysplasia had evidence of congenital infection. Possibly, focal cortical dysplasia is the result of a mild infection, which may not otherwise be clinically apparent or provoke serologic studies. Alternatively, other injuries, such as focal ischemia or toxic exposures more often cause focal dysplasia, whereas diffuse dysplasia may be more often caused by infection.

It is notable that the five patients with diffuse cortical dysplasia had severe developmental and motor disabilities, similar to that in patients with type I lissencephaly (4, 7, 20, 21). All these patients presented in the first year of life with developmental delay. All were hypotonic at birth, with subsequent development of hypertonicity and spasticity in the three oldest patients. Four were microcephalic; the lone exception was patient 1, who was normocephalic despite the presence of hydrocephalus. Three of the five had infantile spasms and the oldest patient had myoclonic seizures. In view of the clinical similarities, all anomalies of neuronal migration with diffuse cortical involvement should be classified together, regardless of the anatomic or histologic characteristics of the cortex.

Seizure control was a major problem in eight of the 10 patients over the age of 10 years in this series. The differentiation of diffuse from focal cortical dysplasia is becoming important in the management of patients with intractable seizure disorders. The fact that poor seizure control diminishes the quality of life is well established. Moreover, it is suspected that poor seizure control leads to progressive brain damage (15). As a result, a number of centers (including this one)

are now surgically resecting focal areas of cortical dysplasia in patients with medically refractory seizures (22). Corpus callosotomies are performed in patients with bilateral focal dysplasia and "drop attacks." Initial results are encouraging: most patients achieve much improved medical control of their seizures without worsening neurologic deficit.

As a result of the increasing surgical role in these disorders, the radiologist assumes an important role in their detection. Careful scrutiny of the images is necessary in order to discover the region of dysplastic cortex. The most common appearances are (1) an abnormally thick cortex with diminished sulcal depth and an irregularly bumpy gyral pattern (Fig. 2), or (2) an abnormally deep infolding of thickened cortex (Fig. 4). The latter appearance is particularly easily missed when in the region of the sylvian fissure; one must be especially suspicious of an abnormally thick cortex, or an abnormally high extension, of the sylvian fissure (Fig. 3).

To summarize, we have analyzed the radiologic and clinical features of 36 patients with cortical dysplasia other than classical type I or type II lissencephaly. The dysplasia may be focal or diffuse. When diffuse, clinical presentation is very similar to that of type 1 lissencephaly. When focal, the clinical presentation varies depending upon the extent and location of the cortical anomaly; some degree of motor dysfunction is almost always present. Unilateral cortical dysplasia seems to have the best prognosis, particularly if the motor cortex is not involved. Focal anomalies can be subtle on imaging studies, particularly when sylvian or perisylvian in location. As surgical treatment of these patients becomes more common, the neuroradiologist will play an increasingly important role in the diagnosis of these anomalies.

References

1. Zimmerman R, Bilaniuk L, Grossman R. Computed tomography in migration disorders of human brain development. *1983;25:257-263*
2. Barth PG. Disorders of neuronal migration. *Can J Neurol Sci* 1987;14:1-16
3. Barkovich AJ, Chuang SH, Norman D. MR of neuronal migration anomalies. *AJNR* 1987;8:1009-1017
4. Barkovich AJ, Koch TP, Carrol CL. The spectrum of lissencephaly: report of 10 cases analyzed by MRI. *Ann Neurol* 1991;30:139-146
5. Barkovich AJ, Chuang SH. Unilateral megalencephaly: correlation of MR imaging and pathologic characteristics. *AJNR* 1990;11:523-531
6. Byrd SE, Bohan TP, Osborn RE, Naidich TP. The CT and MR evaluation of lissencephaly. *AJNR* 1988;9:923-927
7. Dobyns WB. The neurogenetics of lissencephaly. *Neurol Clin* 1989;7:89-105.

8. Barkovich AJ, Kjos BO, Jackson J D.E., Norman D. Normal maturation of the neonatal and infant brain: MR imaging at 1.5 T. *Radiology* 1988;166:173-180
9. Fried R. Introduction to statistics. New York: Gardner Press, 1976:304
10. Titelbaum DS, Hayward JC, Zimmerman RA. Pachygyriclike changes: topographic appearance at MR imaging and CT and correlation with neurologic status. *Radiology* 1989;173:663-667
11. Cohen M, Campbell R, Yaghai F. Neuropathological abnormalities in development dysphasia. *Ann Neurol* 1989;25:567-570
12. Adams R, Victor M. *Principles of neurology*. 2nd ed. New York: McGraw-Hill, 1981:1094
13. Lenn N. Neuroplasticity and the developing brain: implications for therapy. *Pediatr Neurosci* 1987;13:176-183
14. Perry V, Maffei L. Dendritic competition: competition for what? *Dev Brain Res* 1988;41:195-208
15. Volpe J. *Neurology of the newborn*. Philadelphia: Saunders, 1987
16. Barkovich AJ, Norman D. MR of schizencephaly. *AJNR* 1988;9:297-302
17. Gilles FH, Leviton A, Dooling EC, eds. The developing human brain: *growth and epidemiologic neuropathology*. Boston: Wright, 1983
18. Gilles FH. Neuropathologic indicators of abnormal development. In: Freeman J, ed. *Prenatal and perinatal factors associated with brain disorders*. Bethesda: NIH Publication No. 85-1149, 1985
19. Evrard P, de Saint-Georges P, Kadhim H, Gadsseux J-F. Pathology of prenatal encephalopathies. In: French J, ed. *Child neurology and developmental disabilities*. Baltimore: Paul H. Brookes, 1989:153-176
20. de Rijk-van Andel J, Arts W, Barth P, Loonen M. Diagnostic features and clinical signs of 21 patients with lissencephaly type 1. *Dev Med Child Neurol* 1990;32:707-717
21. Dobyns WB, Kirkpatrick JB, Hittner HM, Roberts RM, Kretzer FL. Syndromes with lissencephaly. II. Walker, Warburg and cerebral occular muscular syndromes and a new syndrome with Type 2 lissencephaly. *Am J Med Genet* 1985;22:157-195
22. Kuzniecky R, Berkovic S, Andermann F, Melanson D, Olivier A, Robitaille Y. Focal cortical myoclonus and rolandic cortical dysplasia: clarification by magnetic resonance imaging. *Ann Neurol* 1988; 23:317-325

Note: Please see the Commentary by Barth on page 104 in this issue.