

MR Signal Abnormalities at 1.5 T in Alzheimer's Dementia and Normal Aging

Franz Fazekas¹
 John B. Chawluk²
 Abass Alavi¹
 Howard I. Hurtig²
 Robert A. Zimmerman¹

The type, frequency, and extent of MR signal abnormalities in Alzheimer's disease and normal aging are a subject of controversy. With a 1.5-MR unit we studied 12 Alzheimer patients, four subjects suffering from multiinfarct dementia and nine age-matched controls. Punctate or early confluent high-signal abnormalities in the deep white matter, noted in 60% of both Alzheimer patients and controls, were unrelated to the presence of hypertension or other vascular risk factors. A significant number of Alzheimer patients exhibited a more extensive smooth "halo" of periventricular hyperintensity when compared with controls ($p = .024$). Widespread deep white-matter hyperintensity (two patients) and extensive, irregular periventricular hyperintensity (three patients) were seen in multiinfarct dementia. Areas of high signal intensity affecting hippocampal and sylvian cortex were also present in five Alzheimer and two multiinfarct dementia patients, but absent in controls. Discrete, small foci of deep white-matter hyperintensity are not characteristic of Alzheimer's disease nor do they appear to imply a vascular cause for the dementing illness. The frequently observed "halo" of periventricular hyperintensity in Alzheimer's disease may be of diagnostic importance. High-signal abnormalities in specific cortical regions are likely to reflect disease processes localized to those structures.

Alzheimer's disease is estimated as the underlying cause in 50–60% of dementia cases [1]. Therefore, it represents a serious health problem for the elderly, with about 15% of those over 65 demonstrating some degree of dementia [2]. Although the ability to diagnose Alzheimer's disease clinically has improved [3], there is still a need to increase the accuracy of in vivo diagnosis. MR imaging has shown unprecedented sensitivity in detecting pathologic changes of the brain and has the potential to contribute to this goal.

The occurrence of white-matter signal abnormalities on MR has been noted with increasing age [4–6], and extensive white-matter damage has been demonstrated in patients suffering from presumed vascular dementia [5, 7, 8]. However, reports dealing with the MR appearance of Alzheimer's disease have been anecdotal and controversial. Whereas some investigators have found no signal abnormalities in Alzheimer's disease [9], others have reported almost as many abnormalities as are seen in multiinfarct dementia (MID) [10]. More information is needed to evaluate fully the potential of MR in the diagnosis of dementia.

This report attempts to describe the type and frequency of signal abnormalities that may be observed in patients with a clinical diagnosis of Alzheimer's disease and contrasts these with findings in healthy elderly controls and patients with MID. To our knowledge this is the first time a high-field MR system has been used to address this question.

Subjects and Methods

The 25 subjects in this study were selected from a group of elderly individuals currently under investigation at our institution for cerebral abnormalities associated with normal aging

This article appears in the May/June 1987 issue of *AJNR* and the August 1987 issue of *AJR*.

Received September 19, 1986; accepted after revision December 9, 1986.

This work was supported by NIA Teaching Nursing Home grant P01AG03934 and NIH Clinical Research Center grant 5-M01RR00040.

¹ Department of Radiology, Divisions of Nuclear Medicine and Neuroradiology, Hospital of the University of Pennsylvania, 3400 Spruce St./G1, Philadelphia, PA 19104. Address reprint requests to A. Alavi (Nuclear Medicine).

² Department of Neurology, Cerebrovascular Research Center, Hospital of the University of Pennsylvania, Philadelphia, PA 19104.

AJNR 8:421–426, May/June 1987

0195–6108/87/0803–0421

© American Society of Neuroradiology

and dementia. These subjects were carefully screened by a neurologist and underwent a comprehensive laboratory evaluation consisting of an automated blood chemistry battery, tests for vitamin B12 deficiency and thyroid dysfunction, as well as ECG, electroencephalogram, and chest radiograph. All subjects underwent CT, MR, and positron emission tomography scanning. The mini-mental state examination [11] and the Blessed dementia scale [12] were included as part of the neuropsychological test battery.

In 12 subjects a diagnosis of Alzheimer's disease was established according to clinical diagnostic criteria set forth in the DSM III (*Diagnostic and Statistical Manual of Mental Disorders*) [13] and expanded on by an NINCDS-ADRDA consensus committee [14]. All Alzheimer patients scored 2 or less on a modification of Hachinski's vascular dementia scale [15] and demonstrated no other clinical cause for their dementing illness. In four other demented subjects a Rosen-Hachinski score [15] of greater than 4 suggested a multiinfarct state as the cause of dementia. Impairment was defined by mini-mental state examination scores as mild (>20), moderate (11–20), and severe (10 or less). Nine healthy elderly control subjects were also studied and were found to be free of any neurologic, psychiatric, or major systemic illnesses, although one subject had diabetes and two had a history of hypertension. The mean ages in these groups were 69 (Alzheimer), 70 (MID), and 68 (healthy controls) years old, respectively.

MR was performed on a General Electric imaging unit with a superconducting magnet to generate a field strength of 1.5 T. Image acquisition was performed with a spin-echo technique, the pulse

sequences being repetition time (TR) 600–800 msec/echo time (TE) 20–25 msec for T1-weighted and TR 1500–2500 msec/TE 25–120 msec for T2-weighted images. Sagittal, axial, and coronal scans were available in every subject and interpreted by a neuroradiologist blinded to the clinical diagnosis.

A modification of suggested rating scales [5, 6] was used to describe the different types of hyperintense signal abnormalities surrounding the ventricles and in the deep white matter. Periventricular hyperintensity (PVH) was graded as 0 = absence, 1 = "caps" or pencil-thin lining, 2 = smooth "halo," 3 = irregular PVH extending into the deep white matter. Separate deep white matter hyperintense signals (DWMH) were rated as 0 = absence, 1 = punctate foci, 2 = beginning confluence of foci, 3 = large confluent areas.

The occurrence of these types of abnormality as well as the presence of other signal intensity changes were recorded for dementia patients (Alzheimer and MID) and controls, and compared among the groups. The effects of age, vascular risk factors, and dementia severity on the degree and nature of the signal abnormalities were assessed.

Results

MR revealed a variety of signal abnormalities in controls, as well as in patients with Alzheimer's disease and MID. These findings together with the subjects' clinical data are listed in Table 1 and are discussed below.

TABLE 1: Clinical Features and MR Findings in Alzheimer's Disease, Multiinfarct Dementia, and Normal Aging

Group: Case No.	Age	Duration (years)	Severity	Risk Factors	Grade		Other
					PVH	DWMH	
Probable Alzheimer's disease:							
1	70	3	Mild	H, CAD	2	0	CH
2	66	3	Mild	H	0	0	...
3	66	3	Moderate	H	2	0	...
4	77	6	Moderate	...	2	0	CH
5	80	4	Moderate	...	1	2	CH
6	61	3	Severe	...	1	1	...
7	68	10	Severe	H	1	2	...
Possible Alzheimer's disease:							
8	52	1	Mild	...	0	0	...
9	62	6	Moderate	...	2	2	CH
10	71	2	Moderate	...	2	2	CH
11	77	3	Moderate	H, D	1	1	...
12	73	5	Severe	...	2	1	...
Multiinfarct dementia:							
13	64	6	Mild	H	3	3	BGL, I
14	74	3	Moderate	H, CAD	3	3	BGL, CH
15	63	3	Moderate	H	3	2	I
16	80	1	Severe	H	1	1	BGL, CH
Control:							
17	52	D	0	1	...
18	70	1	1	...
19	64	0	0	...
20	61	H	0	0	...
21	68	0	2	...
22	76	1	0	...
23	76	1	2	BGL
24	83	H	3	2	...
25	65	0	0	...

Note.—PVH = periventricular hyperintensity; DWMH = deep white-matter hyperintensity; H = hypertension; CAD = coronary artery disease; CH = cortical hyperintensity; D = diabetes mellitus; BGL = basal ganglionic lesions; I = "classical" infarcts (infarcts confined to typical vascular territories).

Periventricular Hyperintensity

In controls, areas of abnormal high signal intensity around the ventricles were either absent or seen as caps or a pencil-thin lining of periventricular hyperintensity (PVH) (Fig. 1). The sole exception was a grade-3 PVH pattern in a healthy 83-year-old individual with a history of hypertension. PVH was noted in 10 of 12 Alzheimer subjects, with six showing a halo (Fig. 2C) of high signal intensity around the ventricles. The proportion of Alzheimer patients with a PVH score of 2 was significantly different from that in controls (Table 2). In contrast

to Alzheimer patients and controls, three MID subjects (75%) showed an irregular PVH extending into the deep white matter (Fig. 3B).

Deep White-Matter Hyperintensity

The incidence and extent of deep white-matter hyperintensity (DWMH) seen in Alzheimer patients was comparable to that observed in controls. About 60% of all subjects had some foci of DWMH. However, confluent areas of DWMH (Fig. 3) were present only in MID (two patients) (Table 2).

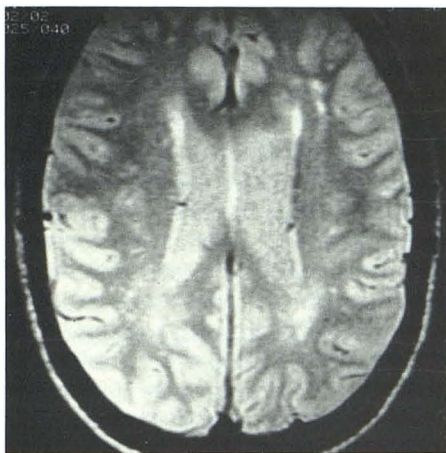


Fig. 1.—Case 18: 70-year-old male control subject with no vascular risk factors. Pencil-thin line of hyperintensity (grade 1) surrounds ventricles. Punctate foci of high signal intensity (grade 1) in deep white matter.

TABLE 2: Incident and Extent of MR Abnormalities in Alzheimer's Disease, Multiinfarct Dementia, and Normal Controls

Abnormality	No. of Patients		
	Controls	Alzheimer's disease	Multiinfarct Dementia
Periventricular hyperintensity (grade):			
0-1	8	6	1
2	0	6*	0
3	1	0	3
Deep white-matter hyperintensity (grade):			
0	4	5	0
1	2	3	1
2	3	4	1
3	0	0	2
Type of lesion:			
Cortical hyperintensity	0	5	2
Basal ganglionic foci	1	0	3
Infarct	0	0	2

* The proportion of Alzheimer patients with grade 2 periventricular hyperintensity differs significantly from that in controls ($p = .024$).

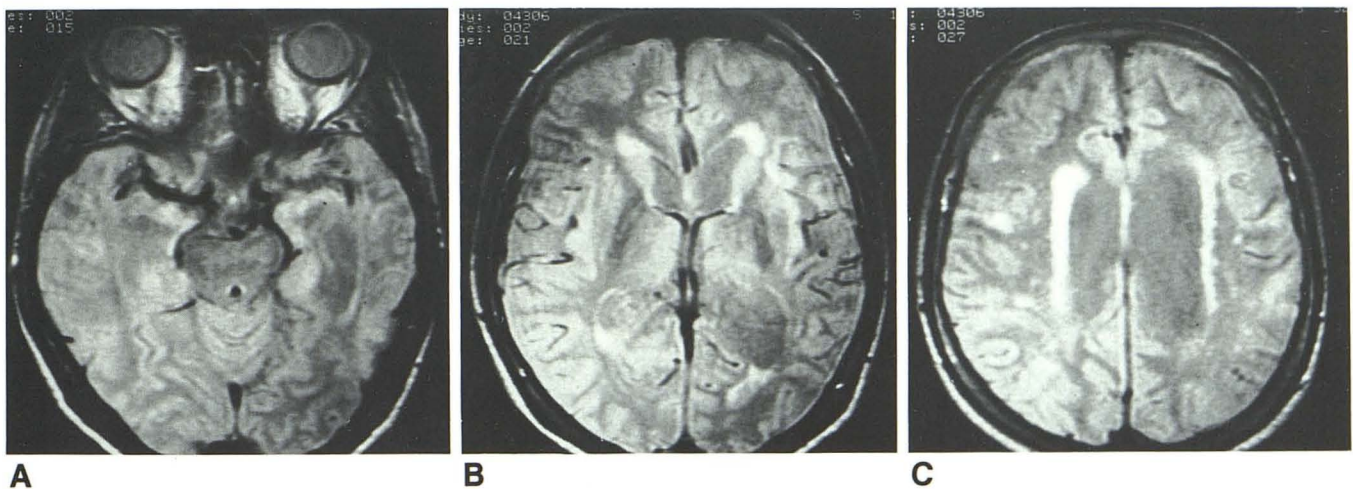


Fig. 2.—Case 9: 62-year-old woman with Alzheimer's disease and no vascular risk factors.
 A, Signal intensity of hippocampal cortex is increased bilaterally.
 B, Sylvian cortex on left and right are of high signal intensity; hyperintense areas are present at tips of ventricles.
 C, Smooth halo of hyperintensity (grade 2) surrounds ventricles; punctate foci of high signal intensity are noted in subcortical white matter. Beginning confluence of these foci (not shown) was present on more inferior sections.

Miscellaneous Findings

Areas of high signal intensity in cortical regions were also noted on some MR studies. In five Alzheimer patients the cortex of the sylvian and/or hippocampal-uncal regions appeared bright on T2-weighted images (Figs. 2A and 2B). Similar changes were seen in two MID subjects but were not seen in any of the controls. MR of Alzheimer subjects revealed no basal ganglionic lesions or "classical" infarcts. However, such abnormalities were common in MID (Table 2).

Correlation of MR Findings with Clinical Data

The presence of a halo of PVH in Alzheimer subjects was not correlated with the severity of dementia, nor was there a correlation of dementia severity with any other signal abnormality detected in these individuals. There was no relationship between a type 1 or 2 PVH or DWMH and vascular risk factors (see Table 1). There was a history of hypertension, however, in all subjects with an irregular PVH extending into the deep white matter or with confluent areas of DWMH (grade 3 lesions). PVH and DWMH were observed more often in the older subjects in this series, but the presence or type of white-matter signal abnormality could not be predicted on the basis of a subject's age. All subjects without any PVH abnormalities, however, were younger than 70 years.

Discussion

In recent years the routine neuroimaging study of the brain in Alzheimer's disease has been CT, the aim being to exclude possible treatable causes of the dementia. Otherwise, the

capabilities of CT in supporting the diagnosis of Alzheimer's disease have been restricted to imaging diffuse cerebral atrophy considered inappropriate for the patient's age. Reports on changes in brain density with Alzheimer's disease have been controversial [16, 17].

Early experience with MR has already demonstrated its greater sensitivity in detecting cerebral abnormalities in comparison with CT [18, 19]. This is particularly true for white-matter lesions, which can be detected readily by highlighting T2 relaxation with a long spin-echo pulse-sequence method [20]. The possibility of a distinct white-matter disorder in Alzheimer's disease reported recently in a pathoanatomic study by Brun and Englund [21] supports the rationale of applying MR in the evaluation of this disease. Nevertheless, the number of white-matter signal abnormalities observed in Alzheimer's disease in this study is somewhat surprising.

Our results support the observation that foci of high signal intensity in the deep white matter are commonly seen in clinically normal elderly individuals [5, 22]. In contrast to a report by Erkinjuntti et al. [9], a similar frequency and extent of such deep white-matter lesions were seen in Alzheimer patients. The more extensive signal changes in the deep white matter seen in two of our MID patients were recently described with vascular dementia [7, 8]. In our series such widespread lesions were not present either in Alzheimer patients or in controls. Therefore, such a finding should rule against a diagnosis of pure Alzheimer's disease. The extensive deep white-matter changes observed in an 85-year-old Alzheimer patient with a gait disturbance in the series of George et al. [22] presumably reflects marked vascular damage in addition to Alzheimer's disease. Therefore, this case would be classified as a mixed type of dementia [23], a speculation supported by the neuropathologic observations

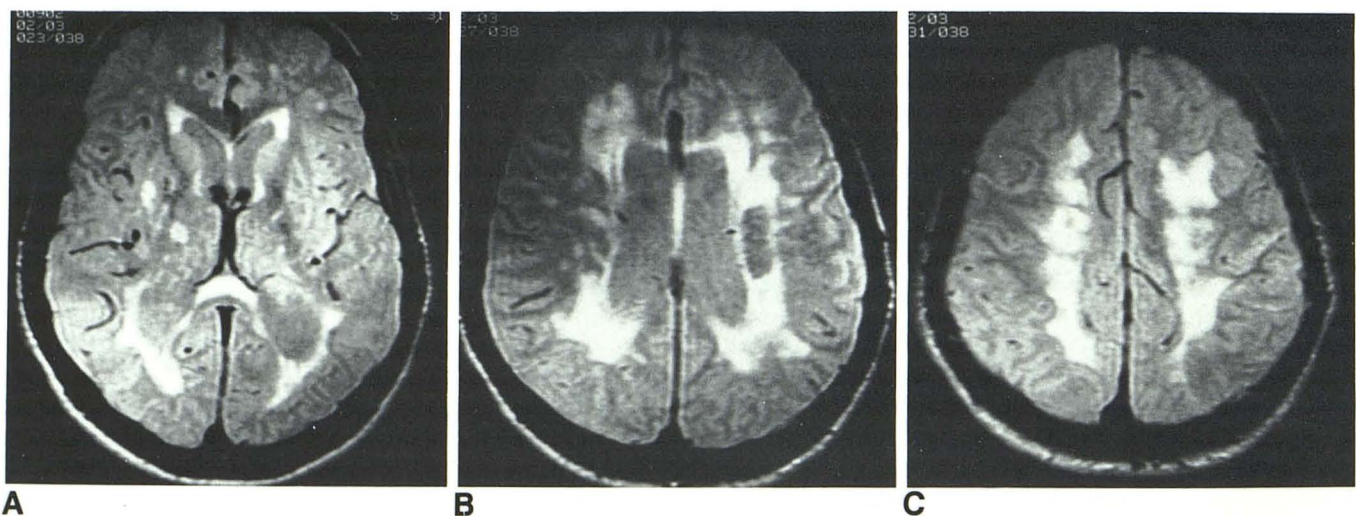


Fig. 3.—Case 13: 64-year-old man with multiinfarct dementia and history of hypertension.
 A, Two hyperintense lesions in right putamen and thalamus; punctate foci of hyperintensity in left basal ganglia. Areas of hyperintensity surround tips of ventricles.
 B, Diffuse irregular hyperintensity surrounds ventricles and extends into deep white matter (grade 3).
 C, Confluent lesions of high signal intensity (grade 3) involve almost entire supraventricular deep white matter.

of similar patients by the same authors [24]. In our experience the smaller white-matter lesions (punctate foci of hyperintensity or even beginning confluence of DWMH) are of no value in distinguishing Alzheimer patients from controls.

The white-matter signal abnormalities we have seen in our Alzheimer patients do not appear to be identical to the white-matter pathology described by Brun and Englund [21]. They observed large, diffuse, predominantly symmetric areas in the deep white matter with partial loss of axons, myelin sheaths, and oligodendroglial cells, accompanied by a mild reactive astrocytosis; in our series MR revealed only punctate or slightly confluent areas of high signal abnormality. Either these lesions do not produce enough change in tissue proton arrays to be fully detected by MR—their pathologic appearance being different from pronounced ischemic damage—or they have not been present in our patients. Pathologically confirmed severe ischemic changes in the deep white matter have been shown to cause extensive signal hyperintensity [7].

The similar extent, frequency, and distribution of the deep white-matter signal abnormalities seen in both healthy elderly individuals and Alzheimer patients suggest a common etiology. Possibilities include local ischemia or focal parenchymal degeneration due to aging. Whereas the presence of vascular risk factors was not correlated with the occurrence of such minor signal abnormalities, all patients (cases 13, 14, 15, and 24) with extensive deep white-matter disease or irregular PVH extending into the deep white matter (grade 3) had a history of hypertension.

The most distinctive finding in Alzheimer's disease in this study was a halo of high signal intensity surrounding the ventricles. This abnormality was detected in 50% of Alzheimer patients and was not present in controls or MID. In a review of 365 cerebral cases studied by MR, a similar pattern of PVH was invariably associated with a specific disease process, for example, hydrocephalus, supratentorial neoplasms, trauma, and rarely white-matter disease [6]. Given the smooth margin of this halolike abnormality, it seems unlikely that ischemia or demyelination would be the cause. It may rather represent an exaggeration of a similar process that has been hypothesized to cause the pencil-thin lining of PVH, more often observed in older subjects with otherwise normal MR studies [6]. This latter hypothesis is supported by our data, since all patients without PVH were younger than 70 years. It has been suggested that the periventricular subependymal lining of hyperintensity reflects an increase in interstitial water reabsorption from the white matter into the ventricles [6]. This explanation is consistent with the observation that caps of PVH seem to be present first, since the area that has to be drained of interstitial water will be greatest for the tips of the ventricles. In patients with Alzheimer's disease this bulk flow to the ventricles would therefore seem to be further enhanced. Unfortunately, no studies directly address the question of interstitial water content in Alzheimer's disease, although there is some indirect support from previous radiologic studies. Besson et al. [25], calculating the proton density of white matter on MR scans, reported a water content of white matter in Alzheimer's disease that was significantly increased over that of both controls and MID patients. Similarly, the finding

of decreased white-matter density on CT [16] is consistent with increased interstitial water. White-matter changes such as those described by Brun and Englund [21] might be the underlying pathologic substrate, and MR might detect their distant effects as increased periventricular water rather than as the actual lesion.

Although its pathologic basis may not be clear, the appearance of the halo of hyperintensity in Alzheimer's disease is an important empirical observation. To date this pattern of PVH has been mostly ascribed to hydrocephalus [6] and has been claimed to be a very reliable diagnostic sign in normal-pressure hydrocephalus [26]. Since normal-pressure hydrocephalus might be considered in the differential diagnosis of Alzheimer's disease, yet requires substantially different management, the notion of a similar PVH pattern in Alzheimer's disease may be critical. Our subjects suffering from Alzheimer's disease had no clinical or radiologic signs suggestive of normal-pressure hydrocephalus.

On the basis of the above discussion, one may speculate that the rim of PVH in normal subjects widens with advancing age, making it similar to that of Alzheimer patients. Our experience with MR in normal patients over 80 years old is too limited to evaluate this possibility.

In accordance with pathologic [23] and CT data, MR detected no typical infarcts or basal ganglionic lesions in Alzheimer patients. Such abnormalities were also absent in controls, except for a tiny lenticular nucleus signal abnormality seen in one normal individual. Basal ganglionic lesions seem to be an important feature in MID, however, confirming previous CT reports [27].

Areas of cortical hyperintensity were present in five Alzheimer and two MID patients. It is likely that such abnormalities affecting the hippocampus reflect changes that have occurred in the cortical structure. A disturbed quantitative relationship of neurons to glia and associated degenerative changes (that is, a high number of senile plaques and fibrillary tangles) may be the basis for these signal-intensity changes. The topography of these histopathologic alterations seen in Alzheimer's disease corresponds well with the hippocampal hyperintensity detected on MR [28]. Congophilic angiopathy affecting cortical vessels with secondary parenchymal changes may represent another possible explanation for the observed hyperintense cortical signals. Pathologically those changes have been reported to occur less often in the hippocampus, however, than in other regions of the brain [29].

In summary, MR has demonstrated its ability to detect parenchymal changes in the brains of Alzheimer patients who have not been seen before with high-resolution CT. The implication of a signal abnormality differs with its type. Small discrete foci of DWMH are neither characteristic of Alzheimer's disease nor do they implicate a vascular cause of dementia, since they are seen to a similar extent in healthy elderly individuals. Furthermore, these punctate lesions appear to be unrelated to the presence of vascular risk factors. A smooth halo of PVH, however, is a distinctive finding in Alzheimer's disease. Areas of cortical signal hyperintensity observed in Alzheimer patients may reflect the disease process itself.

REFERENCES

1. Terry RD, Katzman R. Senile dementia of the Alzheimer type. *Ann Neurol* **1983**;14:497-506
2. Katzman R. The prevalence and malignancy of Alzheimer disease. *Arch Neurol* **1976**;33:217-218
3. Ron MA, Toone BK, Garralda ME, Lishman WA. Diagnostic accuracy in presenile dementia. *Br J Psychiatry* **1979**;134:161-168
4. Bradley WG Jr, Waluch V, Brant-Zawadzki M, Yadley RA, Wycoff RR. Patchy, periventricular white matter lesions in the elderly: a common observation during NMR imaging. *Noninvasive Med Imaging* **1984**;1:35-41
5. Brant-Zawadzki M, Fein G, Van Dyke C, Kiernan R, Davenport L, de Groot J. MR imaging of the aging brain: patchy white-matter lesions and dementia. *AJNR* **1985**;6:675-682
6. Zimmerman RD, Fleming CA, Lee BCP, Saint-Louis LA, Deck MDF. Periventricular hyperintensity as seen by magnetic resonance: prevalence and significance. *AJNR* **1986**;7:13-20, *AJR* **1986**;146:443-450
7. Kinkel WR, Jacobs L, Polachini I, Bates V, Heffner RR Jr. Subcortical arteriosclerotic encephalopathy (Binswanger's disease). Computed tomographic, nuclear magnetic resonance, and clinical correlations. *Arch Neurol* **1985**;42:951-959
8. Alavi A, Fazekas F, Chawluk J, Zimmerman R. Magnetic resonance imaging of the brain in normal aging and dementia. Presented at the Conference on Cerebrovascular Disease, Salzburg, Austria, September **1986**
9. Erkinjuntti T, Sipponen JT, Iivanainen M, Ketonen L, Sulkava R, Sepponen RE. Cerebral NMR and CT imaging in dementia. *J Comput Assist Tomogr* **1984**;8:614-618
10. Cherryman GR, Gemmill HG, Sharp PF, Besson JAO, Crawford J, Smith FW. NMR demonstration of white matter changes in the watershed area of patients with dementia. Correlation with psychiatric evaluation and J-123-isopropylamphetamine cerebral blood flow imaging. Presented at the international meeting of the Society of Magnetic Resonance in Medicine, London, August **1985**
11. Folstein MF, Folstein SE, McHugh PR. "Mini-mental state": a practical method for grading the cognitive state of patients for the clinician. *J Psychiatr Res* **1975**;12:189-198
12. Blessed G, Tomlinson BE, Roth M. The association between quantitative measures of dementia and of senile change in the cerebral gray matter of elderly subjects. *Br J Psychiatry* **1968**;114:797-811
13. American Psychiatric Association. *Diagnostic and statistical manual of mental disorders*, 3d ed. Washington, DC: American Psychiatric Association, **1980**
14. McKhann G, Drachman D, Folstein M, Katzman R, Price D, Stadlan EM. Clinical diagnosis of Alzheimer's disease. *Neurology* **1984**;34:939-944
15. Rosen WG, Terry RD, Fuld PA, Katzman R, Peck A. Pathological verification of ischemic score in differentiation of dementias. *Ann Neurol* **1980**;7:486-488
16. Naeser MA, Gebhardt C, Levine HL. Decreased computerized tomography numbers in patients with presenile dementia. *Arch Neurol* **1980**;37:401-409
17. George AE, de Leon MJ, Ferris SH, Kricheff II. Parenchymal CT correlates of senile dementia (Alzheimer disease): loss of gray-white matter discriminability. *AJNR* **1981**;2:205-213
18. Bradley WG, Waluch V, Yadley RA, Wycoff RR. Comparison of CT and MR in 400 patients with suspected disease of the brain and cervical spinal cord. *Radiology* **1984**;152:695-702
19. Baker HL, Berquist TH, Kispert DB, et al. Magnetic resonance imaging in a routine clinical setting. *Mayo Clin Proc* **1985**;60:75-90
20. Brant-Zawadzki M, Norman D, Newton TH, et al. Magnetic resonance of the brain: the optimal screening technique. *Radiology* **1984**;152:71-77
21. Brun A, Englund E. A white matter disorder in dementia of the Alzheimer type: a pathoanatomical study. *Ann Neurol* **1986**;19:253-262
22. George AE, de Leon MJ, Kalnin A, Rosner L, Goodgold A, Chase N. Leukoencephalopathy in normal and pathologic aging: 2. MRI of brain lucencies. *AJNR* **1986**;7:567-570
23. Tomlinson BE, Blessed G, Roth M. Observations on the brains of demented old people. *J Neurol Sci* **1970**;11:205-242
24. George AE, de Leon MJ, Gentes CI, et al. Leukoencephalopathy in normal and pathologic aging: 1. CT of brain lucencies. *AJNR* **1986**;7:561-566
25. Besson JAO, Corrigan FM, Foreman I, Eastwood LM, Smith FW, Ashcroft GW. Nuclear magnetic resonance (NMR): 2. Imaging in dementia. *Br J Psychiatry* **1985**;146:31-35
26. Kortman KE, Bradley WG. Magnetic resonance imaging of normal pressure hydrocephalus. Presented at the annual meeting of the American Society of Neuroradiology, New Orleans, February **1985**
27. Ladurner G, Iliff LD, Sager WD, Lechner H. A clinical approach to vascular (multiinfarct) dementia. In: Meyer JS, Lechner H, Reivich M, Ott EO, eds. *Cerebral vascular disease 4*. Amsterdam: Excerpta Medica, **1983**:236-243
28. Englund E, Brun A. Senile dementia—a structural basis for etiological and therapeutic considerations. In: Perris C, Struwe G, Jansson B, eds. *Biological psychiatry*. Amsterdam: Elsevier, **1981**:951-956
29. Vinters HV, Gilbert JJ. Cerebral amyloid angiopathy: incidence and complications in the aging brain. 2. The distribution of amyloid vascular changes. *Stroke* **1983**;14:924-928