

Retinal Wada Test

Joseph A. Horton¹ and Robert C. Dawson III²

The interventionist needs precise information about the tissue supplied by an artery that is to be embolized. With intracranial arteriovenous malformations (AVMs), Amytal* can be used to challenge cerebral arteries and their branches [1]. Cranial nerves are physiologically and histologically like peripheral nerves, so external carotid artery branch embolization can be controlled by challenge with intraarterial lidocaine[†] [2]. Doppman [3] has reported that the spinal cord, like the brain, is exquisitely sensitive to Amytal.

We recently had occasion to embolize an ophthalmic artery whose branches fed an extremely vascular frontal meningioma (Fig. 1). It was necessary to ascertain in advance whether this could be done safely by using the more preferred agent, gelfoam powder,[‡] which can pass into the capillary bed of the tumor (Kerber CW, personal communication), or the alternative, large particles of polyvinyl alcohol (PVA) foam,[§] which stop short of that point and occlude the arterioles. We knew that if our slowest injection rate would be likely to result in flow to the globe, then it would be necessary to use particles larger than the lumen of the retinal artery to prevent embolization of the retina. This is exactly analogous to the particle-size strategy for embolizing spinal cord AVMs [4].

The right ophthalmic artery was selectively catheterized by transfemoral approach. The feeder vessels themselves were as large as the ophthalmic artery trunk, but could not be individually catheterized. We determined that a small artery was supplying the retina beyond the origin of these feeder vessels. Since near-exsanguination had occurred on an earlier attempt to operate, the desirability of tumor devascularization was obvious. Amytal in a dose of 5 mg was injected through the catheter without causing a loss of visual acuity. After 5 min, 0.5 ml of 1% lidocaine (5 mg) mixed with a like volume of iohexol was injected, and an irregular but definite scotoma was grossly detectable. This resolved in 2 min. As in the case of testing external carotid artery branches before embolization, we opacified the lidocaine so that we could be certain that it would not reflux into the internal carotid system and possibly precipitate a seizure.

The choice of Amytal and lidocaine doses was based on our previous experience with these drugs in testing arteries to be embolized [2]. In particular, we wanted to inject an amount that would be adequate enough both to have a definite physiologic effect and to replace blood flow completely for at least 2 sec so that the concentrated drug would perfuse through the tissue to be provoked. This approach is purely empirical: in our experience, it has produced no false-negative results over several hundred trials in the external carotid artery.

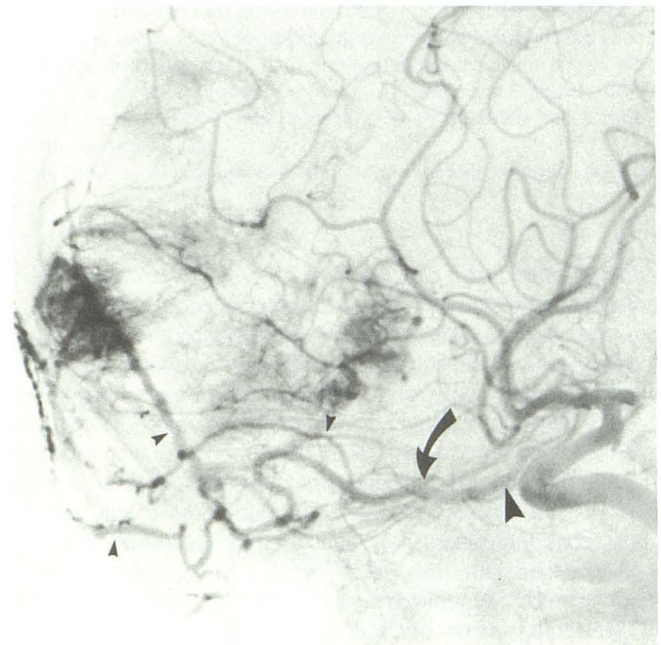


Fig. 1.—An enlarged ophthalmic artery (*large arrowhead*) gives rise to at least three arteries (*small arrowheads*) supplying this highly vascular meningioma. At the time of embolization the catheter was at the point indicated by *curved arrow*. Injection of 5 mg of lidocaine caused gross but spotty visual loss. A like dose of Amytal had no noticeable effect.

* Eli Lilly, Inc., Indianapolis, IN.

[†] Elkins-Sinn, Inc., Cherry Hill, NJ.

[‡] Upjohn, Inc., Kalamazoo, MI.

[§] Pacific Medical Industries, Inc., San Diego, CA.

Received September 23, 1987; accepted after revision March 1, 1988.

¹ Department of Radiology, Presbyterian-University Hospital, University of Pittsburgh School of Medicine, Pittsburgh, PA 15213. Address reprint requests to J. A. Horton.

² Department of Radiology, Our Lady of Lourdes Hospital, Lafayette, LA 70502.

Because our patient developed a scotoma, we elected to use PVA particles, 300–500 μm in size, rather than powdered gelfoam to embolize the feeders. Aliquots of emboli were used, and the patient's vision was assessed constantly. At no time during the embolization did the patient's vision change. When flow to the tumor feeders had slowed but not stopped, the catheter was withdrawn. The tumor was totally resected, with approximately 200 ml of blood loss.

On the basis of our experience with this single case, it seems that the retina is more sensitive to lidocaine than it is to Amytal, if it is sensitive to the barbiturate at all. If the ophthalmic artery or an artery from which it may have an anomalous origin must be embolized, testing with lidocaine may help in the choice of embolic agents. In retrospect, it is sensible that lidocaine and specifically not Amytal would be effective in this setting: a Wada test involves injection of a

rather large dose of Amytal below the origin of the ophthalmic artery; there is rarely even transient monocular blindness.

ACKNOWLEDGMENT

We thank Stephen Goldware, without whose support and insistence this research would not have been possible.

REFERENCES

1. Wada J, Rasmussen T. Intracarotid injection of sodium Amytal for the lateralization of cerebral speech dominance. *J Neurosurg* **1960**;17:266–282
2. Horton JA, Kerber CW. Lidocaine injection into external carotid branches: provocative test to preserve cranial nerve function in therapeutic embolization. *AJNR* **1986**;1:105–108
3. Doppman J. Spinal Wada test. *Radiology* **1986**;161:319–321
4. Horton JA, Latchaw RE, Gold LHA, Pang D. Embolization of intramedullary arteriovenous malformations of the spinal cord. *AJNR* **1986**;7:113–118