

Cranial CT in Children and Adolescents with Diabetic Ketoacidosis

William H. Hoffman¹
 Curt M. Steinhart¹
 Taher El Gammal²
 Sharon Steele¹
 Angel R. Cuadrado¹
 P. Kenneth Morse³

To determine the effects of diabetic ketoacidosis on the brain, we studied nine consecutive patients between the ages of 6 and 17 years by performing cranial CT on three occasions: on admission, before treatment; 6–8 hr after beginning treatment; and 7 days after admission. Both the pretreatment scans and those at 6–8 hr showed significantly reduced size of the lateral and third ventricles in comparison with the 7-day scans. A comparison of the pretreatment scans with those done at 6–8 hr showed no statistically significant differences.

We conclude that the cerebral swelling of diabetic ketoacidosis is usually present before treatment.

Brain edema associated with diabetic ketoacidosis is an acute complication seen primarily in children and adolescents, and has an associated high morbidity and mortality [1, 2]. Recently, Krane et al. [3] reported that subclinical brain swelling was a consistent finding on the basis of cranial CT of six patients 7–12 hr after initiation of fluid and insulin therapy, the time when clinical brain edema is most likely to occur.

The cause of this complication is unknown; however, theories on its etiology have focused on (1) a too-rapid correction of osmotic disequilibrium [4]; (2) alteration of the blood-brain barrier by insulin [5, 6]; (3) hypoxia [7]; and (4) overhydration [1] and hyponcotic states [8].

Although clinical manifestations of hyperosmolality and dehydration are well recognized, information on the effects of these states on the brain is limited. This study was undertaken to provide further insight into the effects of diabetic ketoacidosis and ketosis on the brain before initiation of treatment, and to assess the evolution of subclinical brain swelling.

Materials and Methods

Cranial CT scans were performed on nine consecutive patients with diabetic ketosis or ketoacidosis. There were five girls and four boys ages 6 ½ to 17 ½ years old. Three of the patients were newly diagnosed, and six had known diabetes mellitus. Ketonuria was present for intervals ranging from 3 hr to 2 weeks in previously diagnosed patients. Diabetic ketoacidosis was defined as a blood glucose level of over 250 mg/dl, an arterial pH of less than 7.30, a serum bicarbonate of less than 15 mEq/l and a positive urinary sodium nitroprusside reaction. Ketosis was defined as the presence of serum and urine ketones with a normal serum bicarbonate and pH.

On arrival at the emergency room, a history was taken and a physical examination was performed; an intraarterial and/or IV line was established; and baseline laboratory data were obtained. After obtaining informed consent, the patient was taken immediately to the Neuro-radiology Department for axial cranial CT. CT scans were acquired with a GE 9800 CT scanner (kV 120, mA 140; field of view 23 cm; scan time 3 sec; 512 × 512 matrix). Before each CT was done, a digitized lateral skull film was obtained to preselect the levels and angle of the sections. This method allowed for consistency in the levels and degree of angulation

Received July 28, 1987; accepted after revision December 8, 1987.

This work was supported by the Department of Pediatrics Research Fund and the T.M. Research Fund.

¹ Department of Pediatrics, Section of Pediatric Endocrinology, Medical College of Georgia, Augusta, GA 30912. Address reprint requests to W. H. Hoffman.

² Department of Radiology, Medical College of Georgia, Augusta, GA 30912.

³ Department of Dental Education, School of Dentistry, Medical College of Georgia, Augusta, GA 30912.

AJNR 9:733–739, July/August 1988
 0195–6108/88/0904-0733

© American Society of Neuroradiology

for each of the three scans and minimized intraindividual variation. The slices were 1 cm thick, and sections were contiguous. All scans were performed by the same technologist.

After CT, patients in ketoacidosis were taken to the Pediatric Intensive Care Unit. The initial IV fluid was normal saline at a rate of 10–20 ml/kg for the first hour. Thereafter, the patient received a constant rate of IV fluids and electrolytes, based on the calculated maintenance and deficit with potassium being replaced as half chloride and half phosphate. Correction of dehydration was over a period of 24–36 hr. We used an IV insulin regimen of 0.1 units/kg/hr for previously diagnosed patients in ketoacidosis and 0.05 units/kg/hr for newly diagnosed patients, beginning 1–2 hr after initial hydration. IV insulin was continued until the patients were no longer acidotic. No patient received sodium bicarbonate. During their stay in the Pediatric Intensive Care Unit, patients were evaluated neurologically by nurses every hour using the Glasgow Coma Scale. Patients who were not acidotic received the same fluid regimen, with the exception that they did not receive the initial hydration of 10–20 ml/kg for the first hour. Their insulin regimen was administered subcutaneously, and they were treated on a General Pediatric Unit. Repeat CT scans were obtained 6–8 hr after beginning insulin therapy, and again at discharge, 6–7 days later. One patient (case 3) had an additional CT 26 hr after initiation of insulin, because of signs and symptoms of brain edema. All patients were neurologically normal at the time of discharge.

The study was designed so that scans were reviewed immediately by one of the staff physicians involved in the patient's treatment. Readings by the neuroradiologist were done with no knowledge of the patients' clinical status with regard to ketosis/acidosis or state of hydration. The diameters of the lateral ventricle and third ventricles were determined, with the former diameter measured as the distance between the caudate nuclei [3]. Statistical analysis was performed by separate, repeated-measures analysis of variance tests for both the lateral and third ventricle diameters, with the three occasions considered to be repeated measures on the same subject. When the F-statistic for occasions proved to be significant ($p < .001$ for the lateral ventricle; and $p < .01$ for the third ventricle), follow-up paired t-tests were run for each pair of occasions. The test comparing the 6–8-hr study with the time-of-discharge study was a planned comparison, testing a one-sided hypothesis (time three > time two) as previously reported by Krane et al. [3]. The remaining two t-tests represented post hoc testing without a hypothesis. Consequently, for time one vs time two, and for time one vs time three, the nominal alpha value of 0.05 was adjusted to 0.025 to avoid inflation of type I error.

Results

Pretreatment Measurements vs Time-of-Discharge Measurements

Pretreatment scans showed a significant reduction of the lateral and third ventricles in comparison with the scans at the time of discharge ($p < .008$ and $< .02$, respectively). A reduction in the size of both lateral and third ventricular measurements was present in seven of nine patients when pretreatment and discharge CT scans were compared. Eight of nine patients showed a reduction in lateral ventricle measurements, and seven of nine patients showed a reduction in the third ventricle measurement in comparison with the discharge measurements (Fig. 1). The mean decrease in ventric-

ular dimensions for the five patients with acidosis and dehydration was 3.7 ± 1.0 mm for the lateral ventricle and 1.5 ± 1.0 mm for the third ventricle.* The mean decrease in ventricular dimensions for the four patients without acidosis and dehydration was 0.7 ± 0.7 mm for the lateral ventricle and 0.4 ± 0.6 mm for the third ventricle.

6–8-Hour Measurements vs Time-of-Discharge Measurements

Scans obtained 6–8 hr after treatment also revealed a significant reduction in size of the lateral and third ventricles in comparison with scans obtained at discharge ($p < .001$ and $< .01$, respectively). All nine patients showed a reduction in lateral ventricle measurements, and seven of nine showed a reduction in third ventricle measurements in comparison with the discharge measurements. The mean decrease and standard deviation in ventricular dimensions for the patients with acidosis and dehydration was 4.3 ± 1.4 mm for the lateral ventricle and 1.3 ± 0.6 mm for the third ventricle. The mean decrease in ventricular dimensions for the patients without acidosis and dehydration was 1.8 ± 1.0 for the lateral ventricle and 0.2 ± 0.2 mm for the third ventricle.

Pretreatment Measurements vs 6–8-Hour Measurements

At the second scan, no statistically significant change was demonstrated for either ventricle. When comparing the initial and second CT scans, accentuation of brain swelling, with a reduction in size of both the lateral and third ventricles, was observed in four of the nine patients. A reduction in the size of the lateral ventricles occurred in seven of nine patients, and a reduction of the third ventricle occurred in five of nine patients. The mean decrease in ventricular dimensions for the patients with acidosis and dehydration was 0.5 ± 1.5 mm for the lateral ventricle and 0.12 ± 0.8 mm for the third ventricle. The mean decrease in ventricular dimensions for the patients without acidosis and dehydration was 1.1 ± 0.6 mm for the lateral ventricle and 0.1 ± 0.4 mm for the third ventricle. Figures 2 and 3 show the variation in response of the lateral and third ventricles between the initial, second, and discharge CT scans. Only one patient, case 2, showed an increase in both lateral and third ventricle measurements between the initial and second CT scan.

In one patient (case 3), who developed clinical brain edema 23 hr after initiation of insulin treatment, a third CT scan obtained 3 hr after the onset of signs and symptoms and treatment with IV mannitol, and 1 hr after the resolution of those symptoms, showed a further decrease in the size of the fourth ventricle and obliteration of the subarachnoid space around both the quadrigeminal plate and the quadrigeminal cistern (Figs. 4–6).

No CT scans showed evidence of cerebral thrombosis or infarction [9]. Of the CT scans obtained on discharge, there

* These calculations exclude one patient who was only mildly acidotic and dehydrated; i.e., CO_2 17 mEq/l; pH 7.27 and BUN 15 mg/dl. Ventricular measurements for this patient were included in the nonacidotic group.

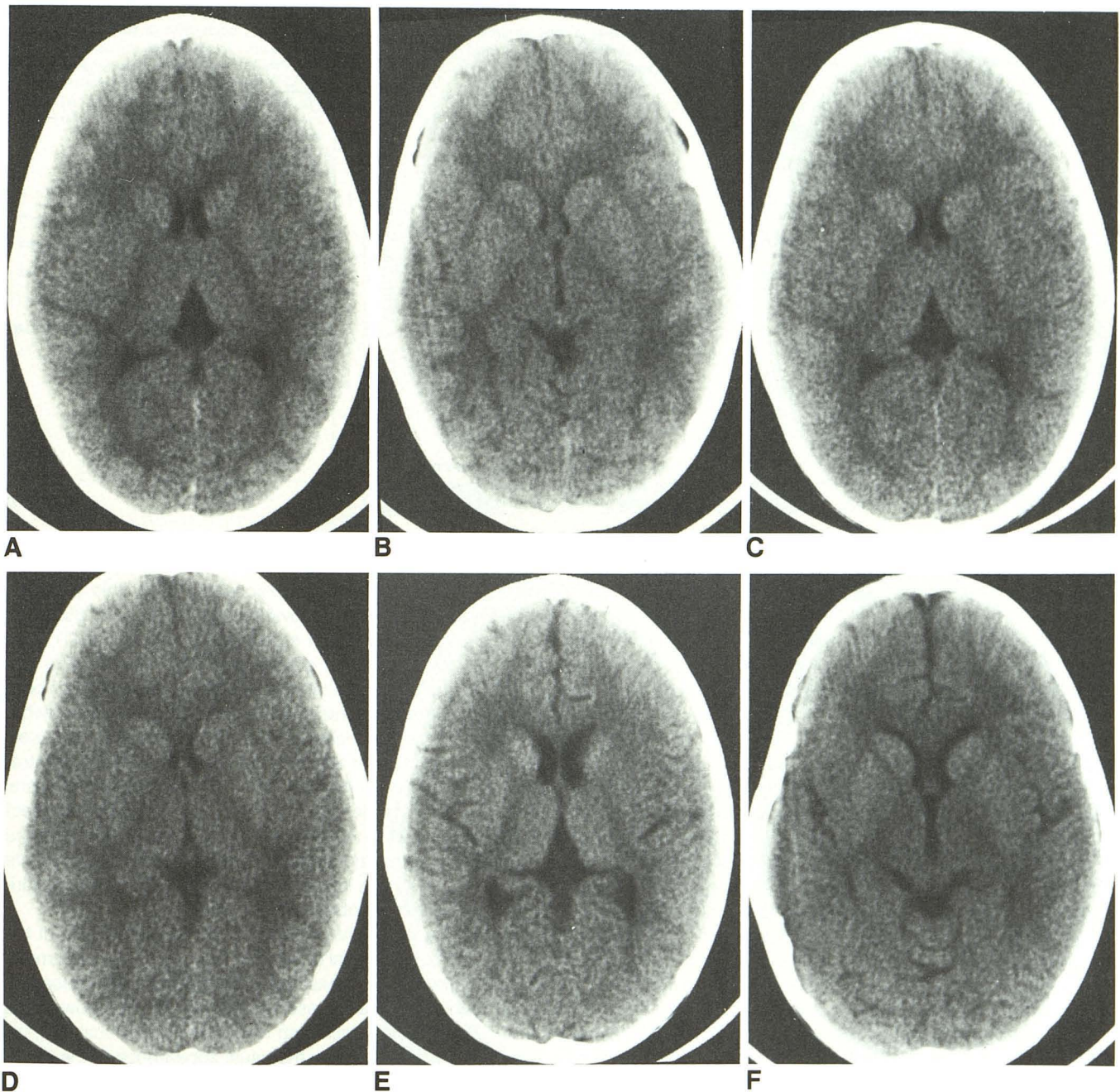


Fig. 1.—A-F, Case 6: typical changes in lateral and third ventricles caused by brain edema. Scans at admission (A and B), at 6-8 hr (C and D), and at 6 days (E and F). Reduction in ventricles is most apparent at 6-8 hr. Note in E and F the normal anterior longitudinal fissure and the superior cerebellar cisterns that were previously compressed by brain edema in A-D.

was no difference between the ventricular measurements of patients who had repeated past episodes of diabetic ketoacidosis and those who were newly diagnosed. The admission laboratory value ranges for six patients in ketoacidosis were as follows: blood glucose 403-746 mg/dl; serum Na 124-138 mEq/l; serum K 4.0-5.7 mEq/l; serum Cl 88-105 mEq/l; serum CO₂ 4-17 mEq/l; serum pH 6.97-7.27; BUN 15-32 mg/dl; and serum osmolarity 292-318 mosmol/kg. The range

of laboratory values for three patients in ketosis were: blood glucose 293-379 mg/dl; serum Na 134-139 mEq/l; serum K 3.8-4.3 mEq/l; serum Cl 92-108 mEq/l; serum CO₂ 20-26 mEq/l; serum pH 7.39-7.45; BUN 14-23 mg/dl; and serum osmolarity 298-302 mosmol/kg. Blood chemistry results showed the expected changes with treatment. Glasgow Coma scores showed no correlation with blood chemistries or ventricular measurements.

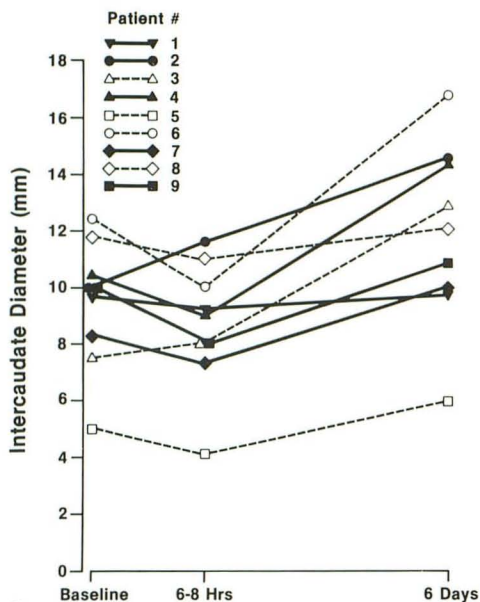
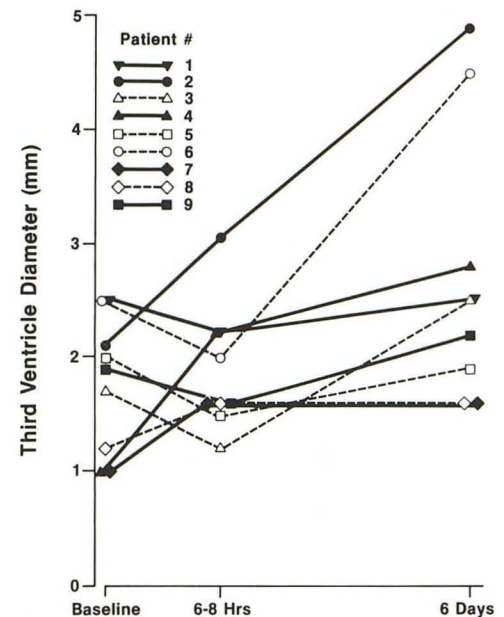


Fig. 2.—Intercaudate diameter (lateral ventricles) in nine patients on admission; changes at 6–8 hr into treatment, and at 6 days.

Fig. 3.—Diameter of third ventricle in nine patients on admission; changes at 6–8 hr into treatment, and at 6 days.



2

3

Discussion

Our CT scan results extend the observations of Krane et al. [3] by confirming that brain swelling is present during treatment of diabetic ketosis/acidosis. More important, our data demonstrate for the first time that brain swelling is frequently present before treatment.

A recent report on the epidemiology of diabetic coma showed a strong correlation between the degree of acidosis, hyperglycemia, and dehydration, with comatose patients having the more severe metabolic derangement [10]. Our blood chemistry data do not allow us to comment on a definite correlation with the presence of brain swelling at the time of admission, since patients with both ketosis and acidosis had CT evidence of swelling on admission and during treatment. An arbitrary separation of patients based on a pH of < 7.25 and a BUN > 15 mg/dl showed a greater mean difference for both lateral and third ventricles between the first and third CT scans as well as between the second and third CT scans than for patients with a pH of 7.25 or greater and a BUN of 15 mg/dl or less. However, the presence of brain swelling in one patient, case 7, who had ketosis but a normal pH and CO₂ content, indicates that peripheral metabolic acidosis is not a prerequisite for the development and/or progression of swelling. In comparison, another patient, case 1, had almost identical laboratory data but did not have CT evidence of swelling on admission, although CT did reveal a decrease in the size of both ventricles at 6–8 hr.

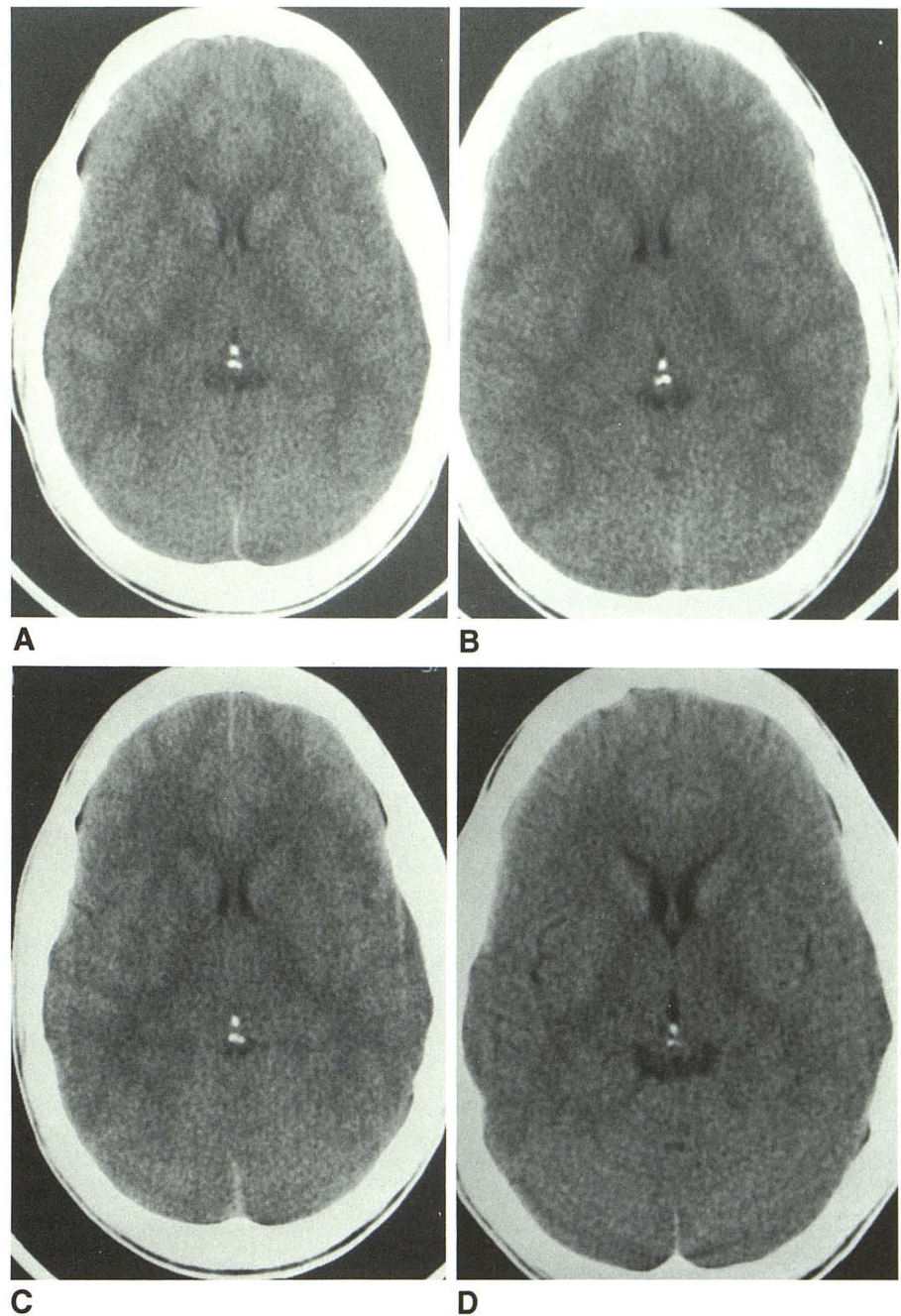
One patient with known diabetes, case 3, was diagnosed as having clinical brain edema at 23 hr on the basis of the onset of a severe headache progressing to obtundation, along with a drop in heart rate and an elevation in blood pressure. On admission she was drowsy but not comatose. Her course was not predictable on the basis of either the initial CT or Glasgow Coma scores; however, in keeping with the report

on the epidemiology of diabetic coma [10], this patient's serum pH of 6.9 was the lowest, and her BUN of 35 mg/dl the highest of any patient studied. We believe her CT 3 hr after the onset of brain edema and 2 hr 40 min after the administration of IV mannitol is indicative of swelling of both the cerebral hemispheres and the cerebellum. The somewhat enlarged lateral ventricles on the 26-hr scan are very likely due to obstruction of the aqueduct and an increase in intraventricular pressure. An alternative explanation for the lateral ventricular enlargement on the 26-hr scan could be the effect of the (IV) mannitol, which was administered 20 min after the onset of the signs and symptoms of the cerebral edema. We believe the latter is a less likely explanation, since the quadrigeminal cistern was obliterated at 26 hr.

Toutant et al. [11] have reported on the importance of the appearance of the basal cisterns in predicting the outcome of patients who have increased intracranial pressure caused by head injury, as well as an association with the Glasgow Coma Scale. Because the brainstem was not routinely scanned, we are unable to comment on the usual appearance of the fourth ventricle or the basal cisterns on admission or during treatment. However, of the five additional patients for whom the fourth ventricle could be examined, only one other patient had a decrease in the size of that ventricle on both of the first two scans. That patient had an uneventful clinical course.

We have no definite explanation for the increased ventricular size at 6–8 hr in patient 2. However, his treatment varied from the other patients in that the period of hydration prior to his first CT and receipt of insulin was 4 hr, compared with 1 or 2 hr for the other patients. This delay occurred because he was referred from a distance and had received no insulin before arriving at our institution. It is also reasonable to assume, based on our current knowledge of clinical cerebral edema in diabetic ketoacidosis, that there may be individual characteristic responses to treatment.

Fig. 4.—A–D, Case 3: changes in lateral ventricular size. Scans at admission (A) and at 6–8 hr (B) demonstrate small lateral ventricles compared with scan at 6 days (D). Scan at 26 hr (C) shows lateral ventricles to be larger than at admission (A) and at 6–8 hr (B) but smaller than at 6 days (D).



We have also had the opportunity to perform CT scans on a patient with hypernatremic dehydration caused by nephrogenic diabetes insipidus prior to treatment and 2 weeks after correction. Initial lateral and third ventricular measurements revealed enlarged ventricles, both of which decreased after treatment. This patient's brain contraction and enlarged ventricles are consistent with what is believed to be the initial response of the brain to hyperosmolar dehydration unrelated to hyperglycemia [12]. The CT results suggest that with comparable hyperosmolar loads, the pathophysiology involv-

ing the brain in the acute, untreated hyperosmolar state of hypernatremia differs from that in the untreated state of hyperglycemia associated with ketosis/acidosis.

Our study does not clarify the pathophysiology of this life-threatening complication of diabetic ketoacidosis, nor does it identify which patients will develop clinical brain edema. However, the demonstration of brain swelling prior to treatment in some patients with diabetic ketosis and acidosis in both newly and previously diagnosed patients suggests an osmotic disequilibrium, perhaps caused by a breakdown of the blood-

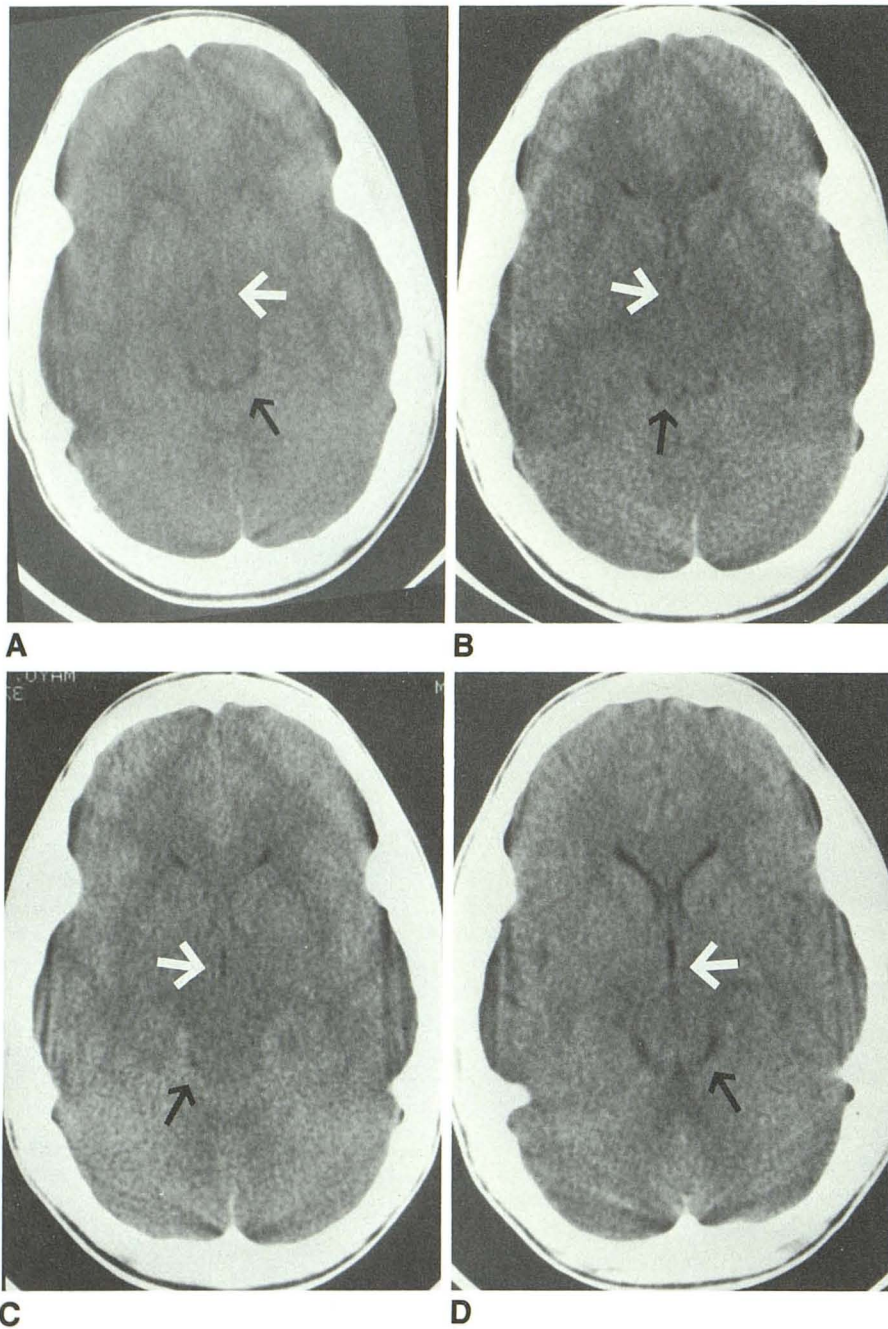


Fig. 5.—A-D, Case 3: changes in third ventricle and cisterns. Scans at admission (A), at 6-8 hr (B), and at 26 hr (C) show a reduced third ventricle (white arrow) in comparison with scan at 6 days (D). Quadrigeminal cistern (black arrow) is reduced on both admission scan (A) and on 6-8-hr scan (B), and completely obliterated on 26-hr scan (C) in comparison with 6-day scan (D).

brain barrier [13] and/or a defective adaptive mechanism of the brain in generating idiogenic osmoles and/or a defective Na-proton pump. The Na-proton pump may have particular relevance in view of the fact that it is activated by vasopressin and at least one group of counterregulatory hormones (catecholamines), as well as by insulin [14]. Our data suggest that the duration of the metabolic derangement involved in the pathophysiology of the pretreatment swelling need not be prolonged. It also indicates a relationship with the degree of abnormality but suggests that in some patients the abnormality need not be severe.

Although our data appear to indicate that treatment accentuates the subclinical swelling in some patients, and occasionally precipitates clinical brain edema, the presence of brain edema before treatment raises the alternative possibility that the accentuation of edema during treatment may be a progression of the underlying pathophysiology.

ACKNOWLEDGMENTS

The authors gratefully acknowledge the cooperation and expertise of James Cash in performing the CT scans, the expert skills of the

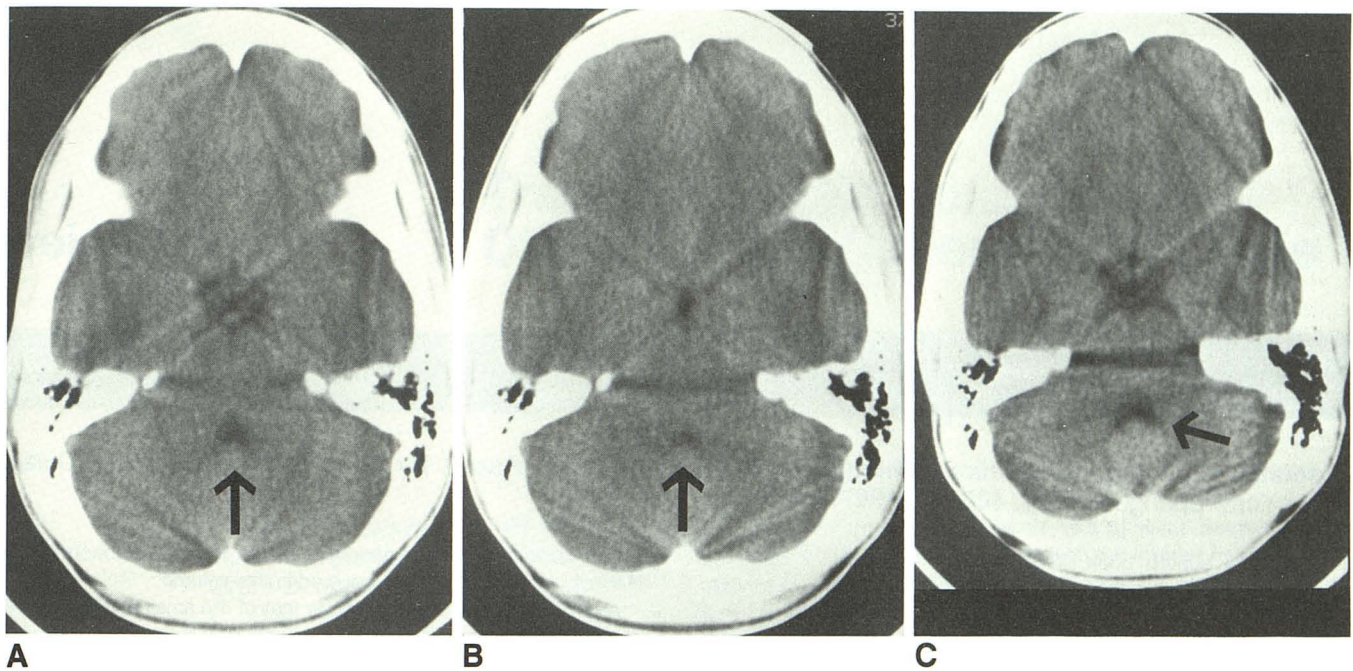


Fig. 6.—A–C, Case 3: fourth ventricle (arrow) is decreased on admission scan (A) and further decreased on 26-hr scan (B) in comparison with 6-day scan (C). Also note reduction of subarachnoid space in suprasellar region on 26-hr scan (B).

nursing staffs of the Pediatric Intensive and Intermediate Care Units, and the quality care of the Pediatric Residents at the Medical College of Georgia.

REFERENCES

1. Duck SC, Weldon VV, Pagliara AS, Haymond MW. Cerebral edema complicating therapy for diabetic ketoacidosis. *Diabetes* 1976;25:111–115
2. Rosenbloom AL, Riley WJ, Weber FT, Malone JI, Donnelly WH. Cerebral edema complicating diabetic ketoacidosis in childhood. *J Pediatr* 1980;96:357–361
3. Krane EJ, Rockoff MA, Wallman JK, Wolsdorf JI. Subclinical brain swelling in children during treatment of diabetic ketoacidosis. *N Engl J Med* 1985;312:1147–1151
4. Clements RS, Blumenthal SA, Morrison AD, Winegard AI. Increased cerebrospinal fluid pressure during treatment of diabetic ketosis. *Lancet* 1971;2:671–675
5. Arief AI, Kleeman CR. Studies on mechanisms of cerebral edema in diabetic comas. *J Clin Invest* 1973;52:571–583
6. Tornheim PA. Regional localization of cerebral edema following fluid and insulin therapy in streptozotocin-diabetic rats. *Diabetes* 1981;30:762–766
7. Bureau MA, Begin R, Berthiaume Y, Shapcott D, Khoury K, Gagnon N. Cerebral hypoxia from bicarbonate infusion in diabetic acidosis. *J Pediatr* 1980;96:968–973
8. Fein IA, Rackow EC, Sprung CL, Grodman R. Relation of colloid osmotic pressure to arterial hypoxemia and cerebral edema during crystalloid volume loading of patients with diabetic ketoacidosis. *Ann Intern Med* 1982;96:570–574
9. Kanter RK, Oliphant M, Zimmerman JJ, Stuart MJ. Arterial thrombosis causing cerebral edema in association with diabetic ketoacidosis. *Crit Care Med* 1987;15:175–176
10. Japan & Pittsburg Childhood Diabetes Research Groups. Coma at the onset of young insulin-dependent diabetics in Japan. *Diabetes* 1985;34:1241–1246
11. Toutant SM, Klauber MR, Marshall LF, et al. Absent or compressed basal cisterns on first CT scan: ominous predictors of outcome in severe head injury. *J Neurosurg* 1984;61:691–694
12. Feig PU. Hyponatremia and hypertonic syndromes. *Med Clin North Am* 1981;65:271–291
13. Winegrad AI, Kern EFO, Simmons DA. Cerebral edema in diabetic ketoacidosis. *N Engl J Med* 1985;312:1184–1185
14. Grinstein S, Rothstein A. Mechanism of regulation of the Na⁺/H⁺ exchanger. *J Membr Biol* 1986;90:1–12