

CT and MR Findings in a Patient with Alien Hand Sign

Matthew J. Kuhn,¹ Prashanth C. Shekar,¹ James Schuster,² Richard A. Buckler,³ and Stewart M. Couch¹

Alien hand sign is characterized by the presence of involuntary but seemingly purposeful, unilateral hand movements. It is believed to be caused by lesions in the supplementary motor area of the contralateral medial frontal lobe cortex. We present a patient with alien hand sign in whom results of CT and MR imaging of the brain showed infarction in the medial frontal lobes and corpus callosum.

Case Report

A 75-year-old right-handed man was hospitalized with a closed head injury he received from being struck by an automobile. He was lethargic and mute, and would not follow simple verbal or written commands.

A tonic grasp response to palmar stimulation was noted on the right, which was not present on the left. Other abnormal motor activity involved his right hand, which would spontaneously perform stereotyped movements such as brushing his hair repeatedly, rubbing his abdomen and chest, and grasping his left arm. The left upper extrem-

ity did not manifest any abnormal motor activity; indeed, it seemed to try to prevent the right hand from performing destructive movements, such as seizing and pulling on his feeding tube.

A CT scan obtained on admission showed no hemorrhage or other specific abnormality. Reexamination 1 week later (Fig. 1) showed decreased density in the corpus callosum and medial frontal lobes consistent with acute infarction. MR at this time (Fig. 2) revealed dark T1 and bright T2 signal abnormality in the corpus callosum and medial frontal lobes, also consistent with infarction.

Discussion

Lesions of the brain in areas supplied by the anterior cerebral artery (the anterior and medial frontal lobes and the rostral two thirds of the corpus callosum) may result in weakness of the contralateral limbs and produce a spectrum of other abnormal motor phenomena. These include compulsive movements of a reflex nature, such as the grasp reflex elicited by palmar stimulation [1]. More complex, semipurpo-

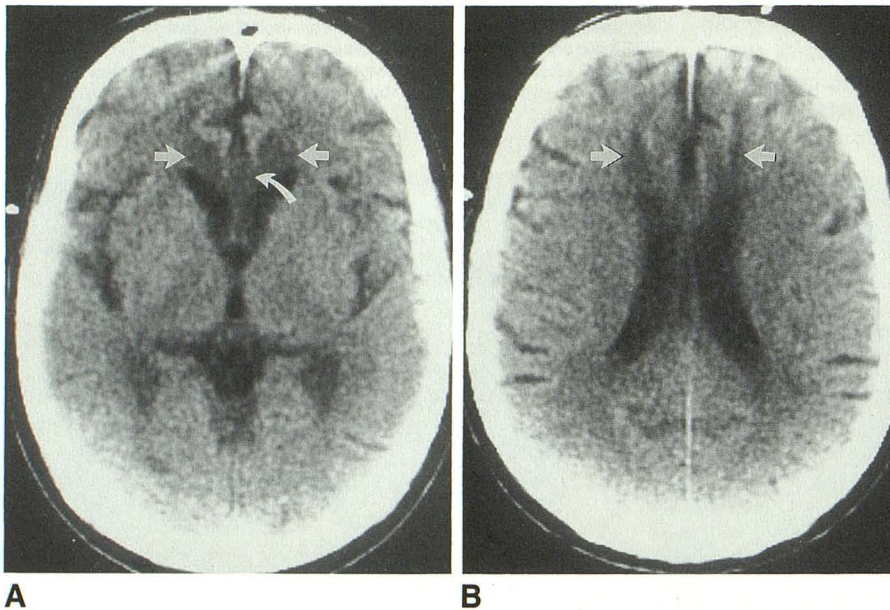


Fig. 1.—A and B, CT scans show new areas of decreased attenuation in medial frontal lobe cortex bilaterally (straight arrows) and in corpus callosum (curved arrow).

Received July 14, 1989; revision requested August 14, 1989; revision received September 7, 1989; accepted September 21, 1989.

¹ Department of Radiology, Southern Illinois University School of Medicine, 800 E. Carpenter St., Springfield, IL 62729. Address reprint requests to M. J. Kuhn.

² Department of Radiology, University of Massachusetts School of Medicine, Worcester, MA 01655.

³ Penn Neurologic Associates, Sellersville, PA 18960.

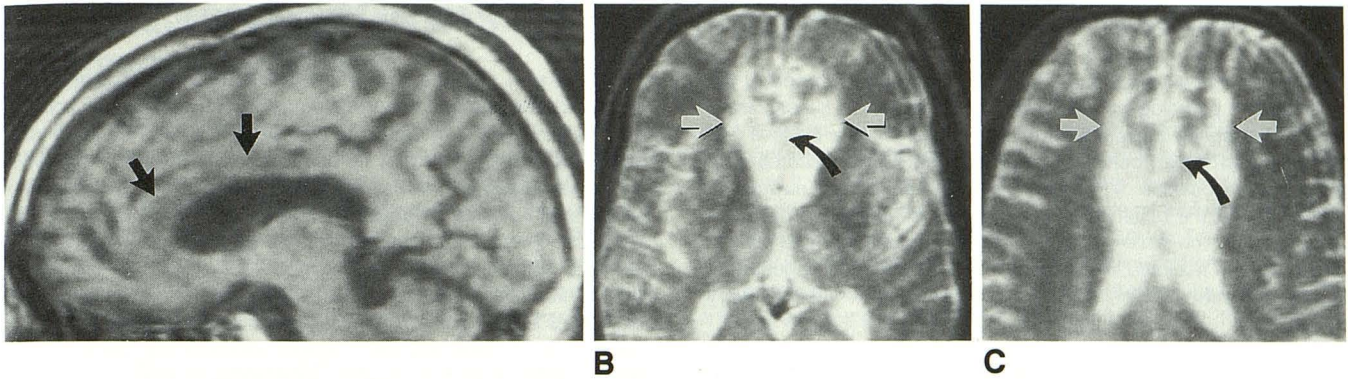


Fig. 2.—Midline sagittal T1-weighted MR image, SE 500/30, shows reduced signal in genu and body of corpus callosum (arrows). B and C, Proton density, SE 2000/60 (B), and T2-weighted, SE 2000/120 (C), MR images show associated bright signal in medial frontal lobe cortex bilaterally (straight arrows) and in corpus callosum (curved arrows).

sive, and spontaneous movements have been described as the alien hand sign [1].

The concept of the alien hand was originally introduced to label the uncooperative behavior of the nondominant hand in three patients with tumors of the corpus callosum [2]. Similar findings have also been described in patients with cerebral infarction or hemorrhage [3] in the anterior cerebral artery distribution. Most investigators believe that these abnormal forms of motor behavior are primarily the result of damage to the supplementary motor area (SMA) of the contralateral frontal lobe [4]. Injury to the corpus callosum is probably responsible for the agraphia and apraxia [5] of the involved hand that frequently accompanies the alien hand sign.

The SMA is located in the medial portions of the anterior frontal lobes near the corpus callosum. Since the SMA is bilateral, the alien hand sign may be associated with infarction in either the dominant or nondominant hemisphere. The SMA has many different afferent and efferent connections with the motor and premotor cortex [6]. One of the primary functions of the nondominant SMA may be to transform and modulate motor sequences generated in the dominant SMA [7].

In the present case, CT and MR showed infarction in both supplementary motor areas as well as in the corpus callosum. Despite this bilaterality, the patient maintained volitional control of his left (nondominant) hand. Clearly, there are other complex and incompletely understood neuronal pathways involved in hand control.

Owing to a variety of factors, including age and underlying or associated disease processes, three-dimensional imaging methods have limited ability to predict precisely the complex neurologic findings of many patients studied. Most patients with anterior cerebral artery distribution infarcts do not have the alien hand sign. Nonetheless, when a patient does exhibit the alien hand sign, CT and MR are useful in determining the cause of this bizarre movement disorder if a lesion is demonstrated in the contralateral supplementary motor area.

REFERENCES

1. McNabb AW, Carroll WM, Mastaglia FL. Alien hand and loss of bimanual coordination after dominant anterior cerebral artery territory infarction. *J Neurol Neurosurg Psychiatry* 1988;51:218-222
2. Brion S, Jedynak CP. Trouble du transfert interhémisphérique a propos de trois observations de tumeurs du corps calleux; le signe de la main étrangère. *Rev Neurol (Paris)* 1972;126:257-266
3. Starkstein SE, Berthier ML, Leiguarda R. Disconnection syndrome in a right-handed patient with right hemispheric speech dominance. *Eur Neurol* 1988;28:187-190
4. Goldberg G, Mayer N, Togliola J. Medial frontal cortex infarction and the alien hand sign. *Arch Neurol* 1981;38:683-686
5. Graff-Radford NR, Welsh K, Godersky J. Callosal apraxia. *Neurology* 1987;37:100-105
6. Freedman M, Alexander MP, Naeser M. Anatomic basis of transcortical motor aphasia. *Neurology* 1984;34:409-417
7. Chan JL, Ross ED. Left-handed mirror writing following right anterior cerebral artery infarction: evidence for nonmirror transformation of motor programs by right supplementary motor area. *Neurology* 1988;38:59-63