

## Cystic Intraventricular Schwannoma: A Case Report

Alan Howard Ost<sup>1</sup> and Richard Meyer<sup>2</sup>

Supratentorial schwannomas, especially those related to the cerebral ventricles, are rare lesions [1-7]. A unique case is presented with CT, MR, and clinicopathologic correlation.

### Case Report

A 44-year-old man in good health was found to have a right homonymous hemianopsia on a routine ophthalmologic examination. He had no other neurologic deficits, and the remainder of the physical examination was unremarkable.

Postcontrast axial CT of the brain (Fig. 1) revealed a 6-cm, irregularly contoured, low-density mass with a central, enhancing nodule ( $1.2 \times 1.6$  cm) situated in the left occipital region immediately posterolateral to the glomus of the left choroid plexus. Very little mass effect on the ventricular system and pineal gland was evident, and there was no ventricular enlargement. Associated calcifications were not identified.

Axial SE 900/20/1 (TR/TE/excitations), sagittal SE 300/32/2, and axial SE 2200/132/2 MR images were obtained prior to contrast infusion. After IV administration of gadopentetate dimeglumine, additional sagittal SE 600/20/1 (Fig. 2A) and axial SE 900/20/1 (Fig. 2B) images were acquired. The MR images further localized and defined the lesion. The central nodule enhanced homogeneously, and attachments to the choroid plexus were demonstrated. A cystic component was clearly demonstrated and had the signal characteristics of CSF. A mild amount of peritumoral edema was identified on the noninfusion T2-weighted axial images (not shown).

Diagnostic considerations included cystic astrocytoma, cystic meningioma, and hemangioblastoma. Primary lesions of the choroid plexus such as papilloma or carcinoma as well as metastatic disease were considered unlikely, as were cystic infectious lesions such as *Echinococcus granulosus* and *Cysticercus*.

Under intraoperative sonographic guidance, left temporoparietal craniotomy with tumor resection was performed. Clear fluid was aspirated from the cyst. The medial portion of the mural nodule was incorporated into the ventricular wall and several attachments to the choroid plexus were identified.

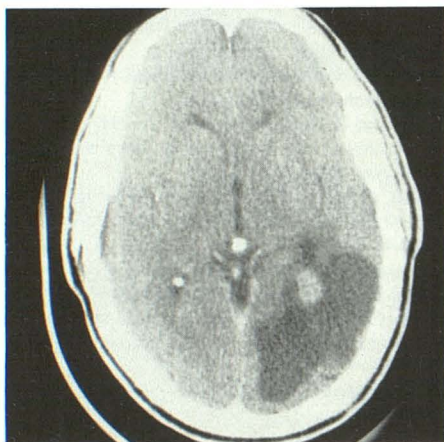

Fig. 1.—Postcontrast CT scan shows a large cystic mass with a central, enhancing nodule in left occipital region adjacent to glomus of choroid plexus.

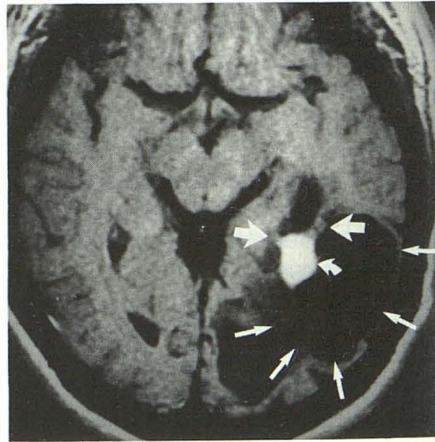
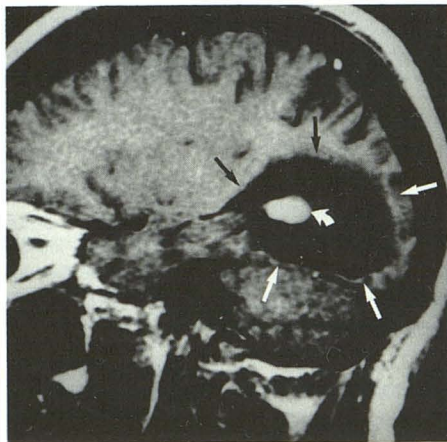


Fig. 2.—Intraventricular schwannoma.

A, Left parasagittal, postinfusion, spin-echo MR image (600/20) reveals an intensely enhancing nodule (curved arrow) surrounded by a large cyst (straight arrows) appearing to be located within or adjacent to left occipital horn.

B, Axial, postinfusion, spin-echo MR image (900/20) demonstrates the mass's attachments (wide straight arrows) to the ventricular wall. The linear high signal intensities are believed to represent incorporation of the neoplasm into the choroid plexus. The enhancing nodule (curved arrow) and surrounding cyst (thin straight arrows) are again identified.

Received February 22, 1990; revision requested April 14, 1990; revision received July 3, 1990; accepted July 6, 1990.

<sup>1</sup> Department of Radiology, Baylor University Medical Center, 3500 Gaston Ave., Dallas, TX 75246. Address reprint requests to A. H. Ost.

<sup>2</sup> Department of Pathology, Baylor University Medical Center, Dallas, TX 75246.



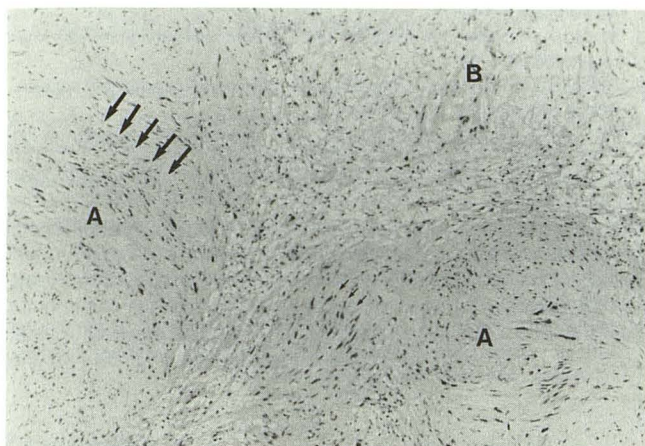


Fig. 3.—Schwannoma showing areas of Antoni A cellularity (A) with nuclear palisading (arrows) alternating with areas of Antoni B loose myxoid stroma (B). (magnification  $\times 86$ )

The tumor consisted of a circumscribed mass measuring  $2.0 \times 1.2 \times 0.9$  cm. Microscopically, the tumor demonstrated a variable pattern with areas of increased cellularity alternating with areas composed of loose, myxoid stroma (Fig. 3). The cellular portions of the tumor consisted of spindle cells arranged in a whirling pattern forming small nodules referred to as Antoni A tissue [8]. These cells showed elongated hyperchromatic nuclei with areas of nuclear palisading. Occasional cells had enlarged, atypical nuclei, but mitoses were not identified. These cellular areas alternated with adjacent Antoni B [9] patterns of loose myxoid stroma with sparse cellularity. Thick-walled vessels and central cystic areas were also seen.

Immunoperoxidase stains confirmed the histologic impression of schwannoma with positive reactions with S-100 protein, neuron-specific enolase, and glial fibrillary acid protein. Stains for cytokeratin and epithelial membrane antigen were negative.

## Discussion

Intracranial, extraaxial schwannomas are common tumors seen in the middle-aged adult and most often involve the eighth cranial nerve. Intraaxial schwannomas, in comparison, are unusual and tend to occur earlier in life. These tumors typically present with seizure disorders and are not likely to have associated neurofibromatosis [9].

Of seven previously reported cases [1–7], five were associated with the cerebral ventricles [3–7]. The origin of intracerebral and, in particular, intraventricular schwannomas remains unclear. A detailed discussion of the theoretical considerations is beyond the scope of this report; however, the most commonly accepted hypothesis proposes that these lesions arise from hyperplastic changes of the autonomic nerve fibers within the CNS, including those of the choroid plexus, which are known to contain Schwann cells [7]. The reports prepared by Ghatak et al. [4] and Pimentel et al. [7], as well as this case, are similar in that the tumors described all had anatomic attachments to the choroid plexus, thereby supporting this hypothesis.

Pathologically, schwannomas have a characteristic appearance. The gross specimen is firm, gray-white, circumscribed, and encapsulated. Histologically, these tumors demonstrate areas of high and low cellularity, referred to as Antoni A and Antoni B tissue [8], respectively. The cells are seen to whirl into small nodules with palisading of the nuclei. Confirmation of the diagnosis can be made with immunohistochemical stains and electron microscopy. The presence of the S-100 protein in the tumor specimen is most suggestive for a Schwann cell origin of the mass [8].

Owing to the infrequent occurrence of intracerebral schwannomas, the radiologic description is limited. Prior to the advent of cross-sectional imaging, diagnosis was aided by plain films, angiography, pneumoencephalography, and radionuclide brain scanning. Skull film findings, other than normal, included bony asymmetry and erosion, sutural diastasis, and focal calcification [1–6]. Cerebral angiography usually revealed vascular displacement by the underlying mass without evidence of tumor neovascularity [2–4, 6, 9]. Pneumoencephalography also demonstrated a mass effect [1, 3]. Nuclear brain scans were invariably positive in the regions of the lesions [2, 4–6]. Since the development of CT, only three cases [5, 7, 9] have been reported in which CT was utilized. Shalit et al. [5] and Pimentel et al. [7] described an enhancing, noncalcified mass involving the lateral ventricle. The third case, cited by Bruni et al. [9], revealed a hyperdense lesion within the left parasagittal frontal parenchyma in a patient with known neurofibromatosis.

MR imaging is very effective in the evaluation of CNS neoplasms and has been shown to have greater sensitivity than CT [10]. MR offers improved contrast and spatial resolution, as well as the ability to characterize different tissues and produce multiplanar images. With respect to this case, MR demonstrated the mass's cystic nature, intraventricular position, and its attachments to the choroid plexus. The differential diagnosis is misleading since these characteristics, in addition to the patient's age and presentation, suggest cystic astrocytoma or cystic meningioma, which are known to occur in this age group, often in the ventricles. Although the enhancing nodule is a characteristic finding for a hemangioblastoma, it usually occurs in the posterior fossa [10]. Choroid plexus papilloma or carcinoma was considered less likely, as the majority occur in the first decade and are also usually found in the posterior fossa within the fourth ventricle [10]. In addition, papillomas and carcinomas cause significant ventricular enlargement secondary to overproduction of CSF, and carcinomas tend to invade adjacent parenchyma. Metastasis was not likely, as the patient had no known malignancy. A parasitic lesion, such as *Echinococcus granulosus* or *Cysticercus (Taenia solium)*, can produce large cysts without much mass effect and may also produce nodular enhancement [10, 11]; it was included in the differential diagnosis as a remote possibility, since the patient had no known exposure to such organisms.

In summary, a unique case has been presented to raise the awareness of an unusual diagnostic consideration and to demonstrate the value of MR imaging. MR provides the ability to characterize tissue and distinguish a cyst from low-density



tissue. In addition, the multiplanar capacity of MR adds to the effectiveness of this imaging technique in terms of lesion localization.

#### REFERENCES

1. Gibson AAM, Hendrick EB, Conen PE. Intracerebral schwannoma: report of a case. *J Neurosurg* **1966**;24:552-557
2. New PFJ. Intracerebral schwannoma: case report. *J Neurosurg* **1972**;36:795-797
3. Van Rensburg MJ, Proctor NSF, Danziger J, Orelowitz MS. Temporal lobe epilepsy due to an intracerebral schwannoma: case report. *J Neurol Neurosurg Psychiatry* **1975**;38:703-709
4. Ghatak NR, Norwood CW, Davis CH. Intracerebral schwannoma. *Surg Neurol* **1975**;3:45-57
5. Shalit MN, Toledo E, Sandbank U. Intracerebral schwannoma. *Acta Neurochir* **1982**;64:253-258
6. Gokay H, Izgi N, Barlas O, Erseven G. Supratentorial intracerebral schwannomas. *Surg Neurol* **1984**;22:69-72
7. Pimentel J, Tavora L, Cristina ML, Lobo Antunes JAF. Intraventricular schwannoma. *Childs Nerv Syst* **1988**;4:373-375
8. Rosai J. *Ackerman's Surgical Pathology*, 7th ed. St. Louis: Mosby **1989**: 1565-1567
9. Bruni P, Esposito S, Greco R, Oddi G. Solitary intracerebral schwannoma in von Recklinghausen's disease. *Surg Neurol* **1984**;22:360-364
10. Stark DD, Bradley WG. *Magnetic resonance imaging*. St. Louis: Mosby, **1988**:322, 375-450
11. Enzmann DR. *Imaging of infections and inflammations of the central nervous system: computed tomography, ultrasound, & nuclear magnetic resonance*. New York: Raven Press, **1984**:123