

Maple Syrup Urine Disease: Findings on CT and MR Scans of the Brain in 10 Infants

Jan Brismar¹
Aida Aqeel²
Gudrun Brismar³
Robert Coates¹
Generoso Gascon²
Pinar Ozand²

Ten infants with classical maple syrup urine disease (MSUD) and two with variant MSUD had a total of 26 CT scans and 13 MR examinations of the brain during different stages of their disease. We found that inter- and inpatient analyses of CT and MR findings at times ranging from 3 days to 7 months were typical enough to suggest the MSUD diagnosis. Imaging studies showed the natural course of the disease and, in a few cases, illustrated the effects of therapy. CT scans typically are negative during the first few days of life, then a marked, generalized, diffuse edema appears. In addition, a localized, more severe edema (the MSUD edema) is seen, which involves the deep cerebellar white matter, the dorsal part of the brainstem, the cerebral peduncles, and the dorsal limb of the internal capsule. Both the generalized and the MSUD edema subside during the second month of life, then may disappear totally or leave a well-defined, low-density zone around the lateral ventricles and small, low-attenuation lesions within the brainstem, respectively. With the disappearance of the edema, some loss of brain substance becomes obvious.

ANJR 11: 1219–1228, November/December 1990

In maple syrup urine disease (MSUD), an enzymatic defect causes a block in one of the first steps of the common metabolic pathway for the catabolism of the branched-chain amino acids (BCAA): leucine, isoleucine, and valine. This leads to an accumulation of the corresponding keto acids and results in the urinary excretion of a metabolite with a characteristic odor, which gives the disease its name.

MSUD was first described in 1954 by Menkes et al. [1], who described a family that had lost four of six infants during their first week of life, each of whom displayed symptoms of vomiting, increased muscular tone, and urine that smelled like maple syrup. It is now known that the disease is inherited as an autosomal recessive trait, and from large screening series its frequency has been estimated to be about 1:224,000 [2]. About 75% of those affected suffer from the severe *classical* form; the remainder from milder *intermediate* or *intermittent* variants [2].

An infant suffering from classical MSUD usually appears normal during the first 4–7 days after birth but then starts to feed poorly, vomits, and fails to thrive. Truncal hypotonia, convulsions, and stupor progress to coma. Without treatment the infant often dies during the first few weeks of life—those surviving the first weeks develop severe brain damage [3]. The urine after the first few days manifests a characteristic odor similar to maple syrup.

The goal of the treatment in MSUD is to control the plasma BCAA concentration—initially, dialysis may be used; low BCAA diet is the main tool. Additionally, to avoid the accumulation of BCAA breakdown products, the metabolism should be kept anabolic (i.e., the child should gain weight). Even in newborn screening series, where diagnosis is established early, several children die before therapy is started, many families have problems with management of the diet, and in most series few infants will end up as “normal” [2, 4]; many will succumb to infections. However, if the therapy is instituted within 24 hr after the onset of symptoms, the

Received November 8, 1989; revision requested February 27, 1990; revision received May 8, 1990; accepted June 6, 1990.

This work was supported in part by a private grant (#85-0030) donated by Sheikh Rafiq Al-Hariri.

¹ Department of Radiology, King Faisal Specialist Hospital and Research Center, P. O. Box 3354, Riyadh 11211, Saudi Arabia. Address reprint requests to J. Brismar.

² Department of Pediatrics, King Faisal Specialist Hospital and Research Center, Riyadh 11211, Saudi Arabia.

³ Department of Surgery (Section of Ophthalmology), King Faisal Specialist Hospital and Research Center, Riyadh 11211, Saudi Arabia.

0195-6108/90/1106–1219

© American Society of Neuroradiology

prognosis appears to be favorable [4]. Previous cranial CT and MR findings in MSUD have been presented only in scattered case reports [5–11].

Materials and Methods

During the last 3 years we have encountered 25 patients with MSUD; 12 of those had brain CT examinations and they are the

subjects of this study. Six patients had multiple CT examinations, five had one or several brain MR studies as well; in total, 26 CT scans and 13 MR examinations were performed.

All 12 patients had high blood levels of BCAA, and, in all, fibroblasts from skin biopsy showed deficient capacity to oxidate ^{14}C -labeled BCAA. The degree to which the blood levels of BCAA responded to a low BCAA diet and the amount of remaining oxidative capacity of the fibroblasts were the criteria used to differentiate between classical

TABLE 1: Family History and Clinical Findings in 12 Patients with Maple Syrup Urine Disease (MSUD)

Case No.	Age at Diagnosis	Sex	Family History	Parents Consanguineous	Clinical History Before Diagnosis and Therapy	Leucine Level at Diagnosis (mol/l) ^a
1	17 days	M	Two brothers with MSUD	1st cousins	Lethargy, poor feeding, vomiting	2.90
2	2 mo	M	None	1st cousins	Seizures since 1 week of age, poor feeding, lethargy, several bouts of sepsis	3.17
3	7 weeks	M	None	Not related	At 1 week lethargy, coma, seizures, sepsis; at 7 weeks severe myoclonus, opisthotonus	2.73
4	1 mo	M	Brother with MSUD	1st cousins	Coma and convulsions at 2 weeks; developed spastic quadriplegia, opisthotonus, blindness; weighed 2.2 kg at 2 months	2.80
5	3 weeks	M	None	Not related	Lethargic at 3rd day, possible sepsis; diagnosis at 3 weeks; no proper diet until 8 weeks, then opisthotonus, blindness spastic quadriplegia	1.61 (at 8 weeks)
6	5½ mo	F	Brother (case 8) and two other siblings with MSUD	Double 1st cousins	At 1 week lethargy, poor feeding; at 1 month hypsarrhythmia, sepsis; at 2 months severe spastic quadriplegia, blindness	3.80
7	6 weeks	M	Two sisters died of MSUD	1st cousins	At 4 days poor feeding, irritability, suspected sepsis; 1–6 weeks worsened, blindness, spastic quadriplegia, bouts of sepsis	4.06
8	3 days	M	Sister (case 6) and two other siblings with MSUD	Double 1st cousins	Positive on screening, no symptoms	>1.0 (at screening), 1.28 (at 5 days)
9	6 days	M	Three siblings with MSUD	1st cousins	Positive on screening, diagnosis doubted until 6th day, too healthy, got normal milk; at 7 days severe convulsions, myoclonia	>1.0 (at screening), 1.15 (at 3 days), 2.75 (at 4 days)
10	27 days	M	Sister with pyruvate carboxylase deficiency	Not related	At 5 days coma, severe convulsions, respiratory arrest; at referral (27 days) severely neurologically damaged, opisthotonus	4.46 (at 27 days), 5.98 (at 28 days)
11 ^b	6 mo	F	Four siblings with MSUD	1st cousins	At 1 week aspiration pneumonia; 2–8 weeks poor feeding, lethargy; 8 weeks to 6 months hypsarrhythmia, hypotonia, blindness myoclonia	3.30
12 ^b	35 days	M	Two siblings with MSUD	1st cousins	At 9 days vomiting, lethargy; blind when referred for therapy at 34 days, otherwise alert, normal neurology	>3.0 (at 9 days), 0.56 (at 35 days)

^a Normal value: 0.01–0.16 mol/l.

^b Variant MSUD.

MSUD (total deficiency, 10 patients) and variant forms (partial deficiency, two patients). A summary of the clinical findings and family history is presented in Table 1.

CT of the brain was performed with 8- or 10-mm-thick contiguous slices (GE 9800, Picker 1200SX or Siemens Somatom); five patients

had contrast-enhanced CT studies. The contrast medium used was Ultravist, in concentrations of 300 mg/ml, 2 ml/kg body weight. The MR studies were performed on a Picker Vista 1.5-T unit. The examination always included axial dual-echo T2-weighted (1700–2100/30–40, 80–100) 7-mm-thick contiguous slices; sometimes a T1-weighted

TABLE 2: CT and MR Findings in 12 Patients with Maple Syrup Urine Disease (MSUD)

Case No.	Age at Imaging	Duration of Therapy	Leucine Level (mol/l) ^a	CT Findings				Loss of Brain Substance ^b	MR Findings		
				Edema/White Matter Disease	Severity Pattern ^b	MSUD Edema ^c	Severity Pattern ^b		Myelination	MSUD Edema ^c	Severity Pattern ^b
1	17 days	–	2.90	+++	Diffuse	+++	Diffuse	0			
2	34 days	–	NA	++	Intermediate	+++	Diffuse	0			
	2 mo	–	3.17	+	Intermediate	++	Well demarcated	+			
	6 mo	4 mo ^d	4.28	++	Well demarcated	+	Well demarcated	++			
3	7 weeks	–	2.73	++	Intermediate	++	Well demarcated	++			
	4 mo	2 mo	2.88	++	Well demarcated	+	Well demarcated	+++			
4	2½ mo	1½ mo	0.19	0		0		++			
5	8 weeks	5 weeks ^e	1.61	++	Well demarcated	++	Intermediate	++			
6	5½ mo	–	3.80	+	Well demarcated	+	Well demarcated	+	T2: Basal ganglia	0	
7	41 days	–	6.37–3.80	+++	Diffuse	+++	Diffuse	0			
8	3 days	–	>1.0	0		0		0			
	6 weeks	6 weeks	1.54	++	Intermediate	++	Diffuse	0			
	2½ mo	2½ mo	0.37–0.62						T2: None	0	
	4 mo	4 mo	0.96–1.06						T2: Basal ganglia	+	Well demarcated
	6 mo	6 mo ^d	1.06	++	Well demarcated	0		++	T1: Internal capsule	+	Well demarcated
9	14 mo	14 mo ^d	NA	+++	Well demarcated	0		+	+++ White matter disease	+	Well demarcated
	3 days	–	1.15	0		0		0			
	9 days	2 days	2.75–2.42	+++	Diffuse	++	Diffuse	0			
	22 days	15 days	2.42–1.95						T2: None	+++	Intermediate
	7 weeks	6 weeks	1.82–0.31	0		++	Well demarcated	+	T2: None	++	Well demarcated
	4½ mo	4½ mo	0.29	0		0		++	IR: Internal capsule	0	
15 mo	15 mo	NA	0		0		++	++ White matter disease	0		
10	27 days	–	4.46	+++	Diffuse	+++	Diffuse	0			
	33 days	5 days	2.72						T1: Basal ganglia	+++	Well demarcated
	2 mo	5 weeks	0.93	0		0		++	T2: Basal ganglia	+	Well demarcated
11 ^g	6 mo ^f	5 mo	1.62–0.22	++	Intermediate	++	Diffuse	+++	T1: Basal ganglia	+	Well demarcated
	8 mo	17 days	0.05	0		0		++			
	9 mo	1½ mo	0.05	0		0		+			
12 ^g	27 mo	26 mo	NA	0		0		+++			
	35 days	2 weeks	0.56	0		0		0	T1: Internal capsule	0	

^a Normal value: 0.01–0.16 mol/l.

^b Severity of edema or loss of brain substance graded as 0 (absent), + (mild), ++ (moderate), or +++ (severe); severity pattern graded as diffuse, intermediate, or well demarcated.

^c MSUD edema is a localized edema involving the cerebellar white matter, brainstem, and posterior limb of the internal capsule.

^d Very poor maternal compliance to diet.

^e No real diet, only low-protein food.

^f Infant in very poor condition: malnutrition, several bouts of sepsis, many times status epilepticus.

^g Variant MSUD.

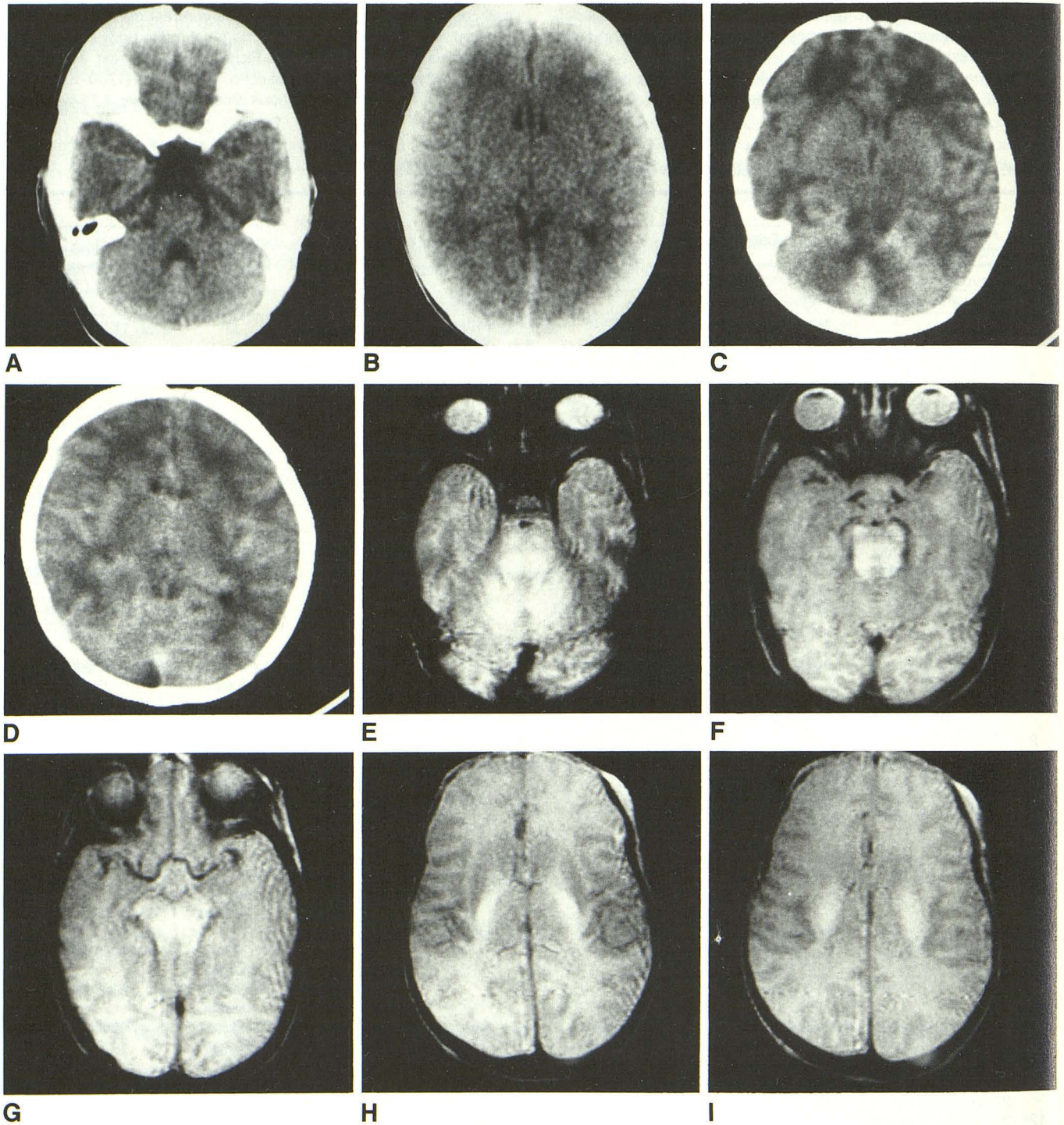


Fig. 1.—Case 9: Infant boy with hereditary maple syrup urine disease (MSUD). *A* and *B*, CT scans at age 3 days, before any symptoms had developed, are normal for age.

C and *D*, Repeat CT scans 6 days later, when the infant had developed severe convulsions and myoclonus, show severe generalized edema and severe MSUD edema.

E-I, T2-weighted axial MR images (2000/90) at age 22 days clearly show detailed distribution of MSUD edema.

(Fig. 1 is continued on the opposite page.)

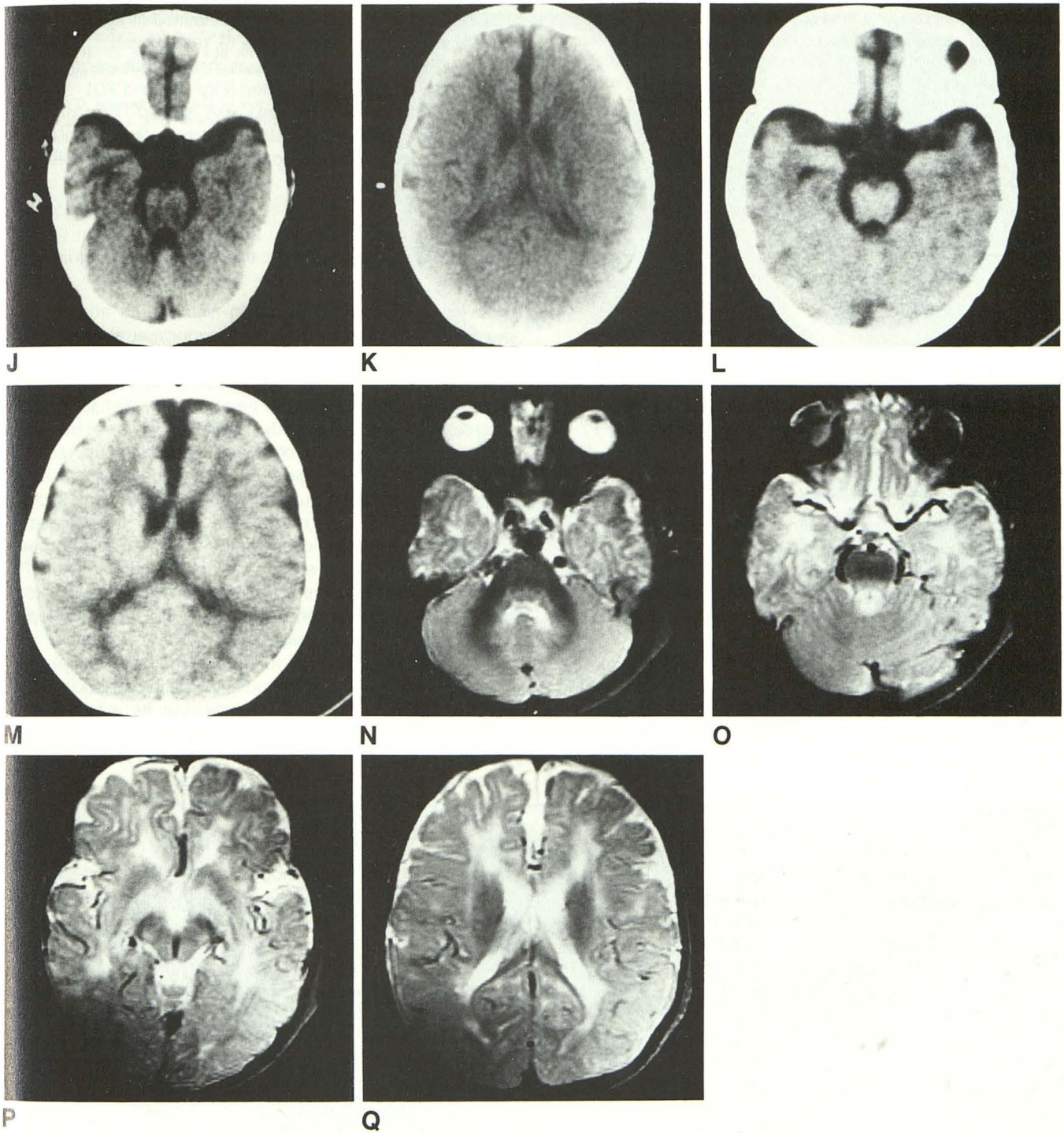


Fig. 1—(continued).

J and K, At age 7 weeks, after 6 weeks of therapy, CT scans show decrease of MSUD edema and disappearance of generalized edema; some loss of brain tissue is already obvious.

L and M, At 4½ months, CT scans show quite pronounced atrophic changes in spite of early diagnosis and therapy.

N-Q, T2-weighted MR images (2000/90) at age 14 months show myelination within deep white matter of posterior fossa, brainstem, and internal capsule up to the centrum semiovale; otherwise there is delayed myelination. Note higher intensity within globus pallidus. Quite pronounced atrophic changes are present.

(600–700/20–30) sequence in axial or sagittal projection, or a coronal T2-weighted sequence was also obtained. The CT and MR examinations were evaluated for (1) Generalized edema/white matter disease, which was subjectively graded as either absent (0), mild (+), moderate (++), or severe (+++). Its pattern was classified as either diffuse, intermediate, or well demarcated. This grading is further clarified through examples in the figures. (2) Localized, more severe edema (described below in Results); its severity and pattern were graded the same way as generalized edema. (3) Signs of loss of brain substance ("atrophy"), also graded as either absent (0), mild (+), moderate (++), or severe (+++).

Results

The results of the CT and MR examinations are summarized in Table 2. Also given are the ages of patients at the time of the various imaging examinations and the time relation between these examinations and the institution of therapy.

CT and MR Findings in Untreated MSUD

In total, nine CT examinations in eight patients were performed before any therapy was given. As the patients' age at these examinations ranged from 3 days to 7 months, inter- and inpatient analyses of the findings suggest the natural course of the disease.

First few days of life. Two patients were examined on the third day of life. Both were asymptomatic and appeared normal; they were examined because each had siblings who had died from MSUD in early infancy. The CT findings in both these infants were within normal limits for a newborn (Figs. 1A and 1B).

Second to sixth week. In one of these patients (case 9), a second CT examination at 9 days of age, after 2 days of diet (before the diet could have produced any effect), showed severe diffuse generalized edema (Figs. 1C and 1D); by then the child had developed severe convulsions and myoclonia. Similar changes were present in all four of the patients examined between 2 and 6 weeks of age (Figs. 2A and 2B, 3, and 4A and 4B). The edema changes, in all the infants, were far more pronounced than the neonatal edema sometimes seen in normal newborns.

In addition, a characteristic, localized, intense edema (referred to as MSUD edema) involving the cerebellar deep white matter, the posterior part of the brainstem, the cerebral peduncles, the posterior limb of the internal capsule, and the posterior aspect of the centrum semiovale was present in all our untreated patients with classical MSUD examined during this time interval. At 9 days of age, MSUD edema was seen only as two diffusely outlined low-density lesions dorsally in the brainstem (Figs. 1C and 1D). At 17 days of age, the MSUD edema was fully developed and quite diffusely outlined.

Seventh week to sixth month. In one patient (case 2) a second CT examination of the brain at 2 months of age (still no therapy) showed a decrease in the generalized edema with remaining low attenuation changes in a more limited periventricular distribution (Figs. 2C and 2D). This was also

the finding in two patients initially examined at ages 7 weeks (case 3) and at 5½ months (case 6), respectively.

The MSUD edema after the second month became less extensive and better demarcated (Figs. 2C and 2D).

After the generalized edema had settled, loss of brain substance with widening of the sulci over the frontal lobes and of the interhemispheric and sylvian fissures became obvious (Figs. 2C and 2D).

CT and MR Findings in Classical MSUD During Treatment

Seventeen CT examinations in nine infants and 12 MR examinations in four infants were performed after different durations of therapy.

Therapy initiated in the fourth week or later. Most of the patients were already severely neurologically damaged when referred to us. In one (case 10), the diagnosis was established at 27 days of age and the child was immediately dialyzed for 4 days and put on a rigid diet. In two patients a dietary regimen was not started until after the age of 2 months (case 2) and 7 weeks (case 3), respectively. A fourth infant (case 5) arrived to us at 8 weeks of age after 1 month of a low-protein diet. All these infants were in very poor condition, with CT-verified loss of brain substance at the time diet was initiated, and none improved with therapy. Follow-up CT, performed in three cases, showed increased loss of brain substance.

One infant (case 4) came to us at 2½ months of age after 1 month of therapy at another hospital. His blood leucine level (initially very high) was then normal, but he was severely malnourished and blind, with opisthotonus and spastic quadriplegia. CT in spite of this was normal except for widening of the sylvian and interhemispheric fissures.

Therapy initiated during the first week. In two of our patients, therapy was started early—in case 8 at 3 days and in case 9 at 7 days of age. In case 8, a control CT study after 6 weeks of diet showed a moderate generalized edema and also quite pronounced MSUD edema. At repeat MR examinations, during the first half year of treatment, the focal edema almost completely disappeared leaving only two small high T2-intensity spots dorsally within the brainstem. CT after 6 months showed white matter disease and some atrophy, but no MSUD edema. MR verified the white matter disease, but on T1 registration showed some myelin within the internal capsule. CT and MR after 14 months showed severe white matter disease.

In case 9, MR imaging 15 days after the start of diet showed pronounced MSUD edema (Figs. 1E–1I). CT studies 4 weeks later showed disappearance of the generalized edema, and the MSUD edema was less pronounced and better demarcated (Figs. 1J and 1K). Slight loss of brain substance could also be seen at this stage. After another 3 months, CT showed disappearance of the MSUD edema, while the loss of brain tissue was more prominent (Figs. 1L and 1M). At 15 months of age myelination had improved somewhat but was markedly delayed.

CT and MR findings in variant MSUD. One of our two infants with variant MSUD (case 12) had normal CT and MR exami-

Fig. 2.—Case 2: Infant boy with seizures, lethargy, poor feeding, and bouts of sepsis.

A and B, CT scans at age 34 days show moderate generalized edema and severe MSUD edema.

C and D, Repeat CT scans at age 2 months, before diagnosis and therapy, show edema changes to be better defined; they also demonstrate loss of brain tissue.

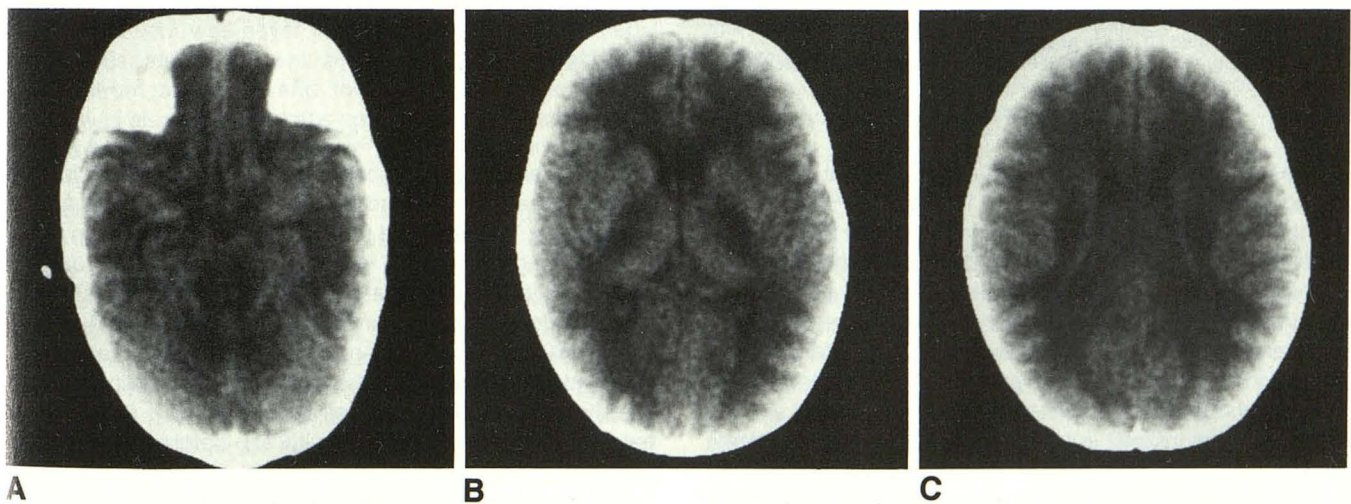
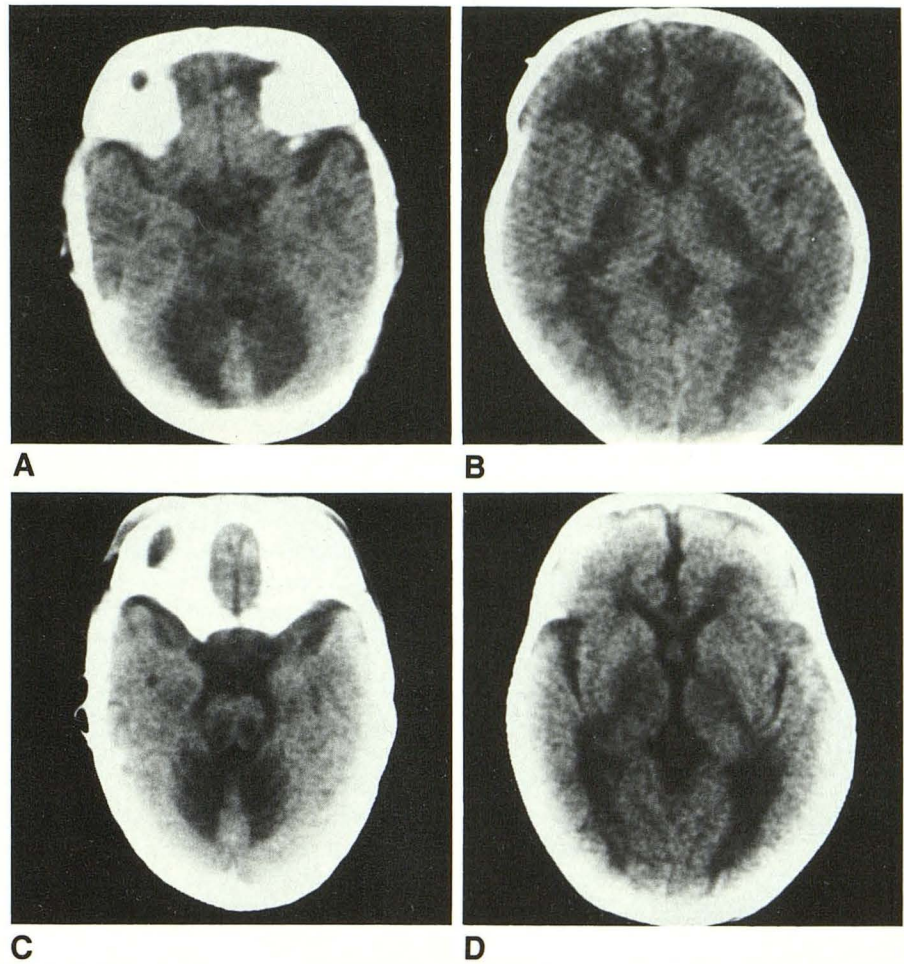


Fig. 3.—Case 7: 6-week-old boy who is blind and quadriplegic.

A–C, CT scans, selected slices, show severe generalized edema and severe MSUD edema.

nations at 5 weeks of age after 2 weeks of diet. In the other (case 11), who was placed on the diet at 7½ months of age, CT examinations over 8–27 months of age only showed progressive loss of brain tissue.

Discussion

Information on the CT and MR findings in MSUD is very limited. We have only been able to retrieve seven reports [5–

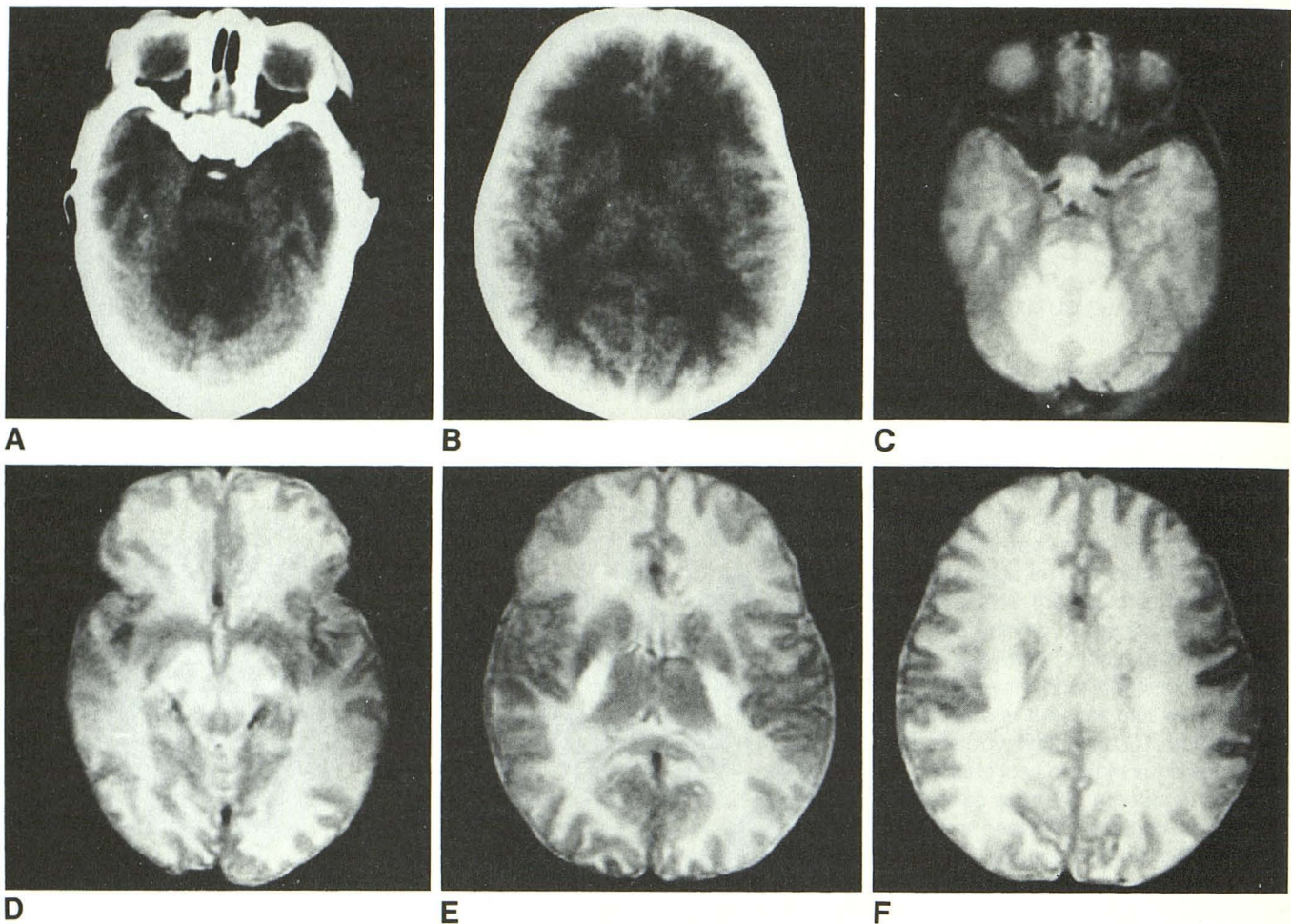


Fig. 4.—Case 10: 27-day-old boy, already severely damaged at diagnosis.
 A and B, Selected CT slices at age 27 days.
 C–F, T2-weighted MR images (2500/80) 6 days later show detailed distribution of severe MSUD edema.

11] describing a total of five infants with classical MSUD [5–7] and five with variant MSUD [8–11]. Moreover, none of the infants with classical MSUD were examined with MR imaging. Four were studied with CT between the seventh and 18th day of life, before the start of diet; the fifth patient was examined at 24 days of age after 6 days of diet. The initial CT examination in all showed lucency of the white matter of the brain. It was discussed whether this represented edema or delayed myelination [5]; the presence of widened sutures in two of the infants supported the diagnosis of edema [5, 6].

At autopsy of a 12-day-old infant with classical MSUD [12], major alterations were found in the white matter, which "was poorly cellular and showed a loose-masked, cystic appearance." Myelination was less than expected for age but there were no signs of myelin breakdown. Furthermore, chemical analysis showed no abnormality in lipid composition or structure. No gray matter changes were present, except in the dentate and inferior olivary nuclei, where many of the

neurons were large with pale cytoplasm. Two other infants with classical MSUD, who died at 11 and 14 days of life, respectively, only showed signs of delayed myelination [1].

Our finding of a normal initial CT examination at 3 days of age in two patients who later developed severe low-attenuation changes (in one documented only 6 days later) proves these changes to be caused by a relatively acute edema, which may correlate with the rapid clinical impairment that usually starts at 4–7 days of age. There are no previous reports on infants examined with CT before the onset of clinical symptoms.

The localized MSUD edema was, in our series, most pronounced from the third week through the second month. No reports on autopsy findings are available from this age group. In an autopsy report on two infants with classical MSUD (one untreated) who died at 4 and 5 months of age, respectively, nothing is mentioned about focal brain changes [13].

Localized edematous changes were mentioned in only one of the five published reports of patients with classical MSUD

who were examined with CT. Low-attenuation changes were described within the posterior limb of the internal capsule in one infant at 24 days of age, following 6 days of diet [5]. In another report [7], one illustration shows low-attenuation changes corresponding to the posterior limb of the internal capsule at 15 days of age.

Acute MSUD edema in our series was most intense in an area corresponding to the cerebral peduncles and the posterior part of the posterior limb of the internal capsule (Figs. 1C and 1D, 2A and 2B, 3, and 4). No similar localized findings have been reported from autopsy studies.

The autopsy of two 9-month-old infants with untreated classical MSUD [14] showed the most severe changes within the dentate nucleus. The myelination was generally delayed, especially in the corticospinal tracts. The medial longitudinal fasciculus, the brachium conjunctivum, and the lateral lemniscus were better myelinated (though less than normal for age) but had a spongy appearance. These latter areas correspond quite well to the late MSUD edema changes within the posterior fossa and dorsal brainstem.

Signs of brain tissue loss were present in all eight patients with classical MSUD who we examined after disappearance of the acute, diffuse, generalized edema.

In classical MSUD, the CT and MR findings during the edema phase appear to be typical enough to permit the MSUD diagnosis. In our case 9, the diagnosis of MSUD was suggested on the basis of the CT findings. Because these findings may be present as early as 9 days of age, when therapy may still be effective, the radiologist must be aware of the possibility of MSUD when he sees severe generalized edema on CT or MR in a neonate, especially if focal brainstem changes are present as well.

The autopsy findings in two infants, who died at 4 and 5 months of age, respectively, illustrate the effects of diet [13]. The first patient was never treated. His brain was markedly edematous, and myelin was almost completely absent from the centrum semiovale and the subcortical white matter. There was also marked status spongiosus. The second child was put on a diet at 10 days of age. At 5 months he died from a circulatory collapse. While the brain in this child also was edematous (agonal changes?) with some gliosis of the white matter, the myelination was normal for age and no status spongiosus was present.

In our series, only two patients were given therapy within the first week of life. However, in spite of this, both had marked initial problems: one (case 8) had several severe bouts of sepsis, the other (case 9) had convulsions and an episode with cardiac and respiratory irregularities. The mother of the patient in case 8 never complied with the dietary scheme, which may explain why he developed severe generalized white matter disease and loss of brain substance and also significant neurologic deficits. At 14 months he was blind and moderately mentally retarded, with muscular hypotonia.

Two of the patients in the published cases of classical MSUD had follow-up CT examinations after therapy [5]. In one patient, pronounced, generalized white matter low-density changes were still present at 35 days of age after 17 days of treatment. At 5½ months the white matter appeared

nearly normal, but signs of mild cerebral atrophy had appeared. In the other patient a follow-up CT at 48 days (30 days after the start of diet) showed normal white matter except for the frontal lobes and possible mild atrophy. These findings are similar to those in our patient who received the best treatment (case 9).

Because the edema changes appear to decrease with age in both treated and untreated patients, the effects of therapy on the imaging studies are difficult to evaluate. However, the results in our two patients who were treated within the first week suggest that the edema might decrease faster during strict dietary regimen.

In our two patients with variant MSUD, after only 2 weeks of diet CT was normal in one and showed loss of brain tissue but no white matter changes in the other.

Significant CT findings in association with variant MSUD have, however, been previously reported in five patients [8–11]. At 5–18 months of age, before therapy, all five showed a generalized edema and also a local edema involving the region of the thalamus and globus pallidus. The exact extension of the edema changes is impossible to evaluate from the published illustrations, but it may well have been the same as that of the MSUD edema in our *classical* MSUD patients; that is, probably not involving the thalamus but only passing through the cerebral peduncles. This at least appears to be the case in one of the patients described [11]. The low-density lesions were described as cerebellopontomedulloolivary and mesencephalic in two siblings [10] examined at 5 and 11 months of age, respectively. In the latter of these children, who was never treated, autopsy at 5 years of age showed a locally pronounced status spongiosus within these regions.

In three infants with variant MSUD, follow-up studies were performed after dietary regimen. In one, CT was normal at 11 months of age after 2 months of therapy [8]; in two, CT showed only slight loss of brain tissue at 8 months of age after 3 months of therapy [10] and at 24 months of age after 6 months of diet [9], respectively.

Conclusions

In patients with classical MSUD the CT and MR findings follow a characteristic pattern. During the first few days of life CT is normal. A marked diffuse brain edema then develops as the clinical condition deteriorates, and this edema remains for as long as 6 or 7 weeks in untreated infants. It then decreases and tends to transform into better-demarcated periventricular white matter disease. Dietary regimen seems to accelerate this process. A characteristic, more intense, local edema (the MSUD edema), involving the deep cerebellar white matter, the dorsal part of the brainstem, the cerebral peduncles, and the posterior limb of the internal capsule, was present in nine of 10 patients with classical MSUD. This local edema became fully developed during the third week of life. After the second month it usually subsided, leaving two small low-density (high MR T2-intensity) lesions dorsally in the brainstem. At this same time, some loss of brain substance

becomes obvious. The CT and MR findings during the edema phase are typical enough to suggest the MSUD diagnosis.

REFERENCES

1. Menkes JH, Hurst PL, Craig JM. New syndrome: progressive familial infantile dysfunction associated with an unusual urinary substance. *Pediatrics* **1954**; 14: 462-466
2. Naylor GW, Guthrie R. Newborn screening for maple syrup urine disease (branched chain ketoaciduria). *Pediatrics* **1978**; 61: 262-266
3. Tanaka K, Rosenberg LE. Disorders of branched chain amino acid and organic acid metabolism. In: Stanbury JB, Wyngaarden JB, Fredrickson DS, Goldstein JL, Brown MS, eds. *The metabolic basis of inherited disease*. New York: McGraw-Hill, **1983**: 440-473
4. Naughten ER, Jenkins J, Francis DEM, Leonard JV. Outcome of maple syrup urine disease. *Arch Dis Child* **1982**; 57: 918-921
5. Mantovani JF, Naidich TP, Prensky AL, Dodson WE, Williams JC. MSUD: presentation with pseudotumor cerebri and CT abnormalities. *J Pediatr* **1980**; 96: 279-281
6. Lungarotti MS, Signorini E, Garibaldi LR. Cerebral edema in maple syrup urine disease. *Am J Dis Child* **1982**; 136: 648
7. Romero FJ, Ibarra B, Rovira M, Natal A, Herrera M, Segarra A. Cerebral computed tomography in maple syrup urine disease. *J Comput Assist Tomogr* **1984**; 8: 410-411
8. Suzuki S, Naito H, Abe T, Hihei K. Cranial computed tomography in a patient with a variant form of maple syrup urine disease. *Neuropediatrics* **1983**; 14: 102-103
9. Verdu A, Lopez-Herce J, Pascual-Castroviejo I, Martinez-Bermejo A, Ugarte M, Garcia MJ. Maple syrup urine disease variant form: presentation with psychomotor retardation and CT scan abnormalities. *Acta Paediatr Scand* **1985**; 74: 815-818
10. Irnberger Th, Plöchl E, Rittinger O, et al. Die kraniale Computertomographie bei der Ahornsiruperkrankung. *ROFO* **1986**; 144:413-417
11. Uziel G, Savoiaro M, Nardocci N. CT and MRI in maple syrup urine disease. *Neurology* **1988**; 38: 486-488
12. Menkes JH, Philippart M, Fiol RE. Cerebral lipids in maple syrup disease. *J Pediatr* **1965**; 66: 584-594
13. Menkes JH, Solcher H. Maple syrup disease. Effects of dietary therapy on cerebral lipids. *Arch Neurol* **1967**; 16: 486-491
14. Silberman J, Dancis J, Figin I. Neuropathological observations in maple syrup urine disease. *Arch Neurol* **1961**; 5: 21-33