

# Surgical Transvenous Embolization of a Cortically Draining Carotid Cavernous Fistula via a Vein of the Sylvian Fissure

Naoya Kuwayama, Shunro Endo, Masahiro Kitabayashi, Michiharu Nishijima, and Akira Takaku

**Summary:** Percutaneous transvenous embolization is one of the most effective treatments of intracranial dural arteriovenous fistulas (AVFs) involving the dural sinuses. We present a unique case of surgical transvenous embolization in a 48-year-old man with a dural AVF of the cavernous sinus who presented with intracerebral hematoma. The dural AVF drained only into the vein of the sylvian fissure on angiography. Transvenous embolization via the vein of the sylvian fissure during craniotomy obliterated the AVF completely.

Dural arteriovenous fistulas (AVFs) account for about 12% of intracranial arteriovenous fistulas (1) and are considered acquired lesions (2–4). Most involve the transverse sigmoid and cavernous sinuses, and they are sometimes associated with sinus thrombosis. Dural AVFs occasionally behave aggressively, depending on their pattern of venous drainage. A high risk of bleeding is emphasized (5–9), especially for lesions draining into leptomeningeal veins due to occlusion of other draining routes. Dural AVFs of the cavernous sinus usually present with ocular symptoms (10); in patients with this condition, an aggressive neurologic course resulting from intracranial hemorrhage is rare (5).

Endovascular treatment is currently a standard therapy for dural AVFs involving the cavernous sinus that do not respond to conservative treatment (11–13). Occlusion of the venous side of the fistula using a transvenous approach is considered the principal form of treatment (14); however, the development of secondary sinus thrombosis sometimes obstructs percutaneous transvenous access routes. Transarterial embolization, direct surgical approach to the cavernous sinus, and/or radiosurgery are the usual alternatives for the treatment of such lesions. We describe a unique case of surgical transvenous embolization of a dural AVF of the cavernous sinus draining only into the vein of the sylvian fissure.

## Case Report

A 48-year-old man had a 2-year history of bilateral tinnitus but no history of trauma. He experienced sudden onset of

headache followed by left hemiparesis while playing golf and was admitted to an emergency hospital. A CT scan revealed an intraparenchymal hematoma in the right frontal lobe (Fig 1A), which was evacuated by emergency surgery. During the operation, the surgeon noticed numerous dilated fine vessels on the cortex. A dural AVF of the cavernous sinus was suspected at follow-up angiography, and the patient was referred to our hospital for further treatment 6 months after the operation.

Neurologic examination on admission revealed left hemiparesis without any ocular symptoms or signs. His tinnitus persisted but no vascular bruit was heard. A detailed interview disclosed no history of chemosis, conjunctival injection, proptosis, or diplopia. Angiography revealed a dural AVF involving the right cavernous sinus (Fig 1B–E), which was fed by bilateral internal and right external carotid arteries and drained only into the ipsilateral (right) vein of the sylvian fissure via the sphenoparietal sinus. The superior ophthalmic vein, inferior and superior petrosal sinuses, and pterygoid plexus were not opacified on angiograms. A percutaneous transvenous approach was attempted, but the catheter reached only the posterior compartment of the right cavernous sinus, which was not involved by the fistula (Fig 1F). The affected cavity of the cavernous sinus appeared to be isolated by a tight septum, resulting in lack of drainage routes other than the sphenoparietal sinus.

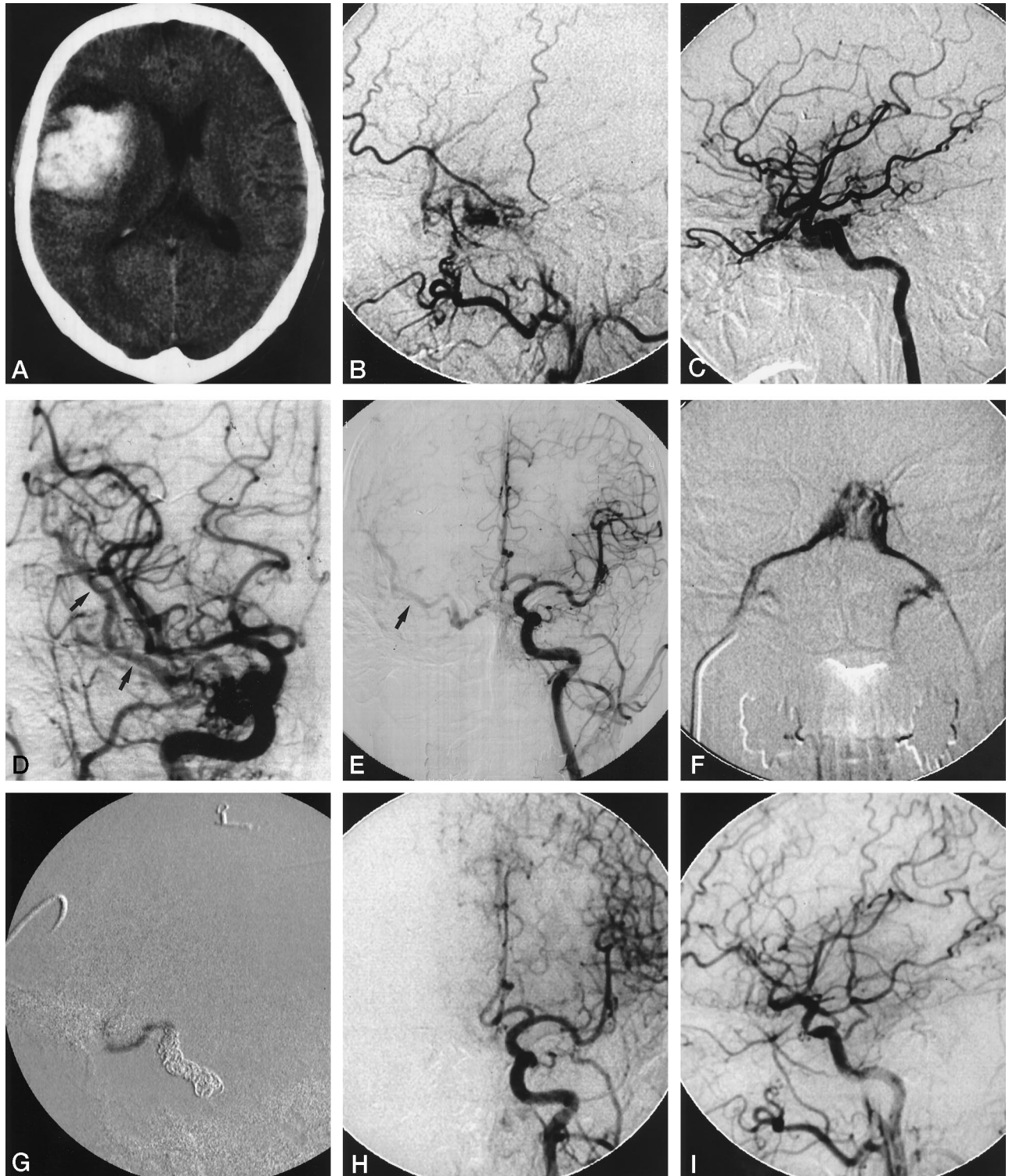
Finally, the distal part of the red arterialized vein of the sylvian fissure was exposed on the cortex during craniotomy. The wall of the vein was thickened and a microcatheter was easily introduced into the vein by direct puncture. The catheter was placed in the affected cavity of the cavernous sinus without any difficulty. The initial mean pressure of the sinus was 58% of the mean systemic arterial blood pressure, and blood gases were purely arterial. The sinus was packed with interlocking detachable coils (Target-CMI, Inc, Tokyo) under fluoroscopy (Fig 1G) using the road-mapping technique. This procedure resulted in complete obliteration of the fistula. The vein of the sylvian fissure became dark red, and hemostasis was easily achieved after removal of the catheter. The postoperative course was uneventful. The patient's tinnitus disappeared, and follow-up angiography 2 days after the operation showed complete cure (Fig 1H and I) with lack of opacification of the vein of the sylvian fissure. The patient was transferred to another hospital for rehabilitation.

## Discussion

The natural history and symptoms of intracranial dural AVFs vary significantly depending on the pattern of venous drainage (3, 5, 7, 8, 15–17). Most

Received May 27, 1997; accepted after revision September 30.

From the Department of Neurosurgery, Toyama Medical & Pharmaceutical University, 2630 Sugitani, Toyama 930–01, Japan. Address reprint requests to Naoya Kuwayama, MD.



**FIG 1.** 48-year-old man with 2-year history of bilateral tinnitus and sudden onset of headache and left hemiparesis.

**A,** CT scan shows a left frontal intraparenchymal hematoma.

**B–E,** Lateral views of right external (**B**) and internal (**C**) carotid injection and anteroposterior views of right common (**D**) and left internal (**E**) carotid injection. The dural AVF involves the right cavernous sinus and drains only into the ipsilateral sphenoparietal sinus and the vein of the sylvian fissure. Note the vein of the sylvian fissure (arrows; **D**, **E**) is opacified in retrograde fashion, emptying into the superior sagittal sinus through anastomotic channels.

**F,** Cavernous sinus opacification (anteroposterior view) by percutaneous transvenous approach reveals normal posterior compartments and bilateral inferior petrosal sinuses, which were not involved by the dural AVF.

**G,** Intraoperative digital subtraction angiogram of the cavernous sinus (lateral view). A microcatheter was placed in the cavernous sinus via the vein of the sylvian fissure during craniotomy, and the sinus was packed with several coils.

**H** and **I,** Postoperative left (**H**) and right (**I**) common carotid artery injections confirm complete obliteration of the dural AVF. The stenotic appearance of the cavernous portion of the right internal carotid artery (**I**) is due to a subtraction artifact.

aggressive neurologic courses in affected patients are thought to result from intracranial hemorrhage. Leptomeningeal venous drainage, variceal or aneurysmal venous dilatation, and galenic drainage have been shown to be significant factors predisposing to an aggressive neurologic course (5). A long-term follow-up study also revealed that lesions draining into leptomeningeal veins had an increased frequency of hemorrhage (7). Dural AVFs of the cavernous sinus usually present with ocular symptoms, such as exophthalmos, chemosis, conjunctival injection, proptosis, or diplopia. Most such lesions are therefore considered benign (ie, not life-threatening). Intracranial hemorrhage is a rare (10) but catastrophic complication of these lesions. Most cases of hemorrhagic complication reported in the literature were associated with high-flow traumatic carotid-cavernous fistulas that drained into cerebral veins (18–24). Six instances of aggressive clinical courses resulting from cavernous sinus dural AVFs were reported in a review of 377 dural AVFs (5); however, it was not made clear whether the aggressive clinical courses of these six patients included intracranial hemorrhage. A long-term follow-up study of 54 patients with dural AVFs included one patient with a cavernous sinus dural AVF in whom subarachnoid hemorrhage developed (7). In our patient, the high venous pressure (58% of mean systemic blood pressure) measured in the affected cavernous sinus was thought to have resulted from occlusion of other drainage routes and to have caused the intracerebral hemorrhage.

Treatment of dural AVFs of the cavernous sinus varies widely (10), but begins with observation as the first step, given the variety of clinical and angiographic manifestations. However, we believe that drainage into cerebral veins is an absolute indication for urgent treatment because of the high associated risk of bleeding (5). We sometimes are able to use a transvenous approach even in cases in which the inferior petrosal sinus, a major access route for transvenous embolization, is not opacified by angiography. An approach via the contralateral cavernous sinus is even successful in some cases. However, all these techniques were unsuccessful in the present case. Compartmentalization of the cavernous sinus (25) was strongly suspected as the reason for the failure of these approaches. Although a successful approach via the superior ophthalmic vein has been reported (26–28), it seemed unlikely to succeed in our case, since the superior ophthalmic vein was not opacified on angiograms. A direct surgical approach to the involved cavernous sinus has been described by several authors (6, 29–34); however, this technique appears to be rather invasive. A surgical transthemoidal-transphenoidal approach has also been reported for the treatment of endovascularly inaccessible carotid cavernous fistulas (35). In the present case, the fistula drained into the vein of the sylvian fissure alone, which was used as a transvenous access route, avoiding the invasive, direct surgical approach to the cavernous sinus.

Some potential risks, such as cortical venous per-

foration, should be considered in surgical transvenous catheterization. In the present case, the draining vein of the sylvian fissure was thickened and arterialized because of the long-standing disease, and we thought careful manipulation could avoid this risk. A clip on the proximal aspect of the vein of the sylvian fissure might also have treated the fistula (14); however, we thought that packing the affected sinus would be more reliable than clipping the distal draining vein, which might have resulted in the opening of other small draining channels that were not seen at angiography. Transarterial embolization of dural AVFs is effective in obliterating or reducing the arterial inflow from the external carotid arteries, but often cannot obliterate feeding arteries from the internal carotid arteries. Radiosurgery may also be effective for dural AVFs (9, 36), although a long posttreatment interval is required before the lesion is obliterated.

## Conclusion

We believe that dural AVFs of the cavernous sinus that drain into leptomeningeal veins should be treated urgently, since these lesions have a high risk of bleeding. The surgical transvenous embolization technique presented here is an alternative to direct sinus surgery for patients with a dural AVF of the cavernous sinus that drains only into veins of the sylvian fissure.

## References

1. Newton TH, Cronqvist S. **Involvement of dural arteries in intracranial arteriovenous malformations.** *Radiology* 1969;93:1071–1078
2. Chaudhary MY, Sachdev VP, Cho SH, Weitzner I Jr, Puljic S, Huang YP. **Dural arteriovenous malformation of the major venous sinuses: an acquired lesion.** *AJNR Am J Neuroradiol* 1982;3:13–19
3. Houser OW, Campbell JK, Campbell RJ, Sundt TM Jr. **Arteriovenous malformation affecting the transverse dural venous sinus: an acquired lesion.** *Mayo Clin Proc* 1979;54:651–661
4. Mironov A. **Pathogenetical consideration of spontaneous dural arteriovenous fistulas (DAVFs).** *Acta Neurochir (Wien)* 1994;131:45–58
5. Awad IA, Little JR, Akrawi WP, Ahl J. **Intracranial dural arteriovenous malformations: factors predisposing to an aggressive neurological course.** *J Neurosurg* 1990;72:839–850
6. Barnwell ST, Halbach VV, Higashida RT, Hieshima GB, Wilson CB. **Complex dural arteriovenous fistulas: results of combined endovascular and neurosurgical treatment in 16 patients.** *J Neurosurg* 1989;71:352–358
7. Brown RD Jr, Wiebers DO, Nichols DA. **Intracranial dural arteriovenous fistulae: angiographic predictors of intracranial hemorrhage and clinical outcome in nonsurgical patients.** *J Neurosurg* 1994;81:531–538
8. Ishii K, Goto K, Ihara K, et al. **High-risk dural arteriovenous fistulae of the transverse and sigmoid sinuses.** *AJNR Am J Neuroradiol* 1987;8:1113–1120
9. Link MJ, Coffey RJ, Nichols DA, Gorman DA. **The role of radiosurgery and particulate embolization in the treatment of dural arteriovenous fistulas.** *J Neurosurg* 1996;84:804–809
10. Barrow DL, Krithi A. **Cavernous sinus dural arteriovenous malformations.** In: Awad IA, Barrow DL, eds. *Dural Arteriovenous Malformations.* American Association of Neurological Surgeons; 1993:117–130
11. Debrum GM. **Angiographic workup of a carotid cavernous sinus fistula (CCF) or what information does the interventionalist need for treatment?** *Surg Neurol* 1995;44:75–79

12. Halbach VV, Higashida RT, Hieshima GB, Reicher M, Norman D, Newton TH. **Dural fistulas involving the cavernous sinus: results of treatment in 30 patients.** *Radiology* 1987;163:437-442
13. Halbach VV, Higashida RT, Hieshima GB, Hardin CW, Pribram H. **Transvenous embolization of dural fistulas involving the cavernous sinus.** *AJNR Am J Neuroradiol* 1989;10:377-383
14. Mullan S. **Reflections upon the nature and management of intracranial and intraspinal vascular malformations and fistulae.** *J Neurosurg* 1994;80:606-616
15. Borden JA, Wu JK, Shucart WA. **A proposed classification for spinal and cranial dural arteriovenous fistulous malformations and implications for treatment.** *J Neurosurg* 1995;82:166-179
16. Lalwani AK, Dowd CF, Halbach VV. **Grading venous restrictive disease in patients with dural arteriovenous fistulas of the transverse/sigmoid sinus.** *J Neurosurg* 1993;79:11-15
17. Lasjaunias P, Chiu M, Brugge KT, Tolia A, Hurth M, Bernstein M. **Neurological manifestations of intracranial dural arteriovenous malformations.** *J Neurosurg* 1986;64:724-730
18. d'Angelo VA, Monte V, Scialfa G, Fiumara E, Scotti G. **Intracerebral venous hemorrhage in "high-risk" carotid-cavernous fistulas.** *Surg Neurol* 1988;30:387-390
19. Halbach VV, Hieshima GB, Higashida RT, Reicher M. **Carotid cavernous fistulae: indications for urgent treatment.** *AJR Am J Roentgenol* 1987;149:587-593
20. Hiramatsu K, Utsumi S, Kyoji K, et al. **Intracerebral hemorrhage in carotid-cavernous fistula.** *Neuroradiology* 1991;33:67-69
21. Lin TK, Chang CN, Wai YY. **Spontaneous intracerebral hematoma from occult carotid-cavernous fistula during pregnancy and puerperium: case report.** *J Neurosurg* 1992;76:714-717
22. Tanaka A, Fukushima T, Tomonaga M. **Intracerebral hematomas in cases of dural arteriovenous malformation and carotid-cavernous fistula.** *Surg Neurol* 1986;25:557-562
23. Turner DM, Vangilder JC, Mojtahedi S, Pierson EW. **Spontaneous intracerebral hematoma in carotid cavernous fistula.** *J Neurosurg* 1983;59:680-686
24. Vaghi MA, Savoirdo M, Strada L. **Unusual computerized tomography appearance of a carotid-cavernous fistula.** *J Neurosurg* 1983;58:435-437
25. Chaloupka JC, Goller D, Goldberg RA, Duckwiler GR, Martin NA, Vinuela F. **True anatomical compartmentalization of the cavernous sinus in a patient with bilateral cavernous dural arteriovenous fistulae: case report.** *J Neurosurg* 1993;79:592-595
26. Courtheoux P, Labbe D, Hamel C, Lecoq PJ, Jahara M, Theron J. **Treatment of bilateral spontaneous dural carotid-cavernous fistulas by coils and sclerotherapy.** *J Neurosurg* 1987;66:468-470
27. Miller NR, Monsein LH, Debrum GM, Tamargo RJ, Nauta HJ. **Treatment of carotid-cavernous sinus fistulas using a superior ophthalmic vein approach.** *J Neurosurg* 1995;83:838-842
28. Takahashi A, Yoshimoto T, Kawakami K, Sugawara T, Suzuki J. **Transvenous copper wire insertion for dural arteriovenous malformations of cavernous sinus.** *J Neurosurg* 1989;70:751-754
29. Albert P, Polaina M, Trujillo F, Romero J. **Direct carotid sinus approach to treatment of bilateral carotid-cavernous fistulas.** *J Neurosurg* 1988;69:942-944
30. Dolenc V. **Direct Microsurgical repair of intracavernous vascular lesions.** *J Neurosurg* 1983;58:824-831
31. Isamat F, Ferrer E, Twose J. **Direct intracavernous obliteration of high-flow carotid-cavernous fistulas.** *J Neurosurg* 1986;65:770-775
32. Mullan S. **Treatment of carotid-cavernous fistulas by cavernous sinus occlusion.** *J Neurosurg* 1979;50:131-144
33. Nishijima M, Kamiyama K, Oka N, Endo S, Takaku A. **Electrothrombosis of spontaneous carotid-cavernous fistula by copper needle insertion.** *Neurosurgery* 1984;14:400-405
34. Parkinson D. **Carotid cavernous fistula: direct repair with preservation of the carotid artery.** *J Neurosurg* 1973;38:99-106
35. Barker FG II, Ogilvy CS, Chin JK, Joseph MP, Pile-Spellman J. **Transethmoidal transphenoidal approach for embolization of a carotid-cavernous fistula: case report.** *J Neurosurg* 1994;81:921-923
36. Pierot L, Poisson M, Jason M, Pontvert D, Chiras J. **Treatment of type D dural carotid-cavernous fistula by embolization followed by irradiation.** *Neuroradiology* 1992;34:77-80