
Adult Choroidal Vein of Galen Malformation

Thomas A. Tomsick, Robert J. Ernst, John M. Tew, Thomas G. Brott, and John C. Breneman

Summary: We report staged embolization and stereotactic radiation in a true adult choroidal vein of Galen malformation. Management dilemmas and their resolutions are also discussed.

Index terms: Vein of Galen; Arteriovenous malformations, cerebral; Arteriovenous malformations, embolization

We report a case of an adult choroidal vein of Galen malformation successfully treated by staged transarterial embolization, stereotactic radiation, and postembolization anticoagulation. The treatment of this patient raised many difficult issues, including shunt treatment of long-standing hydrocephalus with coexisting vein of Galen malformation; optimal route and method of embolization; impaired cerebrovascular autoregulation after total occlusion of a long-standing fistula; and possible thromboembolic venous occlusion, as well as posttreatment occlusive venopathy.

Case Report

A 25-year-old white woman presented in 1990 with worsening generalized headaches. A skull film at age 18 years after head trauma had shown changes typical of hydrocephalus and peripheral ringlike calcification of a vein of Galen aneurysm. These findings were confirmed with computed tomography. Lack of specific symptoms prompted conservative observation.

History included attainment of normal motor landmarks, but clumsiness at play without focal motor deficits. She exhibited low average performance in primary and secondary schools and 1 year at college. The patient worked as a nurse's aide. Physical examination disclosed obesity (101 kg), optic disk pallor, and a cranial bruit. Hydrocephalus and a vein of Galen malformation were reconfirmed with magnetic resonance (MR) imaging (Fig 1). Cerebral arteriography outlined the arterial contribution from the pericallosal artery, right and left posterior

choroidal arteries, and right anterior and posterior thalamoperforate arteries, as well as absent straight and persistent falcine sinuses (Fig 1B-E).

Uncertainty as to the exact cause of headaches in an obese woman and reluctance to shunt long-standing hydrocephalus as a first treatment led to a therapeutic plan that included initial embolization of the single largest feeding artery, the pericallosal artery. To attempt complete occlusion with acrylic injection in hopes of occluding the entire malformation and its outflow was considered too dangerous in such a voluminous (estimate, 29 mL) malformation.

In February 1991, pressure in the aneurysmal vein was 18 mm Hg when measured via transfemoral venous approach. Partial occlusion of the largest feeding artery, the pericallosal artery, was performed with seven platinum coils. The nidus of thalamoperforate and mesencephalic collaterals at their junction with the fistula was treated with stereotactic radiosurgery to a single isocenter by using a 17.5-mm collimator, delivering 2250 cGy to the 80% isodose line. Diminution of headaches was achieved temporarily.

Headaches recurred to preembolization levels, and complete occlusion of the distal pericallosal artery was performed with *N*-butyl-cyanoacrylate (NBCA) in March 1992. In October 1992, two right posterior choroidal artery pedicles were occluded with coils and NBCA. Two months later, two left posterior choroidal pedicles were embolized with platinum coils and NBCA. During the final procedure 1 month later, response of the irradiated nidus was documented (Fig 2). Using temporary balloon occlusion of the basilar artery-P1 junction, the largest remaining right posterior choroidal artery feeder was embolized with a mixture of NBCA (1 mL), tantalum (0.3 g), and ethiodized oil (0.2 mL) (total volume, 1 mL). Nearly total occlusion of the choroidal vein of Galen malformation occurred immediately. The femoral sheath was left in place, and partial thromboplastin time was maintained at twice baseline. Total occlusion of the malformation was documented 24 hours later (Fig 3). Warfarin treatment was begun. Follow-up MR and MR angiography at 3 and 10 months suggested continued total occlusion and thrombotic shrinkage

Received July 27, 1993; accepted after revision December 6.

From the Departments of Radiology (T.A.T., R.J.E.), Neurosurgery (T.A.T., J.M.T.), and Neurology (T.G.B.), University Hospitals and Good Samaritan Hospital, Cincinnati, Ohio; and the Division of Radiation Oncology, University Hospitals, Cincinnati, Ohio (J.C.B.).

Address reprint requests to Thomas A. Tomsick, MD, Division of Neuroradiology, University Hospital, 234 Goodman St, ML 0742, Cincinnati, OH 45267.

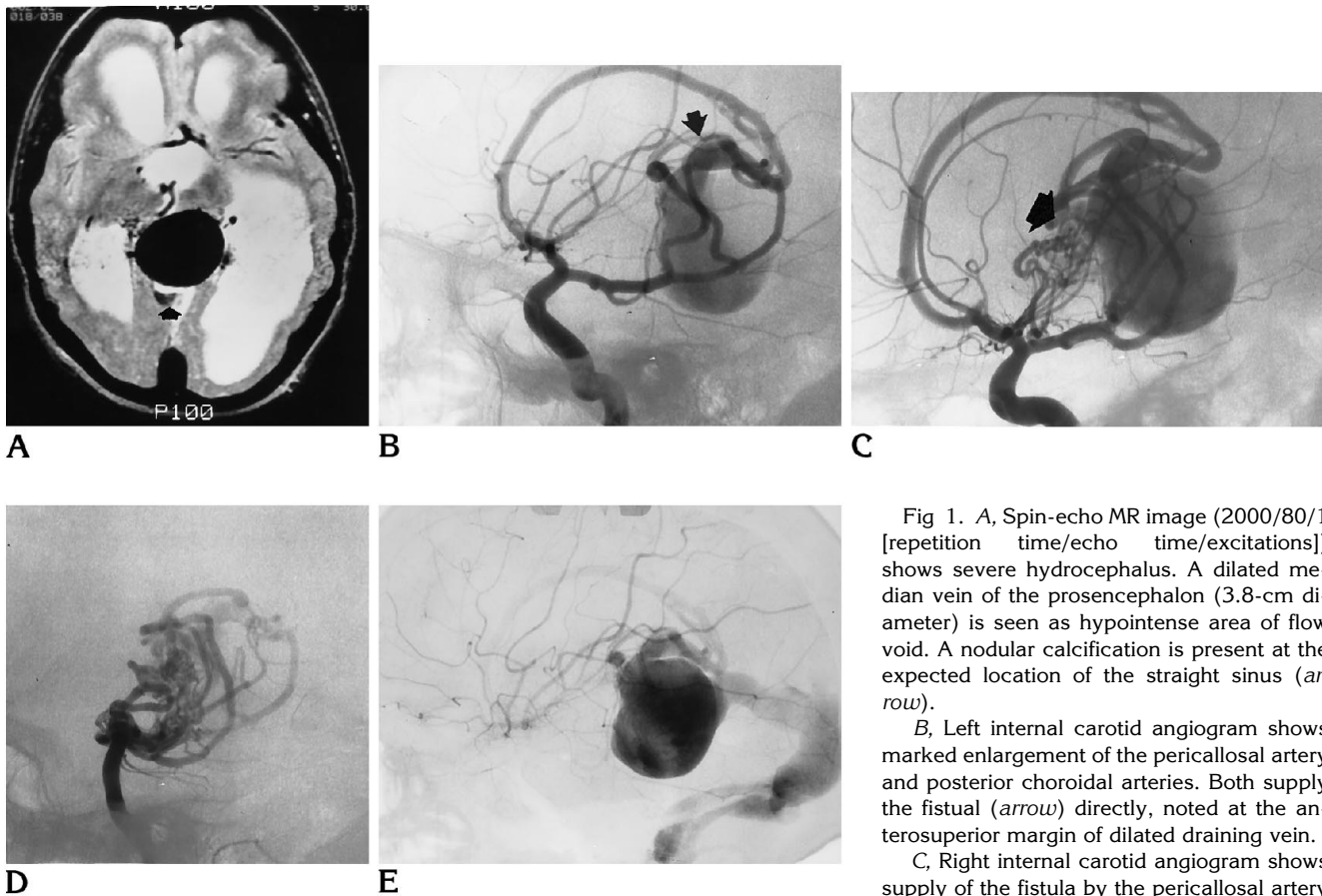


Fig 1. A, Spin-echo MR image (2000/80/1 [repetition time/echo time/excitations]) shows severe hydrocephalus. A dilated median vein of the prosencephalon (3.8-cm diameter) is seen as hypointense area of flow void. A nodular calcification is present at the expected location of the straight sinus (*arrow*).

B, Left internal carotid angiogram shows marked enlargement of the pericallosal artery and posterior choroidal arteries. Both supply the fistula (*arrow*) directly, noted at the anterosuperior margin of dilated draining vein.

C, Right internal carotid angiogram shows supply of the fistula by the pericallosal artery and the right posterior choroidal arteries.

Right lenticulostriate and anterior thalamoperforate arteries converge at a nidus anterior to, and contributing to, the fistula (*arrow*).

D, Vertebral angiogram shows bilateral enlarged posterior choroidal arteries. The nidus of the angiomatous collaterals is created via posterior thalamoperforate arteries.

E, Late arterial phase of left carotid angiogram shows the enlarged medial vein of the prosencephalon with absence of the straight sinus and persistence of the falcine sinus. Relative stenosis of the transverse sinus is present.

of the malformation (Fig 4). The headaches diminished and the patient was being considered for endoscopic third ventriculostomy or a shunt procedure for hydrocephalus.

Discussion

The vein of Galen malformation is a true vascular malformation involving the development of the vein of Galen (1, 2). The pathology is an arteriovenous fistula in the wall of an embryologic venous precursor, the median vein of the prosencephalon. A normal vein of Galen does not exist, but is replaced by the persistence of this embryologic midline venous structure that drains only the arteriovenous fistula. It does not

drain normal tissue and does not communicate with the normal cerebral veins. The fistula can be of two types: choroidal or mural. The choroidal shunt is seated in the cistern of the velum interpositum, and arterial feeders are usually bilateral, corresponding to the normal arteries supplying the choroidal structures. This type of malformation usually presents with heart failure in the newborn. The latter mural shunt is most often in the inferolateral margin of the prosencephalic vein, usually supplied by the collicular or posterior choroidal arteries.

Clinical presentation depends not only on arterial supply, but also on venous drainage. Stenoses in the venous egress may limit cardiac

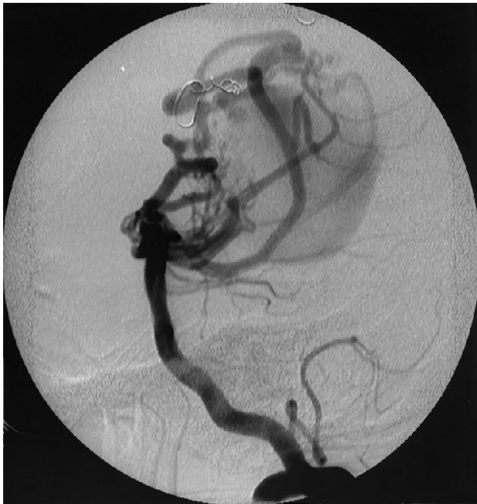

Fig 2. Vertebral angiogram after coil embolization of the pericallosal and a posterior choroidal artery, and 21 months after stereotactic radiation to the thalamoperforate-fistula junction. The nidus has diminished substantially compared with Figure 1D.

return, preventing congestive heart failure. Venous stenosis may also contribute to greater enlargement of the vein, creating aqueductal compression (3). With outlet stenosis, a pressure differential between the median vein of the prosencephalon and draining sinuses usually

occurs. In some patients, when the median vein of the prosencephalon is dilated out of proportion to the draining sinus, stagnant flow is shown on angiography, causing a greater likelihood of spontaneous thrombosis or thrombosis with minimal embolotherapy (4). No pressure differential existed in our patient despite clinical symptoms, an occluded straight sinus, and a relatively thin falcine sinus; pressures of 18 mm Hg extended from the vein of Galen to the right transverse sinus.

Patients with all types of vein of Galen malformations can present with hydrocephalus because of direct aqueductal compression, or possibly increased production of cerebrospinal fluid from increased choroidal blood flow or venous hypertension affecting cerebrospinal fluid absorption (5, 6). Despite massive asymptomatic hydrocephalus at the time of initial trauma, our patient had never required evaluation of symptoms of hydrocephalus.

A review of the literature revealed three cases of true vein of Galen malformation presenting in adulthood, as documented by arteriography. One was a mural malformation in a 36-year-old man seen because hydrocephalus, which initially was treated unsuccessfully with a shunt without development of subdural hematomas and then was treated successfully by surgical ligation and clipping of the feeding vessels (7). A 19-year-old woman with a mural malforma-

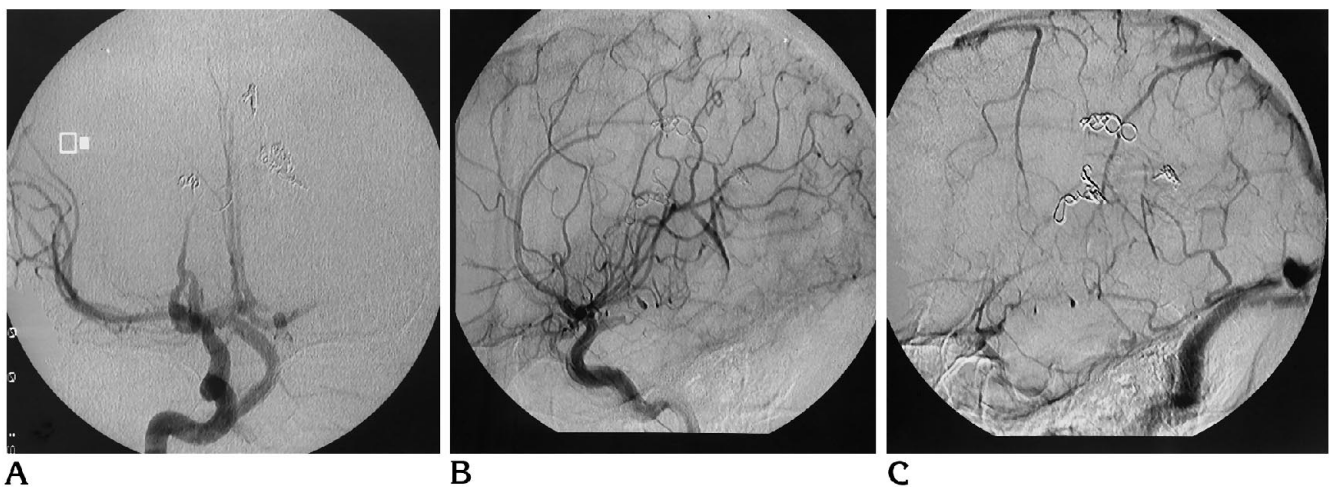


Fig 3. A, Anteroposterior right carotid arteriogram creates abundant reflux down the basilar artery without fistulous filling. (Vertebral arteriogram showed very slow flow into the basilar artery without fistulous filling.)

B, Lateral view of right carotid angiogram after final embolization shows stagnant slow flow in pericallosal and a posterior choroidal artery without evidence of residual nidus or fistula.

C, Venous phase of right carotid angiogram shows nonfilling of medial prosencephalon vein. The superior sagittal and transverse sinuses are patent.

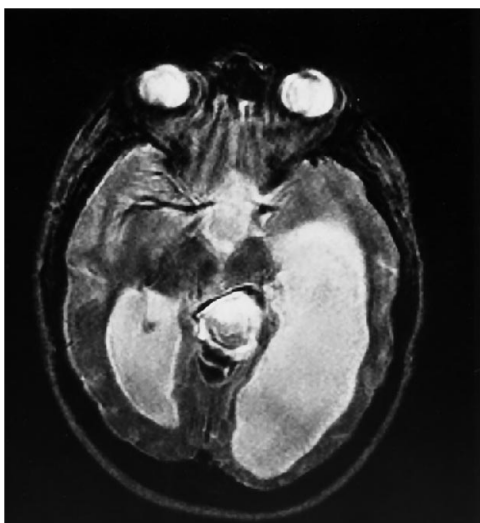


Fig 4. Axial spin-echo MR image (2450/100/2) 10 months after treatment shows hyperintensity within the shrunken median vein of the prosencephalon, with peripheral hypointensity of calcium and/or hemosiderin. MR angiography showed no arterial flow to the median vein of the prosencephalon.

tion presented with ischemic symptoms and was treated surgically. Transient postoperative cerebral edema occurred, but the patient recovered uneventfully (8). Berenstein and Lasjaunias (2) reported one case of a vein of Galen malformation in an adult, but the exact type was not described.

Total occlusion of a vein of Galen malformation with a limited number of feeders can be achieved with single transarterial injections of acrylic. Generally, this has been reported with smaller anatomic fistulous channels and lower fistulous flow volumes (9). In our patient, we had great concern that a single injection might wash beyond the falcine sinus to the sagittal and transverse sinuses, with attendant complications. Therefore, a plan of staged coil and acrylic embolization and radiation was created to ultimately allow a final acrylic injection with other arterial flow sources reduced (10). Staged embolization for a choroidal type of malformation is often preferred because of the complexity of arteriovenous fistulas and the poorly understood hemodynamics (11).

The nidus of right thalamoperforate and mesencephalic vessels presented a dilemma: Would the vessels suffer the effects of impaired autoregulation after total occlusion of the choroidal vein of Galen malformation when subjected to

systemic pressures, having been subjected to lowered shunt perfusion pressures for 25 years (12)? Morgan and Sundt (8) suggested that a death after a complete vein of Galen resection might have been caused by impaired cerebrovascular autoregulation. With no other model to answer the question, a conservative approach toward the perforators was elected: focal radiation early in the course of management, with hopes that the patient's clinical condition would allow an 18- to 24-month treatment plan before final embolization. Focal stereotactic irradiation effectively reduced the small nidus of thalamoperforators (Fig 4).

The final treatment dilemma of potential symptomatic venous occlusion was addressed with anticoagulation after the final procedure. With hope that the threat of thalamoperforate hyperperfusion breakthrough was reduced by radiation, full anticoagulation was administered to diminish the likelihood of propagation of thrombus by the original occlusive embolus, as well as to diminish the possibility of hyperplastic occlusive venopathy stimulating sinus occlusion. The latter phenomenon has been documented in certain vein of Galen malformations otherwise treated successfully (13).

This case report adds another block of information to the construction of a concept of the natural history of vein of Galen malformations. The results of therapeutic options chosen all contribute to the body of information to be referenced when treating similar patients in the future.

References

1. Yasargil MG. *Microneurosurgery*, vol III B. *Clinical Considerations, General and Specific Operative Techniques, Surgical Results, Nonoperated Cases, Cavernous and Venous Angioma. Neuroanesthesia*. New York: Thieme, 1988
2. Berenstein A, Lasjaunias P. Endovascular treatment of cerebral lesions. Berlin: Springer-Verlag, *Surgical Neuroangiography* 1992;4:267-313
3. Raylaud CA, Strother CM, Hald JK. Aneurysms of the vein of Galen: embryonic considerations and anatomical features relating to the pathogenesis of the malformation. *Neuroradiology* 1989; 31:109-128
4. Hurst RW, Kagetsu NJ, Berenstein A. Angiographic findings in two cases of aneurysmal malformation of the vein of Galen prior to spontaneous thrombosis: therapeutic implications. *AJNR Am J Neuroradiol* 1992;13:1446-1450
5. Seidenwurm D, Berenstein A, Hyman A, Kowalski H. Vein of Galen malformation: correlation of clinical presentation, arteriography and MR imaging. *AJNR Am J Neuroradiol* 1991;12:347-354

6. Zerah M, Garcia-Monaco R, Rodesch G, et al. Hemodynamics in vein of Galen malformations. *Childs Nerv Syst* 1992;8:111-117
7. Carson LV, Brooks BS, El Gammal T, et al. Adult arteriovenous malformation of the vein of Galen: a case report with preoperative and postoperative computed tomographic findings. *Neurosurgery* 1980;7:495-498
8. Morgan MK, Sundt TM. The case against staged operative resection of cerebral arteriovenous malformations. *Neurosurgery* 1989;25:429-435
9. Lasjaunias P, Rodesch G, Pruvost P, Laroche FG, Landreu P. Treatment of vein of Galen aneurysmal malformation. *J Neurosurg* 1989;70:746-750
10. Lylyk P, Vinuela F, Dion JE, et al. Therapeutic alternatives for vein of Galen vascular malformations. *J Neurosurg* 1993;78:438-445
11. Garcia-Monaco R, Lasjaunias P, Berenstein A. Therapeutic management of vein of Galen aneurysmal malformation. In: Vinuela F, Halbach V, Dian J, eds. *Interventional Neuroradiology*. New York: Raven, 1992:113-127
12. Spetzler RF, Wilson CB, Weinstein P, Mehdorn M, Townsend J, Telles D. Normal perfusion pressure breakthrough theory. *Clin Neurosurg* 1978;25:651-672
13. Duckwiler GR, Dion JE, Vinuela F, Reichman A. Delayed venous occlusion following embolotherapy of vascular malformations in the brain. *AJNR Am J Neuroradiol* 1992;13:1571-1579