

Methods for Normalization of Hippocampal Volumes Measured with MR

S. L. Free, P. S. Bergin, D. R. Fish, M. J. Cook, S. D. Shorvon, and J. M. Stevens

PURPOSE: To investigate the use of six cerebral measures as correlates for hippocampal volumes and, therefore, to enable normalized absolute hippocampal volumes to be calculated via two correction processes. **METHODS:** Hippocampal volumes and six cerebral measures were estimated from MR data in 20 control subjects. Three of these measures (the cranial volume, the cerebral volume, and the midsagittal cranial area) were then applied to a group of 32 control subjects, and regression analysis was performed to investigate the linear relationship between hippocampal volume and each measure. Division of hippocampal volume by cerebral measure and correction via a covariance calculation enabled corrected absolute hippocampal volumes to be determined for 32 control subjects and 23 patients with temporal lobe epilepsy. **RESULTS:** Correction processes reduced the variance in absolute hippocampal volumes in control subjects and enabled abnormally small absolute volumes to be defined. Of 11 patients with unilateral volume ratio abnormalities, 8 had unilateral abnormally small absolute hippocampal volumes. Of 12 patients with normal volume ratios, 4 had bilateral abnormally small absolute hippocampal volumes. **CONCLUSION:** Correction processes can define absolute hippocampal volumes for correlation studies and may enable identification of unsuspected bilateral hippocampal volume loss.

Index terms: Brain, measurements; Brain, volume; Hippocampus; Magnetic resonance

AJNR Am J Neuroradiol 16:637-643, April 1995

The measurement of the volume of the hippocampal formation on magnetic resonance (MR) images of the brain has been useful for the identification of hippocampal sclerosis (1). This has found its greatest clinical application in the assessment of patients with intractable complex partial seizures for surgical intervention (2-3). Other factors may also help identify hippocampal sclerosis: quantitative evidence of increased T2 values; and visual assessment of the disruption of internal architecture, volume loss, and intensity elevation (4-5). However, none has been shown to be as consistently useful and

relatively straightforward to apply as the volume estimates (3).

The validity of hippocampal volume measurement is highly dependent on the quality of the images from which measures are made. Early studies using thick (5 mm or more) and noncontiguous sections gave rise to some anomalous results (1). Stereologic principles can be applied to define coefficients of errors for anisotropic structures, such as the hippocampus, to show that sections must be less than or equal to 3 mm for an accuracy of volume measurement of 5% (6). The importance of using thin sections cannot be overestimated. Failure to recognize this, in our opinion, can lead to serious flaws. In addition, variations in the anatomic landmarks used contribute to the differences in absolute volumes described by different groups. Progress in the clarity of anatomic landmarks (7) and the generation of high anatomic quality, thin (3 mm or less), and contiguous-section MR data (6) has led to greater consistency.

Received April 26, 1994; accepted after revision October 10.

S.L.F. and P.S.B. received financial support from the Wellcome Trust.

From the Epilepsy Research Group, Institute of Neurology, London, United Kingdom (S.L.F., P.S.B., D.R.F., S.D.S.); Neuroscience Department, St Vincent's Hospital, Fitzroy, Victoria, Australia (M.J.C.); and MRI Unit, St Mary's Hospital, London, United Kingdom (J.M.S.).

Address reprint requests to S.L. Free, PhD, Epilepsy Research Group, Institute of Neurology, Queen Square, London WC1N 3BG, UK.

AJNR 16:637-643, Apr 1995 0195-6108/95/1604-0637

© American Society of Neuroradiology

In many centers only one observer performs hippocampal measurements; therefore, many studies report only intraobserver variation. Some studies do not discuss measurement validity at all (8). Even when observers train together and agree on anatomic landmarks, discrepancies up to 14% are reported when measuring the same hippocampus (9). However, the difference in the left-to-right hippocampal volume ratios between observers is often less than 5%. Hence, in our institution, ratios are usually used when there are several staff members measuring hippocampi for input to the clinical program.

Although unilateral hippocampal sclerosis is the most common precursor of temporal lobe epilepsy, postmortem evidence in unselected groups shows that, in up to one third of patients with hippocampal sclerosis, bilateral hippocampal damage has occurred (10). If the volume loss is equivalent bilaterally, no significant left-to-right volume difference will be observed and, hence, a normal ratio will be reported. Similarly, bilateral volume loss in which one hippocampus has lost more volume than the other generates an abnormal ratio but the evidence of bilateral damage is not revealed. This must have important consequences for subsequent surgical management and for correlation with neuropsychological and other functional data.

The definition of hippocampal volumes and their correlation with hippocampal sclerosis have raised interest in the correlation of volumes with other structural features or functional parameters. These include the assessment of the impairment of memory skills, effects of aging and dementia, and association with learning disabilities. However, the comparison of absolute volumes between patients and the definition of a normal range for control subjects will require some correction factor to account for differences in human build. A small female control subject may have smaller absolute volumes than a large male patient with a sclerotic hippocampus. Other studies have suggested division by the intracranial volume to correct for cerebral volumes (11) and corpus callosal area (12). With respect to hippocampi, workers have suggested division by whole brain volume (8). Jack et al (13) considered correction with the intracranial volume via a covariance method. These studies neither systematically compare a range of potential correction factors nor apply corrections to patient groups.

We have investigated the application of six measures of other cranial structures as possible correction factors for hippocampal volumes in an initial group of 20 control subjects. Two measures were then identified as the most promising and were extended to an additional 12 control subjects. The implications for the correlation process were investigated with respect to 23 patients with epilepsy.

Methods

All control subjects and patients were scanned on a 1.5-T MR scanner. All MR exams consisted of a routine sagittal (T1-weighted) scout sequence and an oblique axial dual-echo sequence (T2- and proton density-weighted). In addition, a coronal spoiled gradient-echo volume sequence (35/5/1 [repetition time/echo time/excitations] with a flip angle of 35°, matrix of 128 × 256, field of view of 24 cm, and 124 × 1.5-mm contiguous sections) was used to cover the whole cerebrum.

The acquisition of control data was approved by the Ethics Committee of the National Hospital for Neurology and Neurosurgery, London, United Kingdom, and all control subjects gave informed consent for an MR examination. Thirty-two control subjects, who had no history of neurologic deficit, illness, or trauma, were studied. Mean age was 27 years, with a range of 20 to 53 years. Nineteen subjects were men, thirteen were women.

Twenty-three patients with clinical and electroencephalographic (EEG) evidence of temporal lobe epilepsy were selected from the routine clinical program at the National Hospital. Twelve patients were known to have symmetric hippocampal volumes and 11 to have asymmetric hippocampal volumes.

Hippocampal Measurements

All measurements were performed on an independent console to which data were transferred from the scanner. The central portion of the coronal images was magnified three times, and a threshold marker was set to delineate the gray-white interface. The boundary of the hippocampal structure was traced, with a cross-hair cursor controlled by a tracker ball, to create a closed contour. The area of the enclosed region was estimated by pixel counting. Areas of the hippocampus on subsequent sections were added and multiplied by the section thickness for an estimate of the volume. The landmarks used for the definition of the hippocampus are as described by Cook et al (6).

Correlation Measures

The following six measures were investigated for their relationship to hippocampal volume in control subjects: (a) corpus callosum area on a midsagittal section; (b) cranial area on a midsagittal section; (c) parenchymal

area, excluding corpus callosum, on a midsagittal section; (d) area of the brain stem on an axial section at the level of the temporal horns; (e) cranial volume from area measurements taken on nine coronal sections, equally spaced throughout the cerebrum; and (f) cerebral volume from area measurements taken on nine coronal sections, equally spaced throughout the cerebrum.

The independent console provided reformatting facilities that enabled us to generate sagittal and axial images from the original coronal data set. For measures *a* to *c*, the same midsagittal section was used. This section was rotated to visually correct for the tilt of the subject in the scanner and a section chosen to minimize the white matter visible in the section. For measure *b*, the cranial cavity was traced along the inner limit of the subcutaneous fat over the convexity, along the margins of the cerebral hemispheres basally, and then along the brain stem, finishing at the foramen magnum. For measure *c*, the intradural projection of the cerebral hemispheres was traced, excluding the corpus callosum.

Reformatting enabled us to generate an axial section that had a visual correction for subject tilt and that was located so that the first inferior appearance of the temporal horns was observed in the section. For measure *d* the outline of the brain stem in this section was traced and the area was estimated.

For the two volume estimates (*e* and *f*), the area measurements were performed on the original coronal data set. For the cranial volume, the cranial cavity was traced, including the adjoining skull and the temporal bones. For the cerebral volume, the intradural area of the cerebrum was traced.

Measurement Variability

In this study, the hippocampal volumes of all subjects were measured by one operator alone (S.F.). Variation in the measurement of volumes by this operator was assessed by the measurement of 10 of the control subjects on four separate occasions. The difference in absolute volumes between the first and the fourth measurements ranged from 19% to 1%, with a mean of 9%. The difference in absolute volumes between the third and the fourth measurements ranged from 7% to 0%, with a mean of 3%. This indicates the improvement in operator consistency over time. The absolute volumes of the 32 controls reported here were all measured subsequent to the training period. To assess interobserver variability, 15 of the control subjects were also measured by a second observer (P.B.). The mean of the difference in absolute volumes between observers was 7%, with a range of 0% to 17%. For 12 of these 15 subjects, the difference in volume ratios between the two observers was less than 2% and for none of the studies was the ratio difference greater than 5%.

Of the correlation measures, two are reported as the means of four separate measurements (corpus callosum area and midbrain area). The cranial area and volume were measured for 10 controls on two separate occasions by the same observer (S.F.). These revealed differences

TABLE 1: Hippocampal volumes for 32 control subjects*

	Mean	Standard Deviation	Minimum	Maximum
All	2772:2799	260:302	2240:2244	3480:3537
Women (n = 13)	2530:2604	220:247	2240:2244	2904:3036
Men (n = 19)	2893:2932	236:265	2543:2502	3480:3537

* All values of hippocampal volume are given in mm³, as left volume:right volume.

between measurements of 2% or less. For 15 of the control subjects, the cerebral volume was measured by a second observer. The range of the difference in volumes estimated by the two observers was 0% to 4%, with a mean difference in volume of 2%.

Results

The means for the hippocampal volumes for the 32 control subjects are listed in Table 1. The ratio of smaller to larger hippocampus ranged from 93% to 100%, with a mean of 97%. A two-tailed Student's *t* test indicated a significant difference between the male and female hippocampal volumes ($P < .01$), with the men having larger hippocampi. Although the difference between left and right absolute hippocampal volumes was small, this difference was statistically significant when assessed with a two-tailed Student's *t* test ($P < .01$). This indicates the need to consider right and left hippocampi separately when performing any correction analysis.

The cerebral measures were applied to 20 control subjects (8 women and 12 men), and the mean results are shown in Table 2. The final column is the Pearson correlation coefficient for the given cerebral measurement and the left hippocampal volume.

TABLE 2: Measures of six cerebral parameters and their correlation with left hippocampal volume for 20 control subjects*

Measure	Mean \pm Standard Deviation	Range	Pearson Correlation Coefficient:L Hippocampus
Corpus callosum	7.25 \pm 0.70	5.77-8.45	0.26
Cranial area	183.73 \pm 11.98	148.79-205.67	0.58
Parenchymal area	96.72 \pm 7.49	72.8-106.52	0.38
Cranial volume	1753 \pm 154	1364-2010	0.63
Cerebral volume	1183 \pm 99	915-1313	0.70
Brain stem area	5.96 \pm 0.76	4.50-7.66	0.19

* All volumes are given in cm³, and all areas are given in cm².

On the basis of these results, three measurements were thought to be worthy of further consideration as correction factors for the hippocampal volume: the cranial area, the cranial volume, and the cerebral volume. These three measurements were also obtained for the additional 12 control subjects. Regression analysis was applied for each correlation measure in relation to the left and right hippocampal volumes. The means for the entire control group (n = 32) are shown in Table 3, along with the adjusted mr^2 value of the regression analysis. This value is a measure of the degree to which the hippocampal volume can be predicted from the appropriate cerebral measurement.

For the 23 patients with temporal lobe epilepsy, the absolute hippocampal volumes and the three cerebral measurements were obtained. The ratio of hippocampal volumes ranged from 65% to 100%, with absolute volumes ranging from 1622 to 3702. For the three cerebral factors, all but two of the values for the patients fell within two standard deviations from the mean of the values for the control subjects. Thus, we presume that the variation in the correlation measures in the patient group is consistent with that of the control group.

Our premise is that the correlation measures can be used to apply a correction to hippocampal volumes, thus enabling us to reduce or eliminate the variation caused by subject size. Some workers have corrected for subject size by dividing the hippocampal volume by the correction factor, whole brain volume (8, 11). Jack et al suggested a covariance estimate based on the strength of the linear relationship between the hippocampal volume and the correction factor (13).

In this study corrections have been applied in two ways: division of hippocampal volume by the three factors; and the covariance method,

TABLE 3: Measures of three cerebral parameters and analysis of regression with hippocampal volume

	Mean ± Standard Deviation	Range	Adjusted mr^2 *
Cranial area, cm^2	180.78 ± 12.68	148.79 –205.67	0.46:0.41
Cranial volume, cm^3	1723 ± 157	1364 –2010	0.50:0.53
Cerebral volume, cm^3	1174 ± 104	915 –1327	0.60:0.61

* The adjusted mr^2 of the regression analysis is tabulated as left hippocampus:right hippocampus.

TABLE 4: Standard deviation and coefficient of variation for hippocampal volumes after correction processes*

	All	Women	Men
Original Volume:L	260/9.4	220/8.7	236/8.2
Original Volume:R	302/10.8	247/9.5	265/9.0
Crct Volume:L	202/7.4	157/6.2	218/7.5
Crct Volume:R	203/7.3	154/5.9	233/7.9
Crct Area:L	209/7.6	160/6.3	224/7.7
Crct Area:R	228/8.1	183/7.0	252/8.6
Crct CVolume:L	200/7.3	159/6.3	221/7.6
Crct CVolume:R	207/7.4	143/5.5	246/8.4
Div/Volume:L × 10 ⁻³	0.124/7.8	0.099/6.2	0.137/8.5
Div/Volume:R × 10 ⁻³	0.121/7.4	0.090/5.5	0.138/8.5
Div/Area:L	0.012/7.9	0.009/6.1	0.013/8.4
Div/Area:R	0.013/8.4	0.010/6.6	0.014/8.9
Div/CVolume:L × 10 ⁻³	0.158/6.7	0.160/6.9	0.159/6.7
Div/CVolume:R × 10 ⁻³	0.160/6.7	0.128/5.4	0.182/7.6

Note.—Div/Volume represents division by cranial volume; Div/Area, division by cranial area; Div/CVolume, division by cerebral volume; and Crct, correction via covariance method.

* All values are listed as standard deviation followed by coefficient of variation.

as described by Jack et al (13). This method derives a corrected hippocampal value via the following equation:

$$NV = OV - \text{Grad} (CM_i - CM \text{ mean})$$

where NV is corrected hippocampal volume, OV is original hippocampal volume, Grad is the gradient of the regression line between the hippocampal volume and the cerebral measure, CM_i is the value of the appropriate cerebral measurement for that subject, and CM mean is the mean value of that measure for all control subjects.

These corrections were applied first for the control subjects as a group and then when the subjects were separated by sex. The covariance estimate considered left and right hippocampi separately. Corrected values were obtained for all control subjects; standard deviations and coefficients of variation for these group values are shown in Table 4. The values for the uncorrected data are also shown for comparison. Figure 1 is a graph of the left hippocampal volume versus the cranial volume. The original left hippocampal volume for all control subjects and the corrected volume, obtained via the covariance method using cranial volume, are shown.

Abnormal volumes were defined as those two standard deviations below the mean for the control subjects for corrected and uncorrected data. The correction via the cranial volume produced

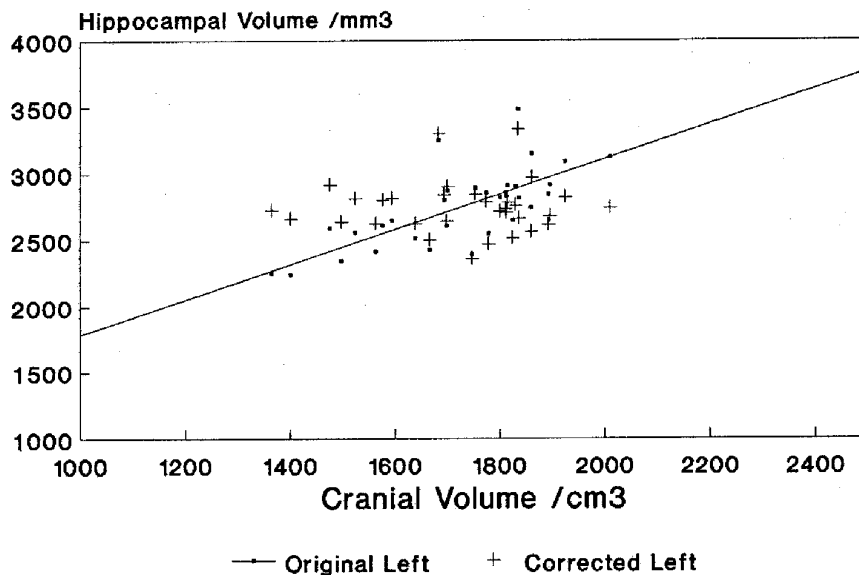


Fig 1. Left hippocampal volume, corrected and uncorrected, against cranial volume for 32 control subjects.

the most consistent reduction in standard deviation for the hippocampal volumes; therefore, this measure has been used to apply the correction process to the 23 patients. Men and women were considered separately.

Of the 11 patients with hippocampal volume ratios of less than 90%, suggesting unilateral hippocampal damage, 7 had unilateral volume loss via the original data and via the division correction process. Correction via the covariance method identified an eighth subject having unilateral volume loss. The remaining 3 subjects did not have evidence of abnormally small hippocampi on the basis of absolute or corrected measures.

Of the 12 patients with hippocampal volume ratios greater than 90%, analysis of the uncorrected hippocampal volumes suggested that 2 had bilateral volume loss and 3 had unilateral volume loss. However, the correction methods, via division or covariance, identified bilateral volume loss in an additional patient and indicated that one patient had bilateral volume loss when the uncorrected data suggested a unilateral volume loss. The other 2 subjects with unilateral volume loss from the uncorrected data had no abnormalities of volume after correction.

Of the four patients with bilateral volume loss after correction, absolute volume ratios were 95% in three cases and 96% in one case. Patient 1 had bacterial meningitis at 11 months of age with no convulsions. Scalp EEG consistently

showed bilateral onset, as did depth EEG recording. Ictal single-photon emission computed tomography was inconclusive with respect to lateralization, and psychometry implicated both hemispheres, with the dominant hemisphere being more affected. Patient 2 had bacterial meningitis at the age of 8 months with no convulsions. Scalp EEG consistently showed bilateral theta activity and epileptiform discharges from both temporal lobes. Psychometry indicated that the patient had a verbal IQ of 72 and a performance IQ of 70. Patient 3 had encephalitis at 30 years of age. An acute MR T2-weighted scan indicated high signal in both temporal lobes, which resolved on a subsequent scan 9 months later. Scalp EEGs indicated consistent bilateral slow activity with no asymmetry and independent bilateral epileptiform discharges. This pattern was maintained in scalp EEGs obtained 1 year after the acute episode. Finally, patient 4 had seizure onset at 9 years of age with no known cause, no history of febrile seizures, and predominantly generalized convulsions. Scalp EEG showed predominantly generalized activity with no lateralizing information. This patient was lost to subsequent follow-up. For the other 19 patients studied, a detailed clinical history and EEG telemetry recording were available for 17 patients. Only 1 of these patients had an identified cause of encephalitis/meningitis. Of the 17, 12 had unilateral epileptiform discharges on EEG recordings, the remainder being either bilateral or generalized.

Thus, 3 of the 4 patients with bilateral volume loss clearly represent a distinct clinical group separate from the patients with no bilateral volume loss.

Discussion

The absolute volumes of the hippocampus for 32 control subjects are consistent with other measures reported in the literature, although they are slightly smaller. The ratios of the hippocampal volumes for the control subjects ranged from 93% to 100%. Cook et al (6) reported no ratio less than 96% for controls but this was for a group of 10 control subjects only. Paired Student's *t* tests suggest that the means for male and female control subjects are different ($P < .01$).

The chosen measures of other cranial structures exhibited a range of values for the control subjects as expected. The values for the corpus callosum area are consistent with those reported elsewhere (12). There were significant differences between male and female control values for the cranial area and cranial volume measure ($P < .01$). For the patient group studied, all but two values of these correlation measures fell within two standard deviations of the mean for the controls.

Regression analysis reveals a linear correlation between the hippocampal volumes of the controls and the defined correction measures. This enables a correction via the covariance method, as described by Jack et al (13), and the definition of mean and standard deviations for the corrected volumes for the control subjects. The strongest correlation was between hippocampal volume and cerebral volume. However, the correction measures were applied for three cerebral measures: the cranial volume, the cranial area, and the cerebral volume. All correction processes resulted in a reduction in variance in the corrected hippocampal volumes, with respect to the original data. There was a further reduction when men and women were considered separately. For the covariance correction, using the cranial volume resulted in the most consistent reduction in variance, and this method was used to investigate the patient data. After correction using covariance applied to cranial volumes, control volumes were still normally distributed, when men and women were considered in combination or separately. Thus, a volume less than two standard devia-

tions below the mean was used to define an abnormally small hippocampus.

Of 11 patients with a hippocampal volume ratio less than 90%, 7 were identified as having unilateral volume loss because one of their absolute hippocampal volumes was less than two standard deviations below the mean for the absolute volumes of the control subjects. Correction via division did not alter this number. Correction via the covariance method increased this group to 8. Of this group, 7 have had temporal lobectomy or hippocampectomy, with 7 proven cases of hippocampal sclerosis. The eighth patient did not proceed to surgery. For none of this group did the correction process suggest that the contralateral hippocampus was abnormally small.

The other three patients, with hippocampal volume ratios less than 90%, had no absolute volume loss less than two standard deviations below the mean for the control subjects, using either the original uncorrected absolute volume data or the corrected data. Temporal lobectomies have been performed on two subjects (two women, hippocampal volume ratios 72% and 86%) and hippocampal sclerosis has been confirmed pathologically. The third subject, a man with a hippocampal volume ratio of 82%, is undergoing further investigation. Thus, none of the correction processes could identify 3 of 11 subjects with evidence of unilateral hippocampal damage. Absolute or corrected hippocampal volumes are not as sensitive as hippocampal volume ratios for the detection of unilateral hippocampal sclerosis.

However, of 12 patients with hippocampal volume ratios greater than 90%, the covariance correction processes identified previously unrecognized bilaterally small hippocampi in 4 patients. Estimates of abnormal volumes from the original uncorrected data set did not identify abnormal volume loss in one of these cases. In another case, the correction via division revealed only a unilateral abnormal volume. None of these patients has been treated surgically and pathologic confirmation has not been obtained. However, the prevalence of encephalitis/meningitis within this group, and the additional clinical, EEG, psychometric, and imaging information about these patients identifies them as a distinct patient group in comparison with the patients in whom no bilateral volume loss was identified.

In summary, the correction via the covariance method was superior to the original data set and the correction via division in the identification of an additional unilateral volume loss and an additional bilateral volume loss. However, in three cases, no volume loss was identified, although subsequent surgery has identified hippocampal sclerosis in two of those subjects.

The use of correction processes for the hippocampal volumes of control subjects results in a reduction in variance of those volumes. In a data set of 23 patients, this enables the identification of four additional abnormalities when a correction via a covariance method is applied. The covariance correction process is dependent on the strength of the linear relationship between the cerebral measure and the hippocampal volume. Increasing the number of control subjects may strengthen this relationship for the enhancement of the correction process. The difference between the male and female control groups suggests that correction processes should be applied to male and female subjects separately. In comparison with other structural or functional measures, the correction via the covariance method is likely to be superior to correction via division or to no correction process.

The absolute hippocampal volume ratio is the most frequently used determinant of unilateral hippocampal sclerosis. However, we have shown that correction factors can be implemented, such that some subjects with no indication of asymmetry from the ratio measure are identified as having bilateral volume loss. This is important for the subsequent management of these cases. The generation of corrected absolute hippocampal volumes is also necessary for correlative studies with other clinical and investigative data.

Acknowledgments

We thank all members of the MRI unit at St Mary's Hospital, Paddington, London, United Kingdom, for their

assistance during data acquisition and analysis. We also thank A. A. Raymond, MD, and S. M. Sisodiya, MD, for helpful discussions.

References

1. Bronen RA, Cheung G, Charles JT, et al. Imaging findings in hippocampal sclerosis: correlation with pathology. *Am J Neuro-radiol* 1991;12:933-940
2. Ashtari M, Barr WB, Schawl N, Bogerts B. Three-dimensional fast low angle shot imaging and computerized volume measurement of the hippocampus in patients with chronic epilepsy of the temporal lobe. *Am J Neuro-radiol* 1991;12:941-947
3. Jack CR, Sharborough FW, Twomey CK, et al. Temporal lobe seizures: lateralisation with MR volume measurements of the hippocampal formation. *Radiology* 1990;175:423-429
4. Jackson GD, Berkovic SF, Tress BM, Kalnins RM, Fabinyi GCA, Bladin PF. Hippocampal sclerosis can be reliably detected by magnetic resonance imaging. *Neurology* 1990;40:1869-1875
5. Kuzniecky R, de la Sayette V, Ethier R, et al. Magnetic resonance imaging in temporal lobe epilepsy: pathological correlation. *Ann Neurol* 1987;22:341-347
6. Cook MJ, Fish DR, Shorvon SD, Straughan K, Stevens JM. Hippocampal volumetric and morphometric studies in frontal and temporal lobe epilepsy. *Brain* 1992;115:1001-1015
7. Watson C, Andermann F, Gloor P, et al. Anatomic basis of amygdaloid and hippocampal volume measurement by magnetic resonance imaging. *Neurology* 1992;42:1743-1750
8. Bhatia S, Bookheimer SY, Gaillard WD, Theodore WH. Measurement of whole temporal lobe and hippocampus for MR volumetry: normative data. *Neurology* 1993;43:2006-2010
9. Jack CR, Bentley MD, Twomey CK, Zinsmeister AR. MR imaging-based volume measurements of the hippocampal formation and anterior temporal lobe: validation studies. *Radiology* 1990;176:205-209
10. Margerison JHM, Corsellis JAN. Epilepsy and the temporal lobes: a clinical, electroencephalographic and neuropathological study of the brain in epilepsy. *Brain* 1966;89:479-530
11. Murphy DGM, DeCarli C, Schapiro MB, Rapoport SI, Horwitz B. Age-related differences in volumes of subcortical nuclei, brain matter, and cerebrospinal fluid in healthy men as measured with magnetic resonance imaging. *Arch Neurol* 1992;49:839-845
12. Laissy JP, Patrux B, Duchateau C, et al. Midsagittal MR measurements of the corpus callosum in healthy subjects and diseased patients: a prospective survey. *Am J Neuro-radiol* 1993;14:145-154
13. Jack CR, Twomey CK, Zinsmeister AR, Sharborough FW, Petersen R, Cascino GD. Anterior temporal lobes and hippocampal formations: normative volumetric measurements from MR images in young adults. *Radiology* 1989;172:549-554