

---

# MR in Adrenoleukodystrophy: Atypical Presentation as Bilateral Frontal Demyelination

A. Castellote, J. Vera, E. Vazquez, M. Roig, J. A. Belmonte, and A. Rovira

**Summary:** A case of rostrocaudal progression of adrenoleukodystrophy presented with hyperintense signal intensity bilaterally in the frontal lobe on MR images obtained with long repetition times and peripheral rim enhancement on postcontrast MR images obtained with short repetition times.

**Index terms:** Adrenoleukodystrophy; Brain, magnetic resonance; Pediatric neuroradiology

This report illustrates a case of adrenoleukodystrophy presenting as early bilateral symmetric frontal lobe white matter disease on magnetic resonance (MR). This is a very rare pattern in this condition, which in most cases shows occipital involvement as a presenting feature. This unusual rostrocaudal progression has been documented scarcely in the English-language literature (1–3).

## Case Report

A 9-year-old boy was the third child of a healthy 25-year-old mother, who had an uneventful pregnancy, labor, and delivery. The family history was unremarkable. His early developmental milestones were normal. Hyperpigmentation was noted at the age of 3 years, and hormonal tests for adrenal disorders disclosed Addison disease. An electroencephalogram showed no abnormalities. The patient did well with replacement treatment until the age of 9 years, when he presented with a 12-month history of progressive learning and behavioral problems, short attention span, hyperkinetic motor movements, and emotional disorders. Physical examination showed mild generalized pigmentation of the skin. No other abnormalities were noted.

An unenhanced computed tomogram of the brain showed bilateral symmetric low-density areas confined to the frontal white matter. T2-weighted MR images showed a hyperintense confluent lesion bilaterally in the frontal white matter. The lesion extended through the genu of the corpus callosum and reached both anterior limbs of the inter-

nal capsule (Fig 1A). In the brain stem, small lesions were seen bilaterally, corresponding to the location of the corticospinal tracts. Marked enhancement at the periphery of the lesions was observed after injection of gadopentetate dimeglumine (Fig 1B).

The diagnosis of adrenoleukodystrophy was strongly suggested from the medical history and radiologic findings. This diagnosis was confirmed by cultured skin fibroblast assay, which showed an abnormal amount of very-long-chain fatty acids.

## Discussion

The clinical course in adrenoleukodystrophy is characterized by behavioral disorders, ataxia, visual loss, decreased hearing, and epileptic seizures, followed by mental deterioration and death. Adrenal insufficiency is a usual finding, but does not always precede neurologic disease.

Biochemically, there is accumulation of very long fatty acids resulting from impairment of their peroxisomal oxidation. This accumulation probably decreases myelin membrane stability, leading to demyelination. Histologically, in the classical forms, demyelination begins bilaterally in the occipital region, extending across the splenium of the corpus callosum. Gradually the process spreads outward and forward as a confluent lesion, affecting the parietal, temporal, and finally, the frontal white matter, cerebellar white matter, cerebellar peduncles, and corticospinal and corticobulbar tracts. Calcium deposition can also be found (1).

MR is more sensitive than computed tomography (4–6) and correlates well with histologic features according to the zones described by Schaumburg et al (7). The outer zone of the lesions corresponds to the zone of active inflam-

---

Received January 12, 1993; accepted after revision November 30.

From the Departments of Pediatric Radiology (A.C., J.V., E.V.) and Pediatrics (J.A.B.) and the Institut de Diagnòstic per la Imatge (A.R.), Hospital Vall d'Hebron, Barcelona, Spain.

Address reprint requests to A. Castellote, MD, Department of Pediatric Radiology, Hospital Universitari Materno-Infantil Vall d'Hebron, Passeig Vall d'Hebron 119-129, 08035 Barcelona, Spain.

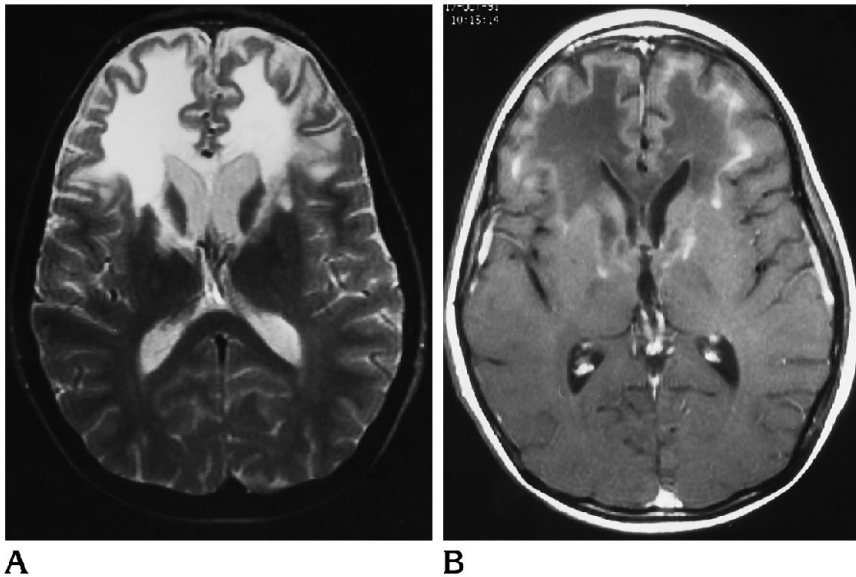


Fig 1. A, Axial T2-weighted spin-echo MR image (2500/20-90/1 [repetition time/echo time/excitations]) shows bilateral confluent hyperintense areas involving the frontal white matter, genu of the corpus callosum, and both anterior limbs of the internal capsule.

B, Axial T1-weighted spin-echo MR image (500/20/2) after injection of contrast material shows a rim of enhancement at the periphery of the lesion.

mation and enhances with contrast administration because of blood-brain barrier breakdown (8).

In our case, the location of the pathologic process was committed to the frontal white matter, genu of the corpus callosum, internal capsule, and brain stem. This constitutes an atypical and rare presentation pattern seldom described in previous reports (1-3).

Regardless of speculations about the pathologic substrate, we conclude that adrenoleukodystrophy may present in a broad spectrum of white matter disease. This indicates the need for radiologists to be aware of the diagnosis of adrenoleukodystrophy in boys who have behavioral disorders and/or adrenal insufficiency and show white matter disease on MR or computed tomography.

## References

1. Mac Donald JT, Stauffer AE, Heitoff K. Adrenoleukodystrophy: early frontal lobe involvement on computed tomography (case report). *J Comput Assist Tomogr* 1984;8:128-130
2. Moser HW, Naidu S, Kumar AJ, et al. The adrenoleukodystrophies. *Crit Rev Neurobiol* 1987;3:29-88
3. Scully RE, Mark EJ, McNeely BU. Case records of the Massachusetts General Hospital: case 5-1982. *N Engl J Med* 1982;306:286-293
4. Van der Knaap MS, Valk J. MR of adrenoleukodystrophy: histopathologic correlations. *AJNR Am J Neuroradiol* 1989;10:S12-S14
5. Bewermeyer H, Bamborschke S, Ebhardt G, et al. MR imaging in adrenoleukomyeloneuropathy. *J Comput Assist Tomogr* 1985;9:793-796
6. Kumar AJ, Rosenbaum AE, Naidu S, et al. Adrenoleukodystrophy: correlating MR imaging with CT. *Radiology* 1987;227:67-70
7. Schaumburg HH, Powers JM, Raine CS, et al. Adrenoleukodystrophy. *Arch Neurol* 1977;32:577-591
8. Di Chiro G, Eiben RM, Manz HJ, et al. A new CT pattern in adrenoleukodystrophy. *Radiology* 1980;137:687-692