

---

# Dural Cavernous Angioma: MR Features

Robert Vogler and Mauricio Castillo

**Summary:** The imaging features of a cavernous angioma, which originated from the meninges, are presented. The patient harbored a second cavernous angioma within the brain parenchyma. Cavernous angioma should be included in the differential diagnosis of dural lesions, especially when other cavernous angiomas are present.

**Index terms:** Angioma; Arteriovenous malformations, cerebral

Cavernous angioma, also known as cavernous hemangioma or cavernoma, was described by Luschka in 1853 as an incidental finding in a suicidal patient (1). Cavernous angiomas account for 5% to 13% of cerebral vascular malformations and are thought to be present at birth (2). Multiple lesions are not uncommon. Although cavernous angiomas may occur anywhere in the brain or spinal cord, only a few cases of primary dural cavernous angiomas have been reported (3–5). We present the magnetic resonance (MR) imaging features of a cavernous angioma arising in the dura mater.

## Case Report

A 35-year-old man presented with generalized seizures, headache, and left visual blurring of 2 months' duration. Medical history and physical examination findings were unremarkable. An electroencephalogram showed low background activity in the right parietal occipital region. Computed tomography (CT) scan demonstrated an extraaxial lesion in the right parietal region (Fig 1A). The mass had punctate calcifications and showed minimal contrast enhancement. MR imaging showed the lesion to be heterogenous with mainly intermediate signal intensity on precontrast T1-weighted images (Fig 1B). T2-weighted sequences showed the lesion to be of high signal intensity and surrounded by a halo of very low signal intensity (Fig 1C). The adjacent brain parenchyma showed abnormal high signal intensity. After gadolinium administration, the mass enhanced (Fig 1D). In addition, T2-weighted images showed a second lesion in the left midparietal region (Fig 1D). This lesion was of high signal intensity centrally and had an area of low signal intensity peripherally. Con-

ventional catheter angiogram was negative. At surgery, the right parietal occipital lesion was found to be completely extraaxial and dura based, and was entirely resected. Microscopy showed numerous vessels of variable size with distorted collagenized thin walls that had significant intimal fibrosis (Fig 1F). Calcifications and peripheral hemosiderin also were present.

## Discussion

Cavernous angiomas are commonly seen in the subcortical regions of the cerebral hemispheres, pons, or cerebellum, but may occur anywhere in the brain leptomeninges and spinal cord (6). The majority of cavernous angiomas remain asymptomatic in life and are incidental findings at autopsy. When they produce symptoms, these commonly include seizures, headache, hemorrhage, and focal or progressive neurologic deficits (7). Seizures are believed to occur secondary to a combination of mass effect and deposition of hemosiderin, which has epileptogenic properties (8). The risk of bleeding is small and usually not life threatening. The risk is increased in patients with a prior hemorrhage (9). Recurrent (mainly subclinical) bleeds cause encasement or pseudoencapsulation of the lesion by hemosiderin-stained gliotic tissues (10, 11).

Macroscopically discrete, cavernous angiomas are multiloculated, purple, mulberry-appearing masses filled with sinusoidal vascular channels separated by fibrous strands and no intervening neural tissues (2). They are thought to arise at the capillary level. Microscopically, the vessel walls lack muscle and elastic tissue, are lined by a single endothelial cell layer, and may be calcified or ossified (5). Close macrophages show extensive deposition of hemosiderin. Hemangioma calcificans, a variant of cavernous angioma, show extensive calcification (12). As many as half of patients with cav-

---

Received July 8, 1993; accepted after revision October 15.

From the Department of Radiology, University of North Carolina, Chapel Hill.

Address reprint requests to M. Castillo, MD, Department of Radiology, CB #7510, University of North Carolina, Chapel Hill, NC 27599-7510.

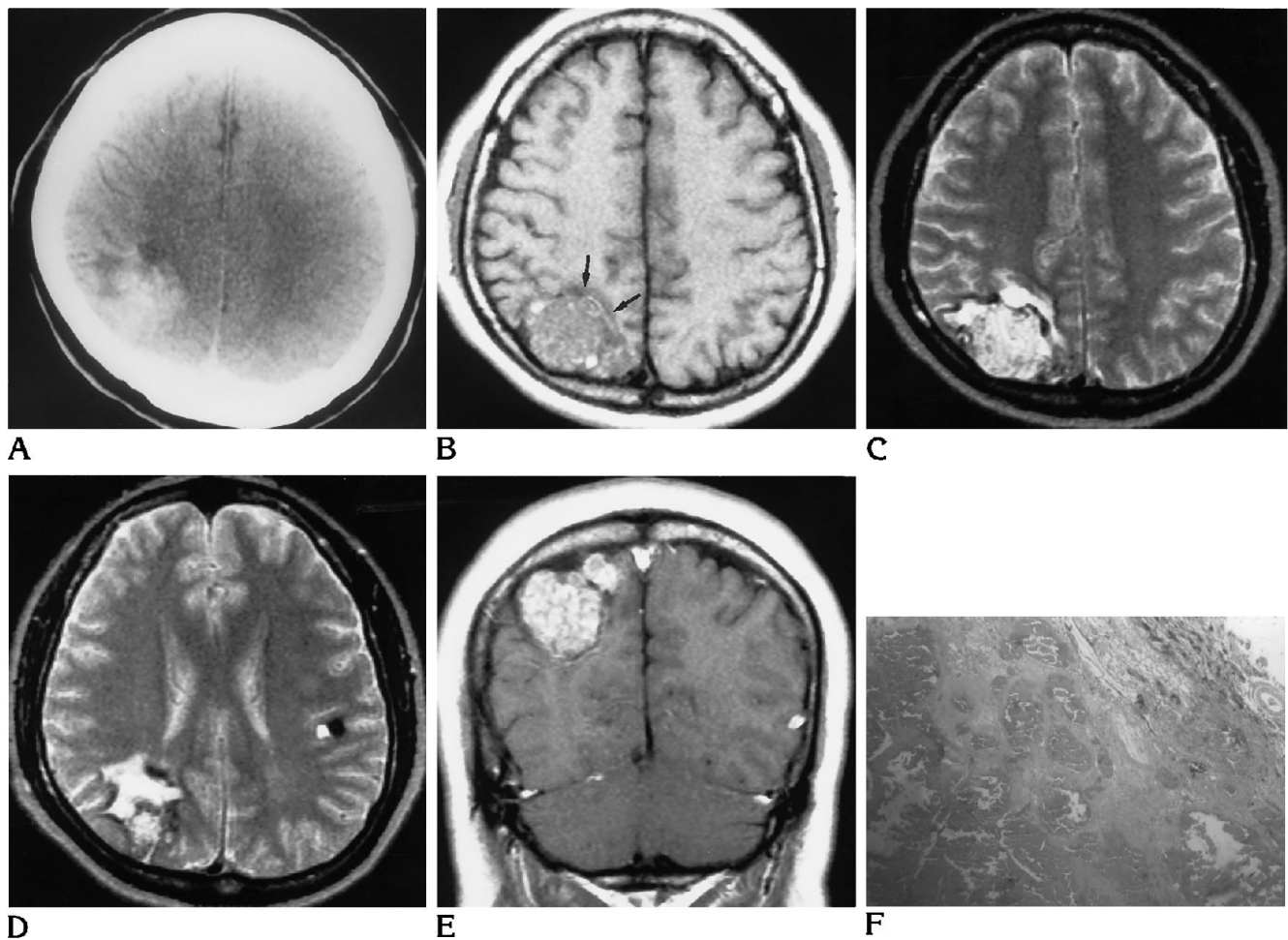


Fig 1. A, Plain CT shows a hyperdense mass in the right posterior parietal region. The mass contains some punctate calcifications, and there is low density in the adjacent brain anterior to the lesion.

B, Noncontrast axial T1-weighted image (600/15/1 [repetition time/echo time/excitations]) shows the lesion to be heterogenous but mainly of low signal intensity. There are some areas of high signal intensity in the periphery of the mass, and the underlying gray matter (*arrows*) is buckled, indicating the extraaxial location of the mass.

C, Axial spin-echo T2-weighted image (2500/90/1) at the same level as B shows the lesion to be inhomogeneous but generally hyperintense. A rim of very low signal ( hemosiderin) surrounds the mass. The underlying brain is of high signal intensity, probably reflecting gliosis and/or edema.

D, Axial T2-weighted image (2500/90/1) shows the inferior aspect of the lesion with abnormal high signal intensity in the underlying brain. A second smaller lesion is present in the left parietal region. This subcortical lesion is of high signal intensity and partially surrounded by an area of signal void believed to be hemosiderin.

E, Coronal postcontrast T1-weighted image (600/15/1) shows the right parietal lesion to enhance markedly.

F, Microscopic view of hematoxylin-eosin stain of the lesion. There are variable-size blood vessels with thin, distorted walls separated by fibrous tissue, areas of hemorrhage, cholesterol granulomas, and calcifications.

ernous angioma have a family history of similar lesions (5).

Cavernous angioma may be treated by surgical resection. The goals of surgery include control of progressive neurologic deficits, elimination of mass effect, treatment of medically refractory seizures, and prevention of hemorrhage (2, 11). Radiation therapy also may be useful in selected cases (13).

CT shows cavernous angiomas to be well-circumscribed, slightly hyperdense masses without adjacent edema or significant mass effect (14). Calcifications are seen in as many as 30% of lesions. After iodinated contrast infusion, mild enhancement may be seen. Occasionally, cavernous angiomas contain areas of low density that are thought to be related to old thrombosis and/or cystic degeneration. By MR imag-

ing, cavernous angiomas have a "salt and pepper" appearance (15). A peripheral rim of very low signal intensity is seen on all sequences and represents hemosiderin deposits within macrophages. After gadolinium administration, enhancement usually occurs but is variable. Catheter angiography is generally negative, although occasionally a faint vascular blush may be seen, especially after prolonged injection (16).

A recent article described similar MR findings in dural juvenile capillary hemangioma. Juvenile capillary hemangiomas are a subgroup of cavernous hemangioma (17).

In our patient, CT showed a hyperdense mass with internal calcifications (Fig 1A). MR confirmed the extraaxial location of the lesion and showed it to have heterogenous signal intensity surrounded by a rim of very low signal intensity (Fig 1B). The adjacent white matter also had abnormal high signal intensity on T2-weighted images that was most likely related to gliosis and/or edema (Fig 1C). The lesion enhanced markedly after gadolinium administration (Fig 1D). Presence of a second, smaller lesion similar in appearance to the larger one led us to postulate the possibility of vascular malformation; however, because we were not aware that cavernous angiomas may occur in the meninges, our main preoperative diagnosis was meningioma.

## References

1. Luschka H. Cavernöse Blutgeschwulste des Gehirns. *Arch Path Anat* 1853;6:458
2. Rapacki TFX, Brantley MJ, Furlow TW, Geyer CA, Toro VE, George ED. Heterogeneity of cerebral cavernous hemangiomas diagnosed by MR imaging. *J Comp Assist Tomogr* 1990;14:18-25
3. Hodges FJ. Pathology of the skull. In: Taveras JM, Ferrucci JT, eds. *Radiology. Diagnosis-Imaging-Intervention*. Philadelphia: JB Lippincott; 1986:9-10
4. Okada J, Hara M, Takevchi K. Dural hemangioma with extracranial component. *Acta Neurochir* 1977;36:111-115
5. Burger PC, Scheithauer BW, Vogel FS. Cerebrovascular disease. In: Burger PC, Scheithauer BW, Vogel FS, eds. *Surgical Pathology of the Nervous System and Its Coverings*. 3rd ed. New York: Churchill Livingstone; 1991:439-440
6. Voigt R, Yasargil MG. Cerebral cavernous haemangiomas or cavernomas: incidence, pathology, localization, diagnosis, clinical features and treatment: review of the literature and report of an unusual case. *Neurochirurgia* 1976;19:59-68
7. Tagle P, Huete I, Mendez J, del Villar S. Intracranial cavernous angioma: presentation and management. *J Neurosurg* 1986;64:720-723
8. Willmore LJ, Rubin JJ. Antiperoxidant pretreatment and iron-induced elliptiform discharges in the rat: EEG and histopathological studies. *Neurology* 1981;31:63-69
9. Simard JM, Garcia-Bengochea F, Ballinger WE, Mickle JP, Quisling RG. Cavernous angioma: a review of 126 collected and 12 new clinical cases. *Neurosurgery* 1986;18:162-172
10. Sigal R, Krief O, Houtteville JP, Halimi P, Doyor D, Pariente D. Occult cerebrovascular malformations: follow-up with MR imaging. *Radiology* 1990;176:815-819
11. Wilson CB. Cryptic vascular malformations. *Clin Neurosurg* 1992;38:49-84
12. Harbaugh RE, Roberts DW, Fratkin JD. Hemangioma calcifications: case report. *J Neurosurg* 1979;51:219-228
13. Scott RM, Barnes P, Kupsky W, Adelman L. Cavernous angiomas of the central nervous system in children. *J Neurosurg* 1992;76:38-46
14. Ahmadi J, Miller CA, Segall HD, Park S, Zee C, Becker RL. CT patterns in histopathologically complex cavernous hemangiomas. *AJNR Am J Neuroradiol* 1985;6:389-393
15. Imakita S, Nishamura T, Yamada N, et al. Cerebral vascular malformations: applications of magnetic resonance imaging to differential diagnosis. *J Neuroradiol* 1989;31:320-325
16. Namaguchi Y, Kishikawa T, Fukue M, et al. Prolonged injection angiography for diagnosing intracranial cavernous hemangiomas. *Radiology* 1979;131:137-138
17. Willing SJ, Faye-Petersen O, Aronin P, Faith S. Capillary hemangioma of the meninges. *AJNR Am J Neuroradiol* 1993;14:529-536