

---

# Cranial Hypertrophic Interstitial Neuropathy

John E. Jordan,<sup>1</sup> Barton Lane,<sup>1,4</sup> Michael Marks,<sup>1</sup> Yuan Chang,<sup>2</sup> and Monty Weinberger<sup>2,3</sup>

**Summary:** The authors describe a patient with complex cranial neuropathy caused by pathologically proved hypertrophic interstitial neuropathy. Plain and contrast-enhanced MR studies were performed prior to surgical exploration. Surgical complications caused the patient's death and a complete pathology study was done. Though nonspecific, MR proved helpful in determining the extent of disease and areas of anatomic involvement.

**Index terms:** Nerves, cranial; Neuropathy

Hypertrophic interstitial neuropathy (HIN) is a rare entity, typically causing focal or diffuse enlargement of peripheral nerves (1–5). HIN more commonly involves a single peripheral nerve, but there has been one report of isolated cranial nerve involvement (6). We report a case of HIN with involvement of at least two cranial nerves. This presentation was an isolated finding without any associated systemic disease. As of this writing, this is apparently the second case reported of cranial HIN and the first demonstrating magnetic resonance (MR) findings.

## Case Report

A 61-year-old woman of Hispanic origin presented with a 3-year history of diplopia, left temporal and intraorbital pain, and a 5-year progressive ptosis of the left eye. A left partial third nerve palsy with left eyelid droop and paresis of upward gaze were demonstrated on physical examination. In addition, there was a partial left sixth nerve palsy. Pupillary function, corneal reflexes, and facial sensations were within normal limits.

An MR scan of the sellar and parasellar region was performed before and after gadolinium administration (Fig. 1). This study demonstrated thickening of the third division of the left trigeminal nerve as it exited the foramen ovale (Fig. 1B). Diffuse involvement and enlargement of the left cavernous sinus with carotid artery encasement by a mass-like lesion was also noted (Figs. 1A and 1C). Only slight enhancement of the cavernous sinus mass was present and

the nerves within the cavernous sinus wall were not clearly delineated (Fig. 1C). Moderately intense contrast enhancement was seen involving the perineural region of the thickened left trigeminal nerve (Fig. 1D).

The patient underwent a craniotomy. It was not possible to dissect the tumor that had been seen along the involved neural structures. Some extension was also seen within the cavernous sinus. A biopsy was performed. Approximately 1 hour following operation, the patient had a generalized seizure. A CT scan demonstrated a right occipital intraparenchymal hemorrhage, diffuse subarachnoid blood, and hypodensity within the basal ganglia. One hour later, the patient suffered respiratory arrest requiring intubation and complicated by hemodynamic instability. The patient subsequently died.

## Pathologic Findings

Grossly, the third nerve was slightly yellowed and thickened at the distal end just before entering the dural sheath. A grayish soft mass was seen bulging out of the cavernous sinus. The mass filled the entire cavernous sinus and was soft and stringy in consistency. Similar findings were seen involving the fifth nerve.

Detailed cytologic and pathologic features of this entity are to be discussed in a separate paper. Essentially, microscopic evaluation revealed a benign lesion with no abnormal mitotic activity or cellular atypia. In addition, there was no evidence of inflammation. Permanent sections showed vascular fibroconnective tissue surrounding a nerve sheath lesion characterized by a concentric proliferation of Schwann cell processes around intact axons, forming onion bulb structures on cross-section.

Myelin sheaths were intact albeit attenuated. Electron microscopy demonstrated spindle-shaped cells with interdigitating processes surrounded by basement laminae and collagenous

---

Received July 3, 1991; accepted and revision requested October 22; revision received January 21, 1992 and accepted April 29.

<sup>1</sup> Department of Radiology, Stanford University School of Medicine, Stanford, CA.

<sup>2</sup> Department of Pathology, Stanford University School of Medicine, Stanford, CA.

<sup>3</sup> Department of Neurosurgery, Stanford University School of Medicine, Stanford, CA.

<sup>4</sup> Address reprint requests to Barton Lane, MD, Diagnostic Radiology, Neuroradiology Section, Stanford University School of Medicine, Stanford, CA 94305-5105.

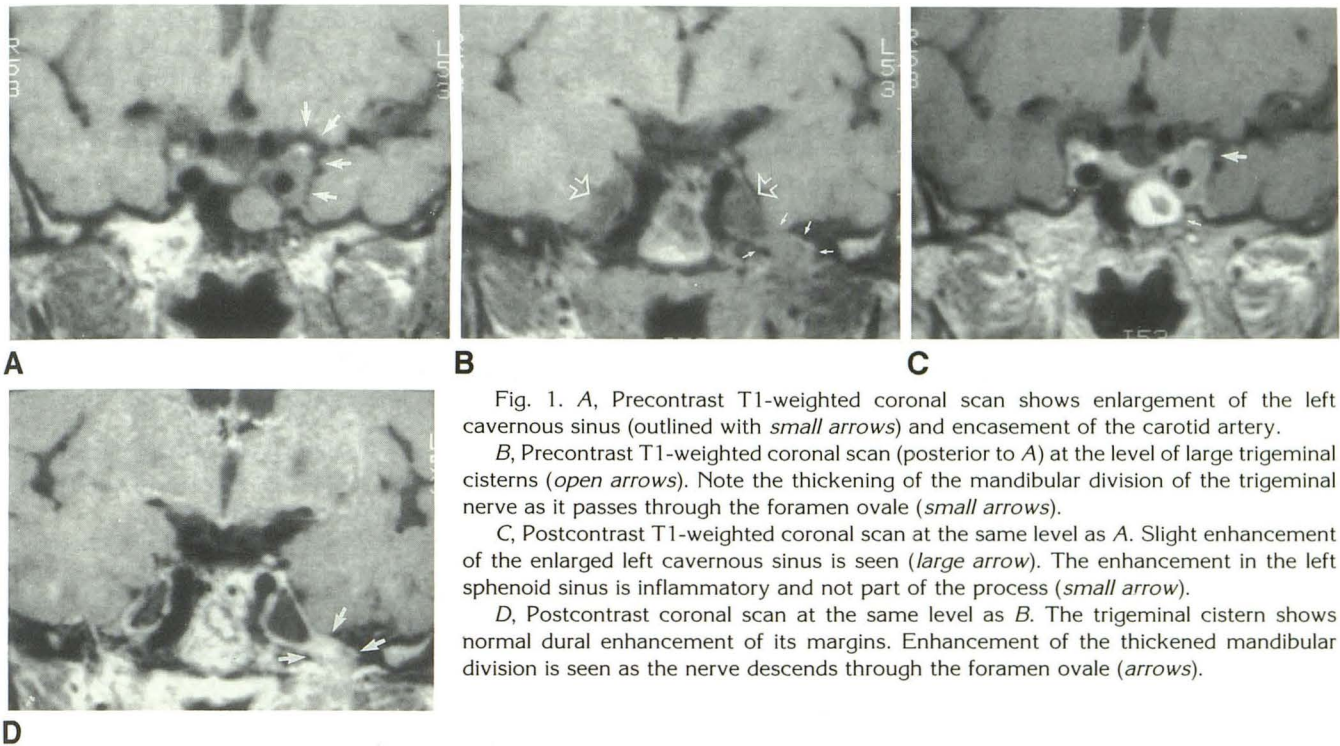


Fig. 1. A, Precontrast T1-weighted coronal scan shows enlargement of the left cavernous sinus (outlined with *small arrows*) and encasement of the carotid artery.

B, Precontrast T1-weighted coronal scan (posterior to A) at the level of large trigeminal cisterns (*open arrows*). Note the thickening of the mandibular division of the trigeminal nerve as it passes through the foramen ovale (*small arrows*).

C, Postcontrast T1-weighted coronal scan at the same level as A. Slight enhancement of the enlarged left cavernous sinus is seen (*large arrow*). The enhancement in the left sphenoid sinus is inflammatory and not part of the process (*small arrow*).

D, Postcontrast coronal scan at the same level as B. The trigeminal cistern shows normal dural enhancement of its margins. Enhancement of the thickened mandibular division is seen as the nerve descends through the foramen ovale (*arrows*).

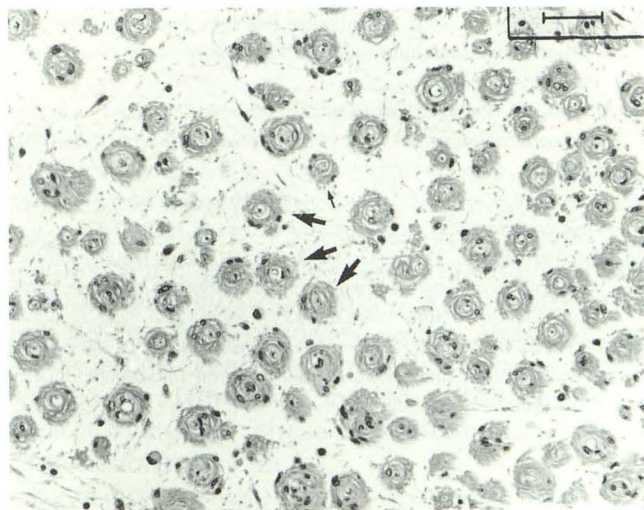


Fig. 2. Cross-sectional view of trigeminal hypertrophic interstitial mononeuropathy demonstrating "onion-bulb" formations composed of proliferating Schwann cells around centrally placed axons. "Onion-bulbs" (*arrows*) are loosely separated in myxoid-appearing background.

stroma. The basal lamina was thickened and there were few intercellular junctions or vesicles. The pathologic diagnosis was hypertrophic interstitial neuropathy (Fig. 2).

## Discussion

Several terms have been used for hypertrophic interstitial neuropathy including localized hyper-

trophic neuropathy, hypertrophic neurofibrosis and hypertrophic mononeuropathy (3, 5, 7, 8). This rare benign entity is characterized by onion bulb formation in the presence of segmental demyelination and remyelination (9). It is more commonly localized but is often composed predominantly of perineural cells (1, 7, 8). This appears to be distinct from the perineurioma described by Lazarus et al as a focal tumor excised from the gastrocnemius muscle and composed of spindle-shaped cells (10). The important feature in contrast to HIN was the fact that no nerve was attached or associated with the tumor. A similar mass was seen in peripheral nerves involving the shoulder (9). HIN is not considered a neoplasm.

These lesions may result from local trauma or nerve entrapment. The finding of Schwann cells forming onion bulbs, surrounding regions of segmental demyelination and remyelination, is consistent with a prior traumatic etiology (11).

HIN has been considered to be a morphologic variant of generalized hypertrophic neuropathy seen in hereditary sensory motor neuropathies such as Charcot-Marie-Tooth disease and Dejerine-Sottas disease or in Refsum disease (11-15). Multiple peripheral nerves as well as cranial nerves can be involved with Refsum disease. In Charcot-Marie-Tooth disease and Dejerine-Sottas disease, the more common feature of hypertrophic neuropathy is hypertrophied nerves con-

taining the onion bulbs. Nerve conduction velocities are usually slower than normal. With peripheral involvement, the upper extremities or lower extremity muscle groups may demonstrate atrophic changes. Both of these disorders are more commonly seen in childhood. Dejerine-Sottas disease may be seen in infancy. These syndromes are caused by aberrant reaction of Schwann cells or perineurial cells due to genetic disorders, while in HIN such a genetic basis does not exist. The neoplasms are focal and can be separated from intact axons microscopically. However, this case of HIN was pathologically distinct from the peripherally reported interstitial and perineural proliferation around the intact nerve by the fact that the proliferating cells were schwannian in nature instead of perineural origin, as in other cases of HIN.

MR proved to be very helpful in delineating the extent of disease and the anatomic areas of involvement. However, the MR appearance is nonspecific. Although this is only the second reported intracranial case, the exquisite imaging detail allows consideration of this entity in addition to more common differential diagnostic possibilities with multifocal involvement such as lymphoma, metastatic disease, and inflammatory or granulomatous processes. In a patient with neurofibromatosis, multiple schwannomas or meningiomas might be considered. Separate perineural lesions secondary to neoplasms known for perineural spread such as adenoid cystic or squamous cell carcinoma would be unlikely.

## References

- Mitsumoto H, Wilbourn AJ, Goren H. Perineurioma as the cause of localized hypertrophic neuropathy. *Muscle Nerve* 1980;3:403-412
- Bilbao JM, Khoury NJ, Hudson AR, Briggs SJ. Perineurioma (localized hypertrophic neuropathy). *Arch Pathol Lab Med* 1984;108:557-560
- Synder M, Cancilla PA, Batzdorf U. Hypertrophic neuropathy simulating a neoplasm of the brachial plexus. *Arch Pathol Lab Med* 1982;106:534-537
- Lallemant RC, Weller RO. Intraneural neurofibromas involving the posterior interosseous nerve. *J Neurol Neurosurg Psychiatry* 1973;36:991-996
- Peckham NH, O'Boynick PL, Meneses A, Kepes JJ. Hypertrophic mononeuropathy: a report of two cases and review of the literature. *Arch Pathol Lab Med* 1982;106:534-537
- Baskin DS, Townsend JJ, Wilson CB. Isolated hypertrophic interstitial neuropathy of the trigeminal nerve associated with trigeminal neuralgia: case report of an entity not previously described. *J Neurosurg* 1981;55:987-990
- de los Reyes RA, Chason JL, Rogers JS, Ausman JI. Hypertrophic neurofibrosis with onion bulb formation in an isolated element of the brachial plexus. *Neurosurgery* 1981;8:397-399
- Hawkes CH, Jones EL, Thomas Smith W. Hypertrophic mononeuropathy. *J Neurol Neurosurg Psychiatry* 1974;37:76-81
- Weidenheim KM, Campbell WG Jr. Perineural cell tumor: immunocytochemical and ultrastructural characterization. Relationship to other peripheral nerve tumors with a review of the literature. *Virchows Arch* 1986;408:375-383
- Lazarus SS, Trombetta LD. Ultrastructural identification of a benign perineurial cell tumor. *Cancer* 1978;41:1823-1829
- Dyck PJ, Lambert EH. Polyneuropathy associated with hypothyroidism: electrophysiologic, quantitative histologic and teased fiber, and electron microscopic study of nerve biopsies. *Trans Am Neurol Assoc* 1969;94:245-248
- Fardeau M. Pathology of Refsum disease. In: Dyck PJ et al, eds. *Peripheral neuropathy*. Vol 2. Philadelphia: Saunders, 1984:1693-1703
- Smith TW et al. Charot-Marie-Tooth disease associated with hypertrophic neuropathy. *J Neuropathol Exp Neurol* 1980;40:420
- Cammermeyer J, Haymaker W, Refsum S. Heredopathia actastica polyneuriformis: the neuropathological changes in three adults and one child. *Am J Pathol* 1964;30:643
- Dyck PJ, Gomez MR. Segmental demyelination in Dejerine-Sottas disease in light, phase contrast and electron microscopic studies. *Mayo Proc Clin* 1968;43:280